

# Abfraction examples

(In random order based on  
my original filing of cases.)

Brian Palmer, DDS  
Kansas City, Missouri  
November 2004

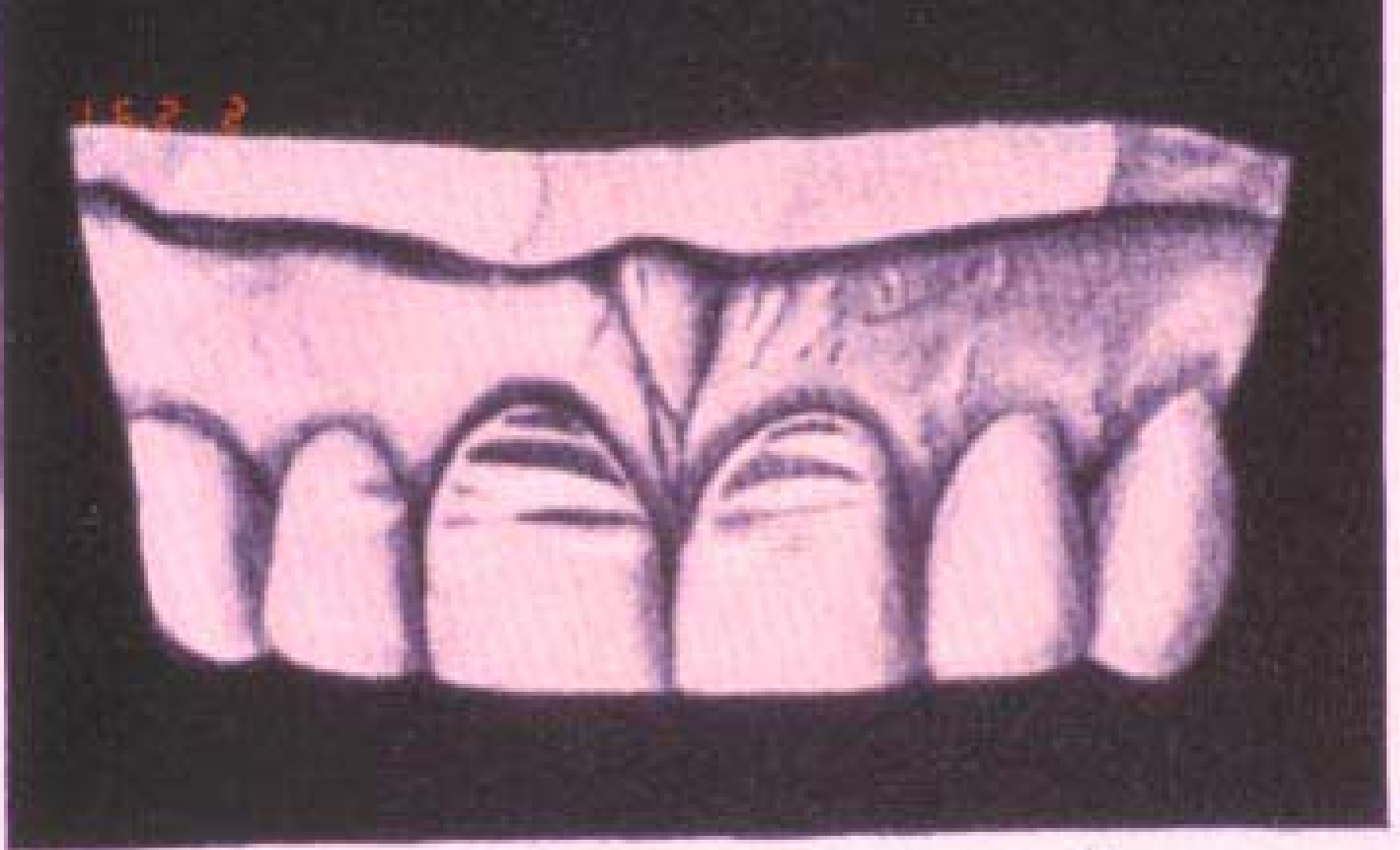
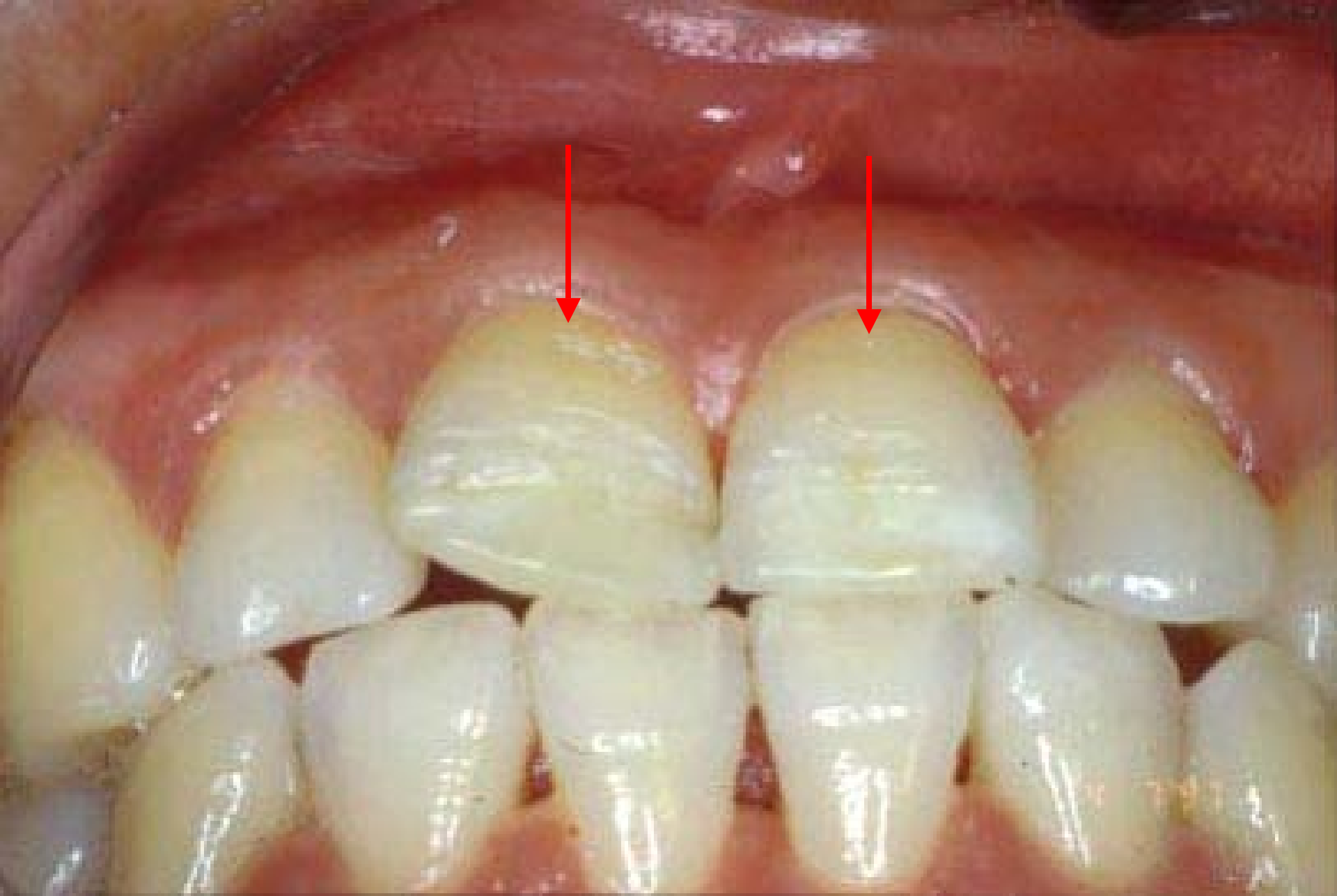

FIG. 56.

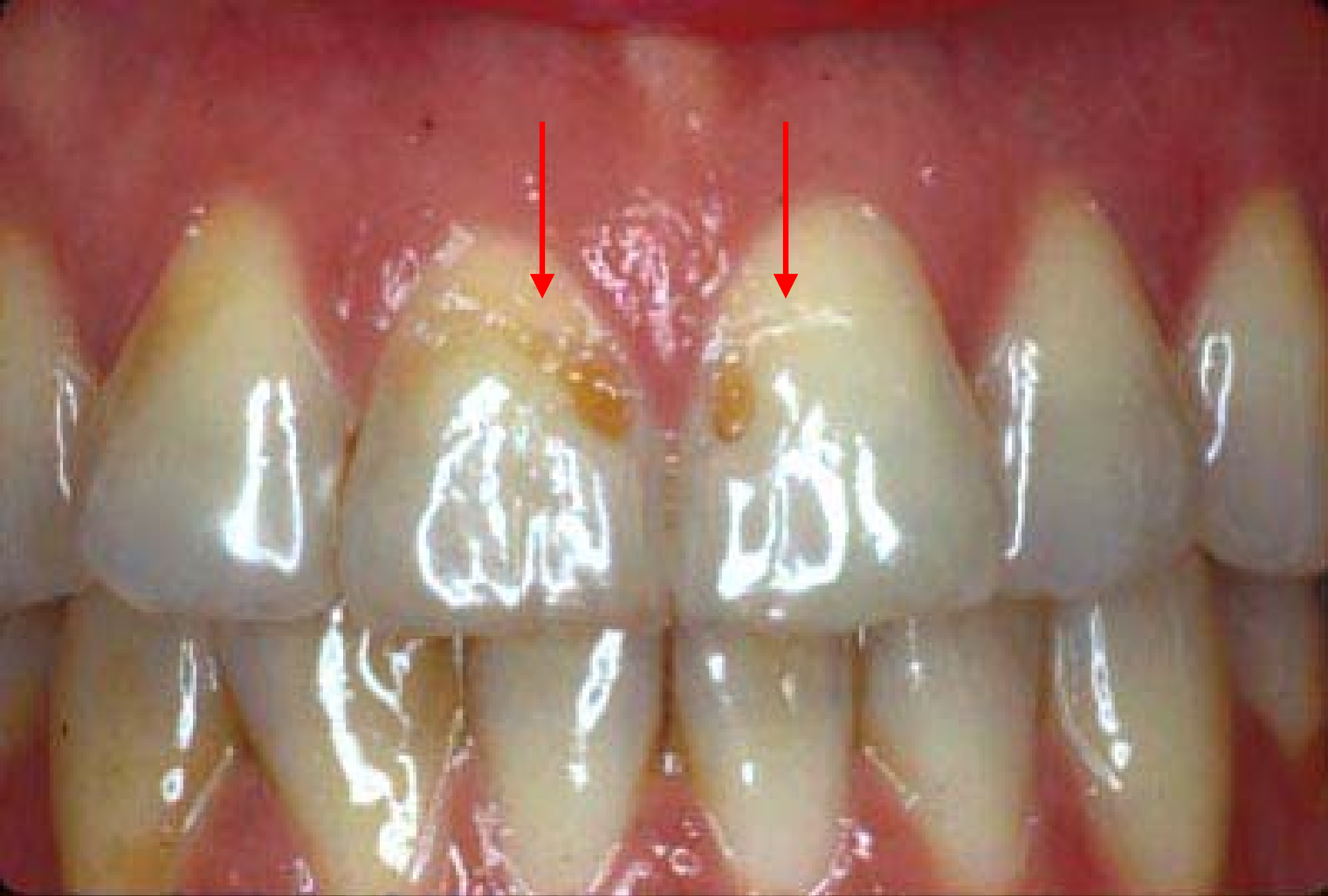B2

GV Black - 1907 Anterior 'wasting'.



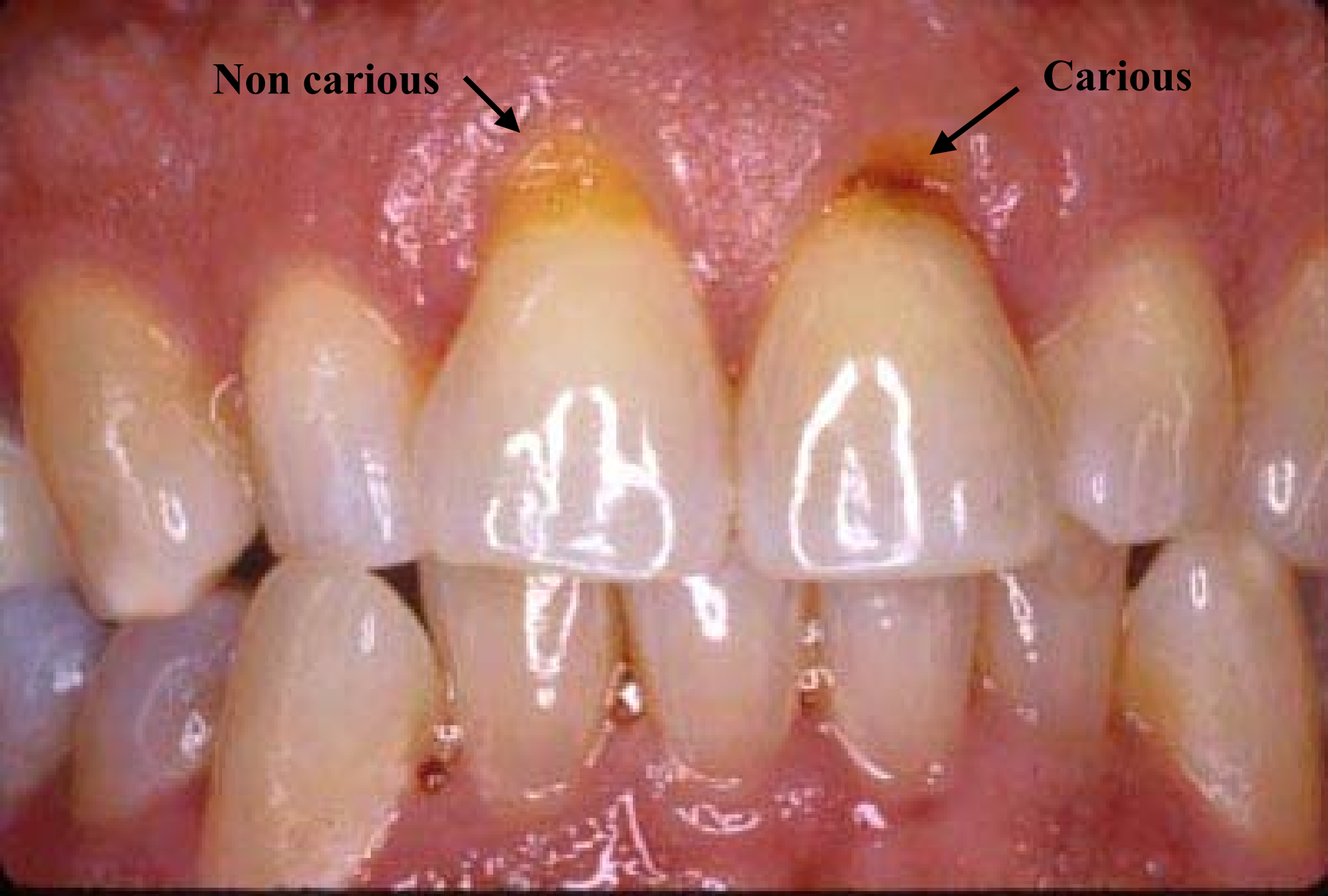
Abfractions on centrals. A 'clencher'.

B3



B4

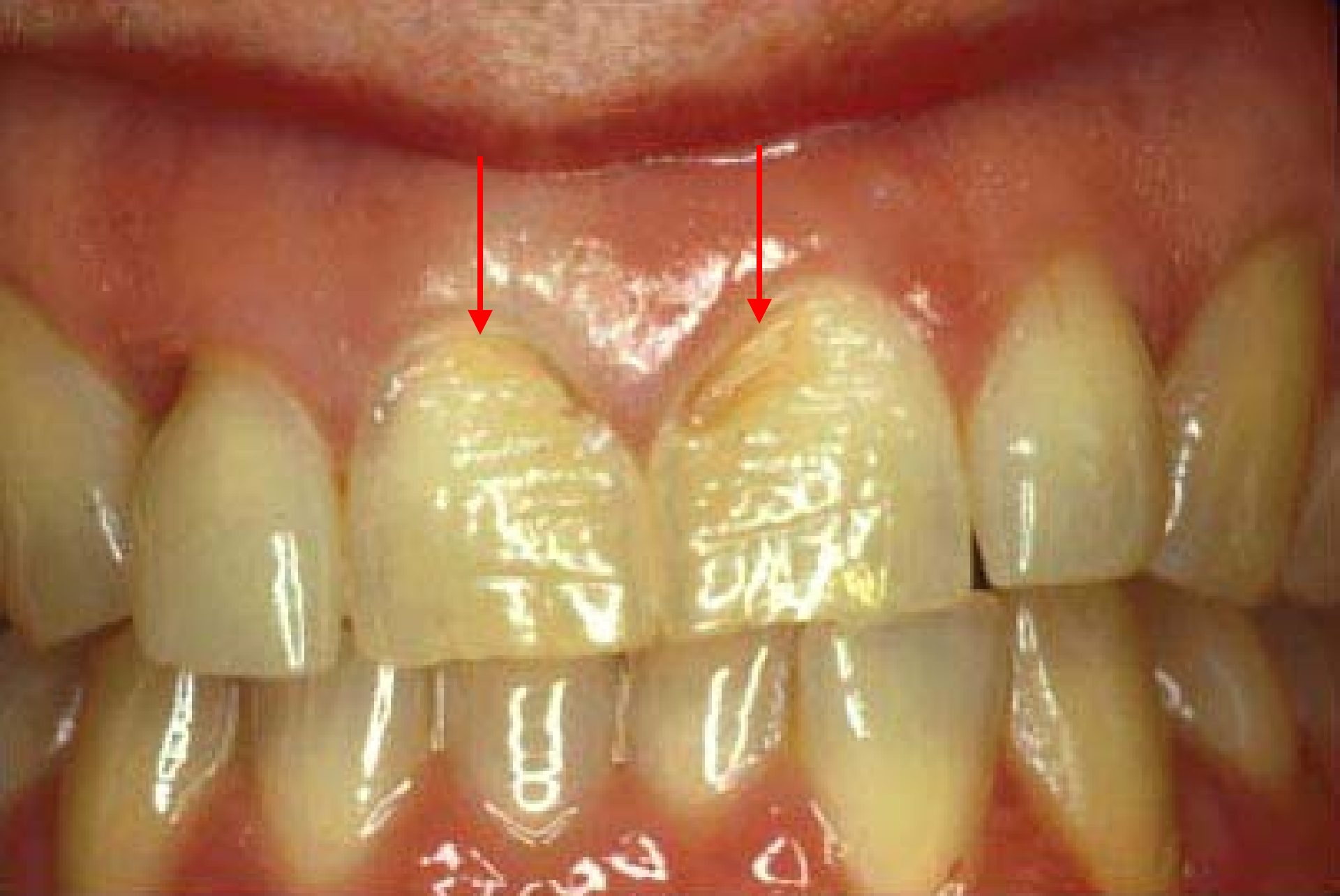Abfractions on centrals.



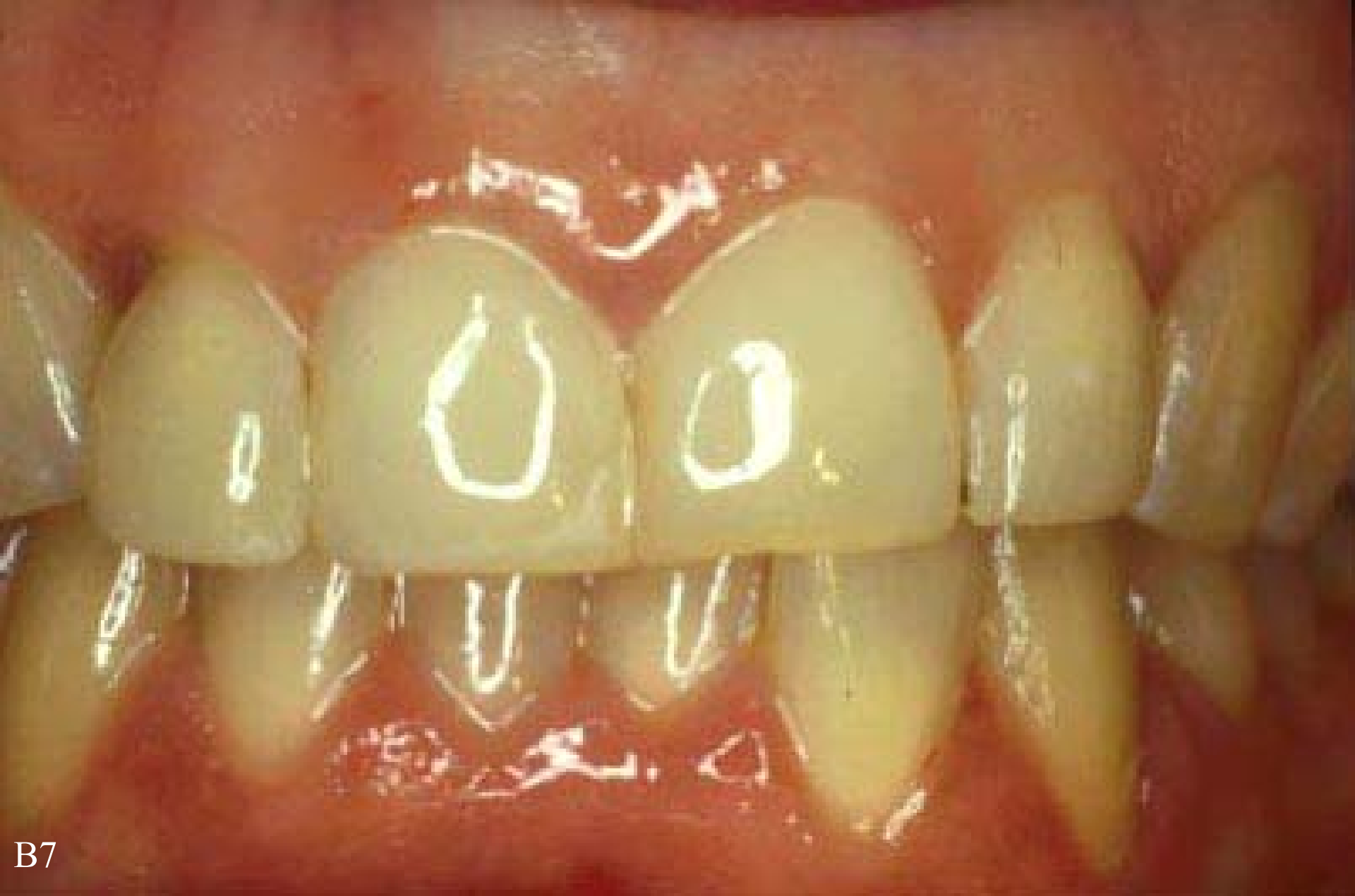**Non carious**

**Cariou**

**Crowded malocclusion with cross-bite.**

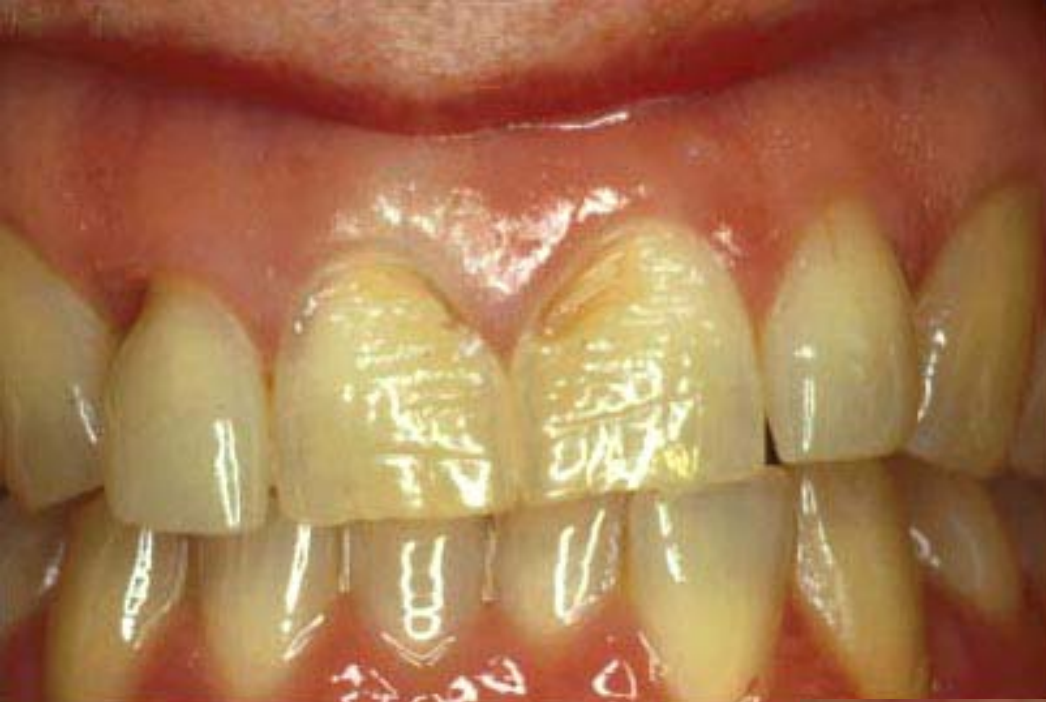

B6 Abfractions on centrals. See next 2 slides.



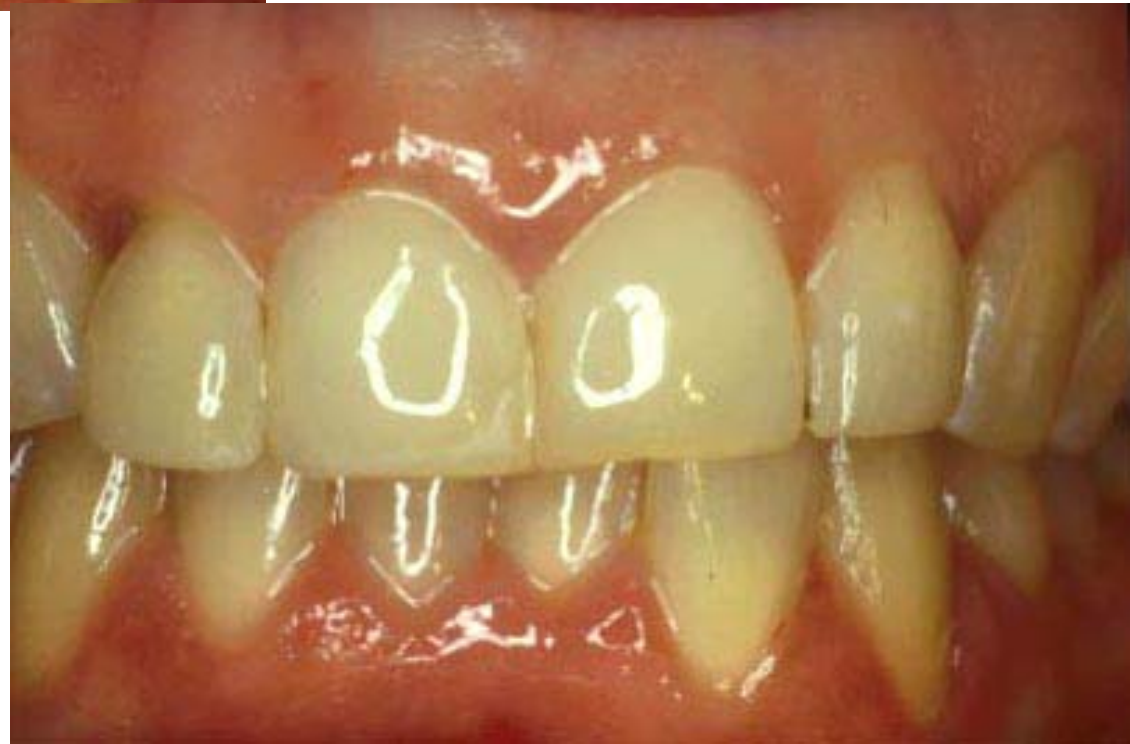B7

Abfractions in previous slide restored. See next slide.



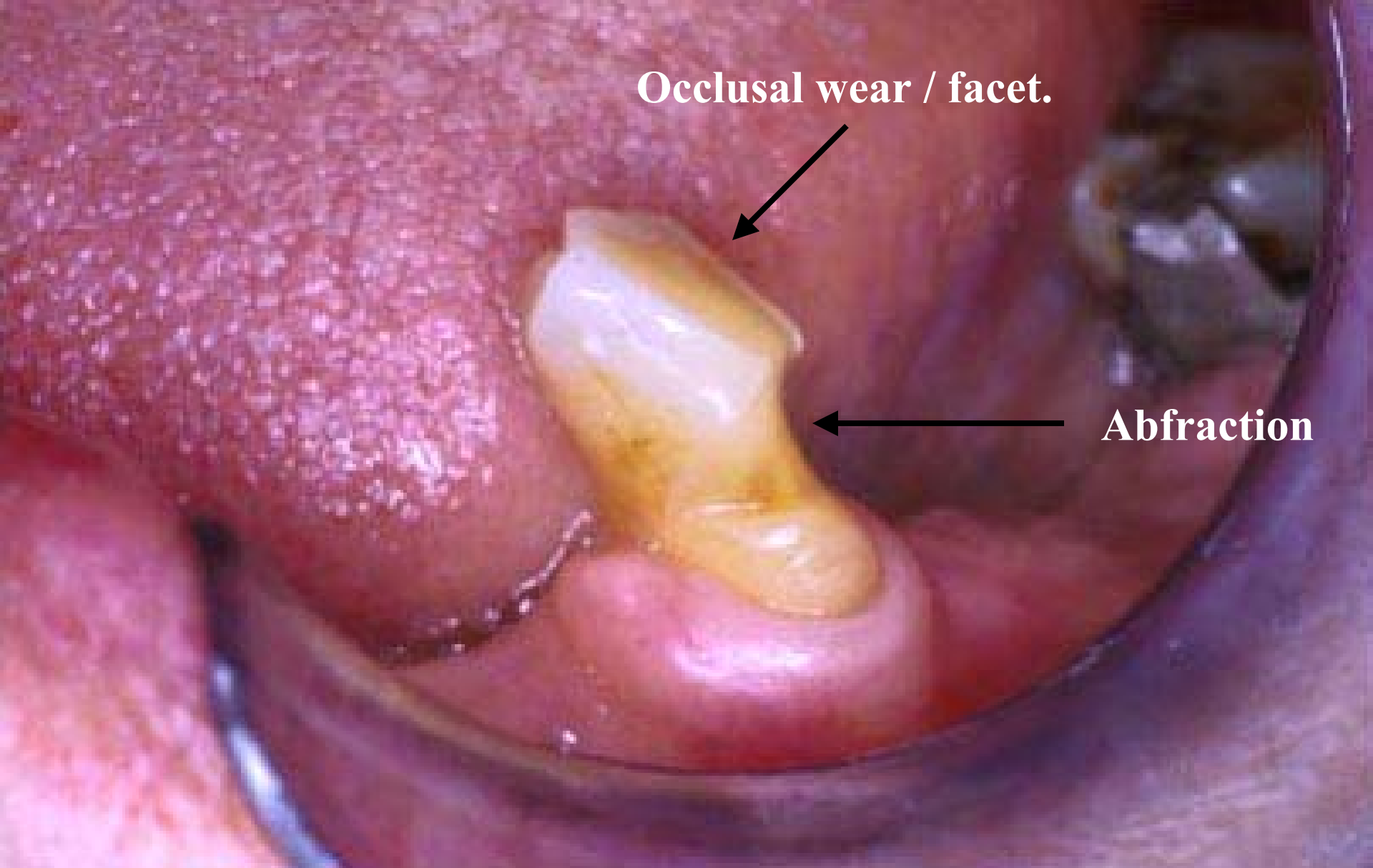
← **Before**

**After** →

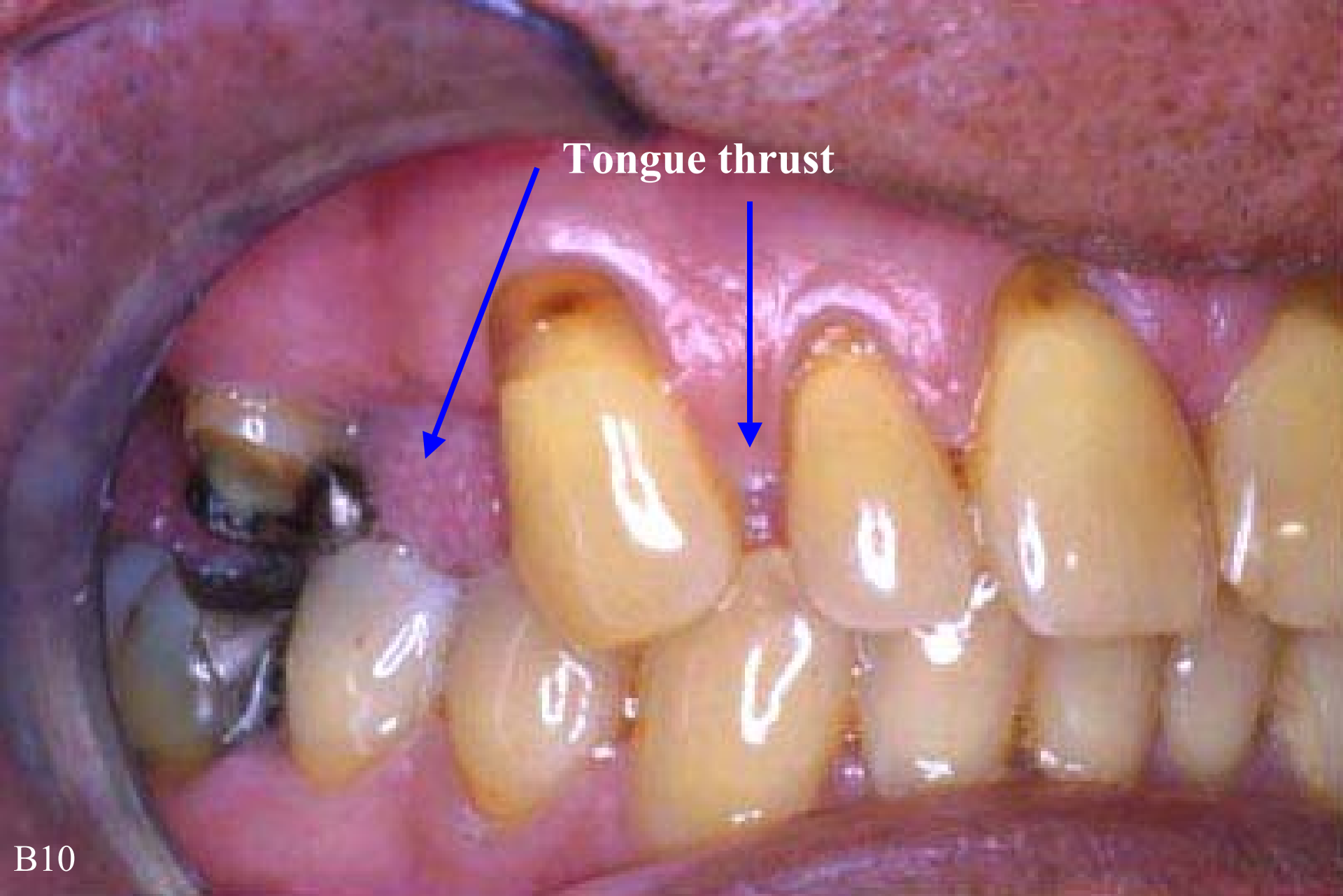


B8

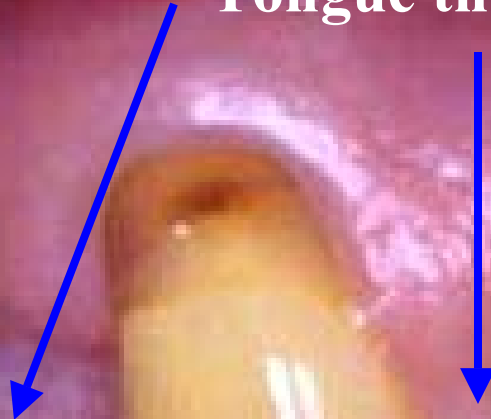**End of case.**



Tooth occludes against porcelain teeth in a full denture. She also has a tongue thrust.

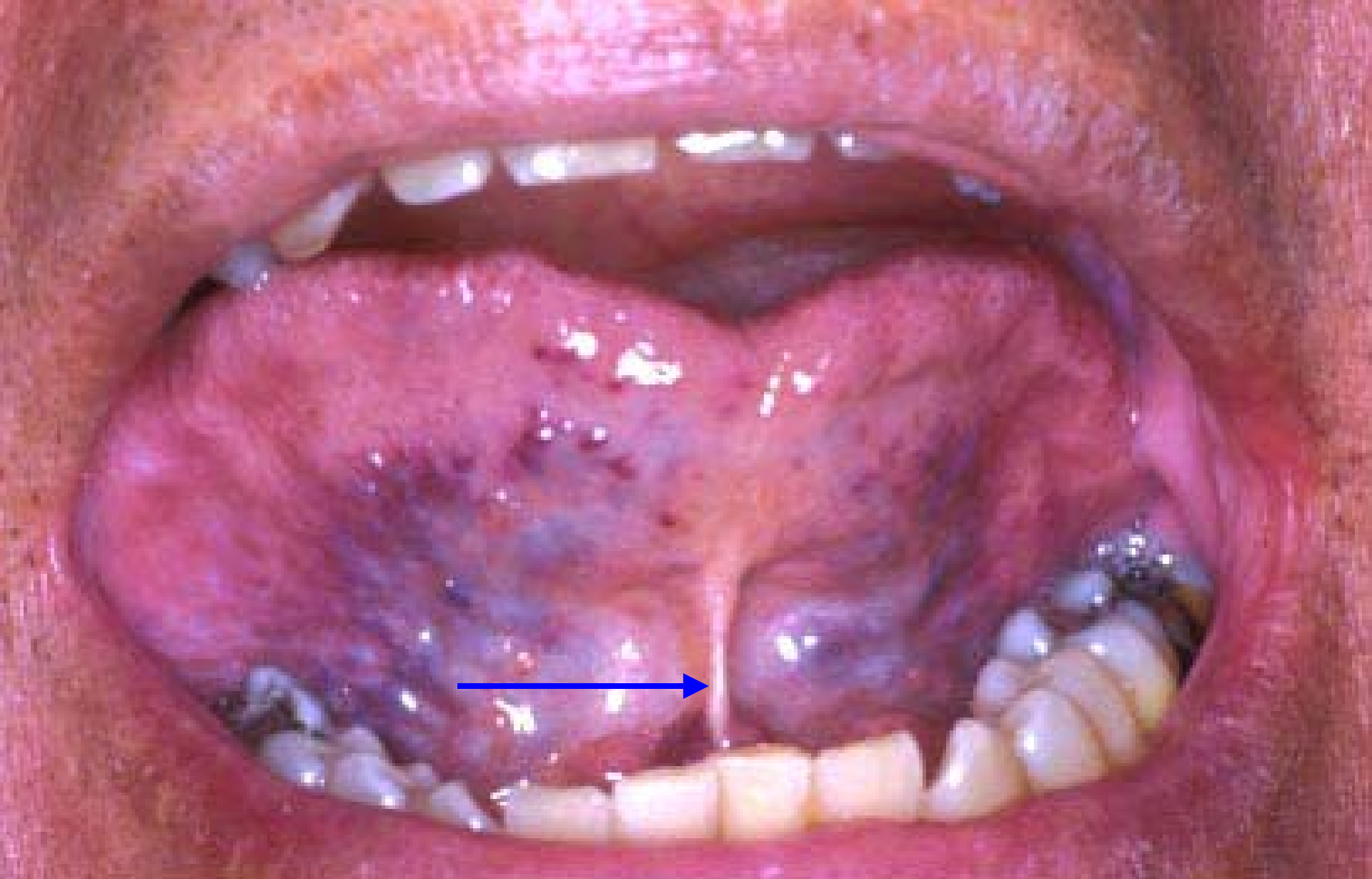


**Tongue thrust**

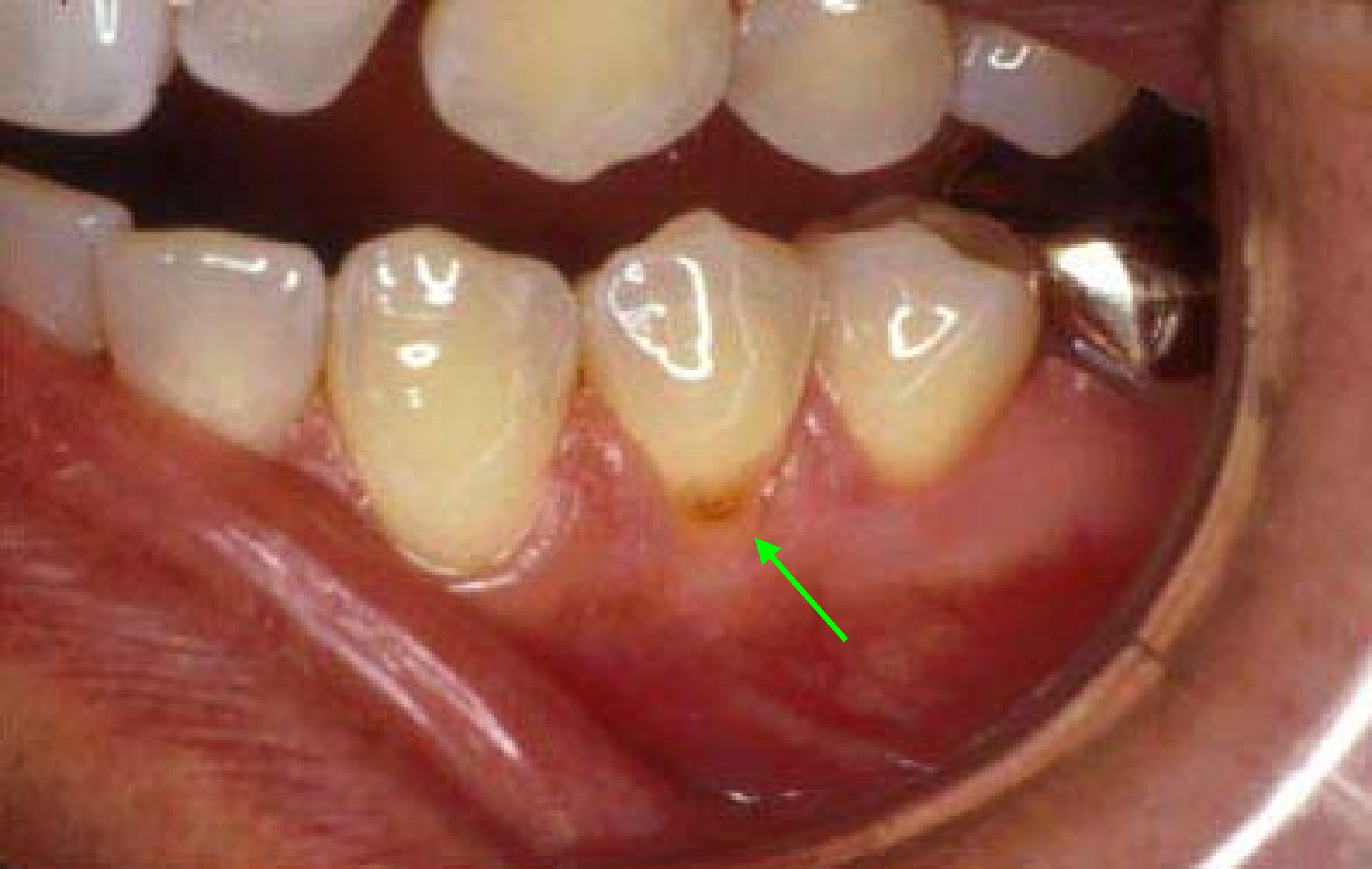

B10

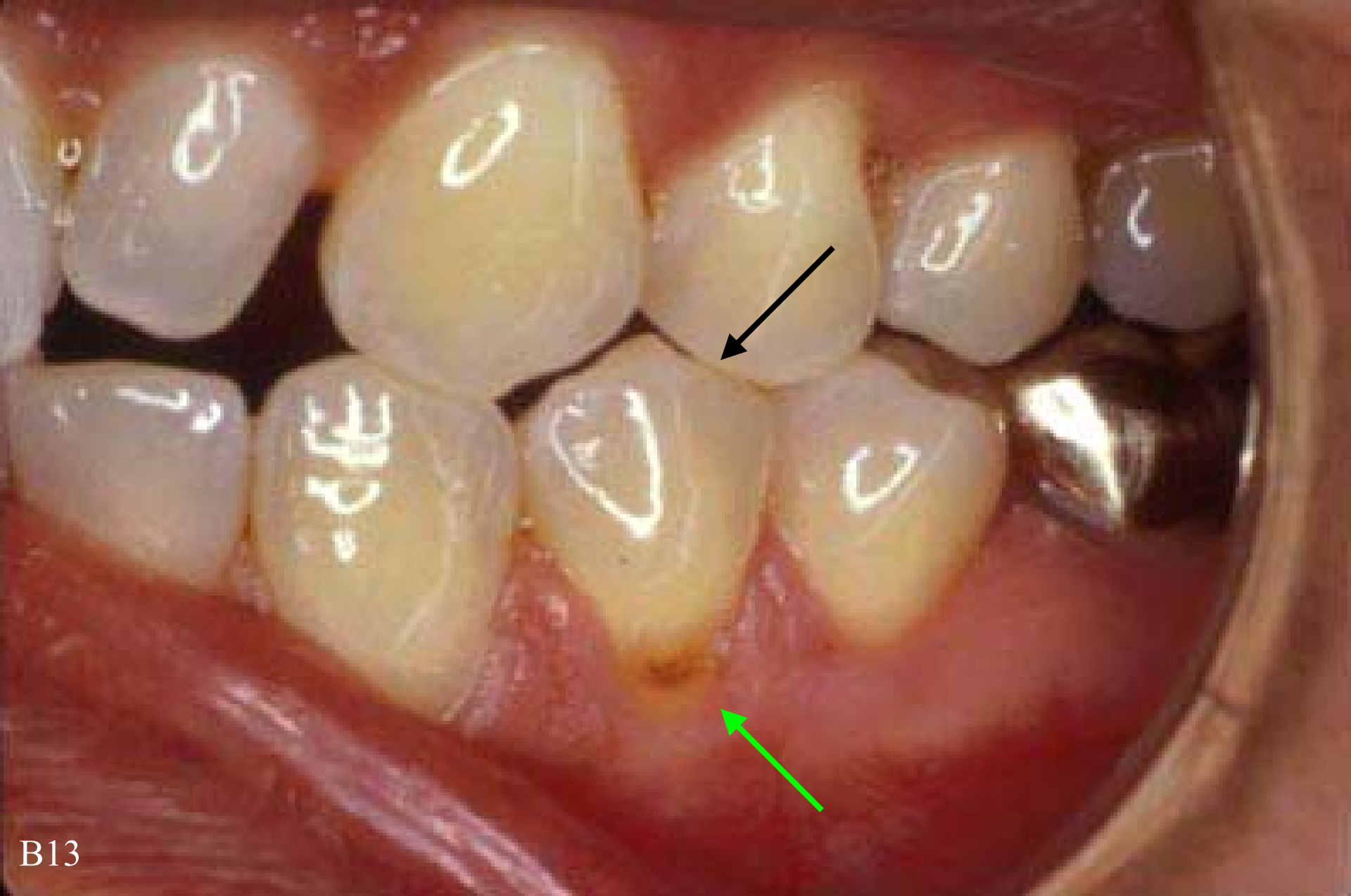
Abfractions and open spaces. Age 66. See next slide.



Patient (Age 66) in previous slide has a tongue thrust due to ankyloglossia.

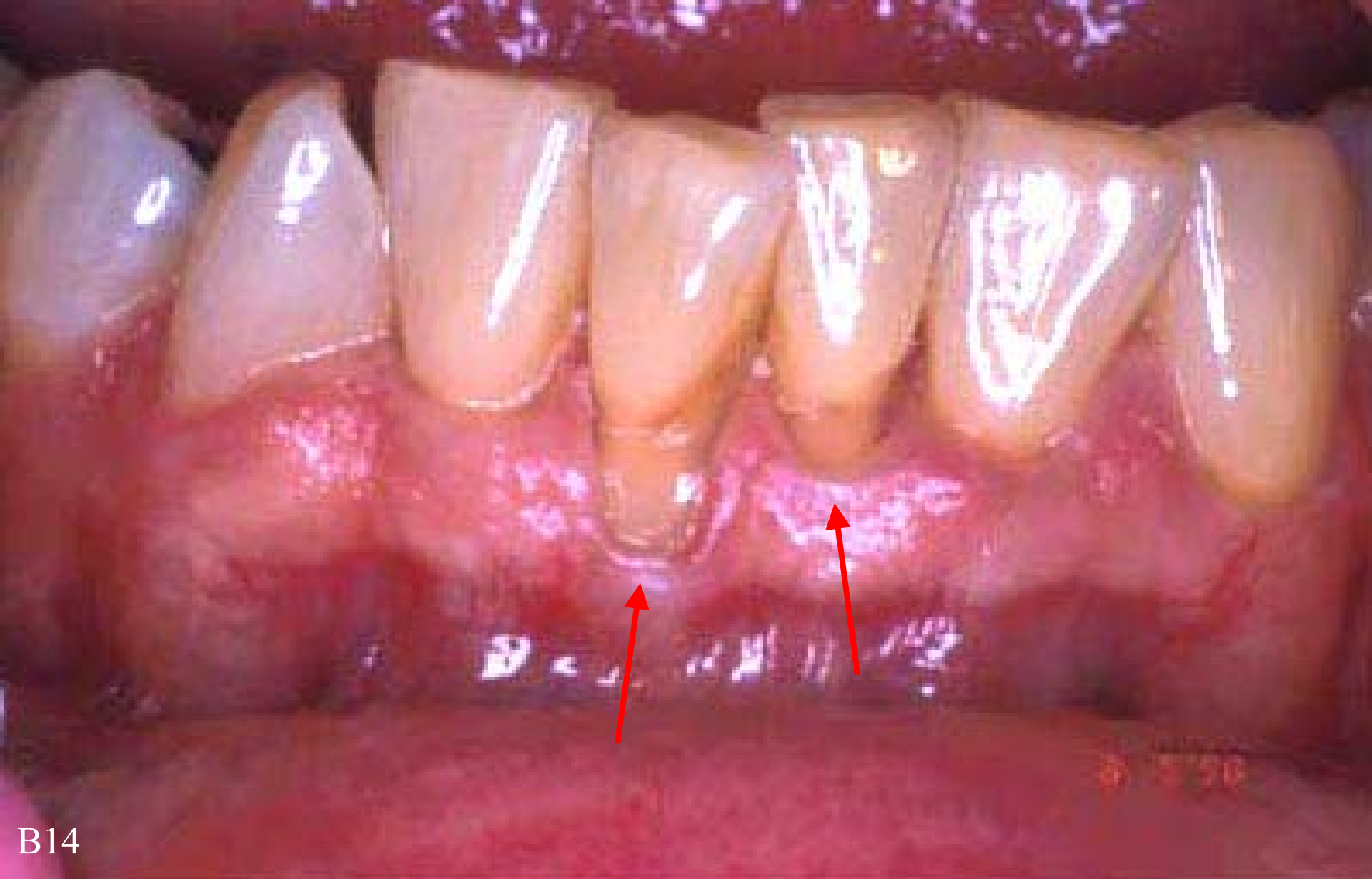

Single abfraction on first bicuspid. See next slide.



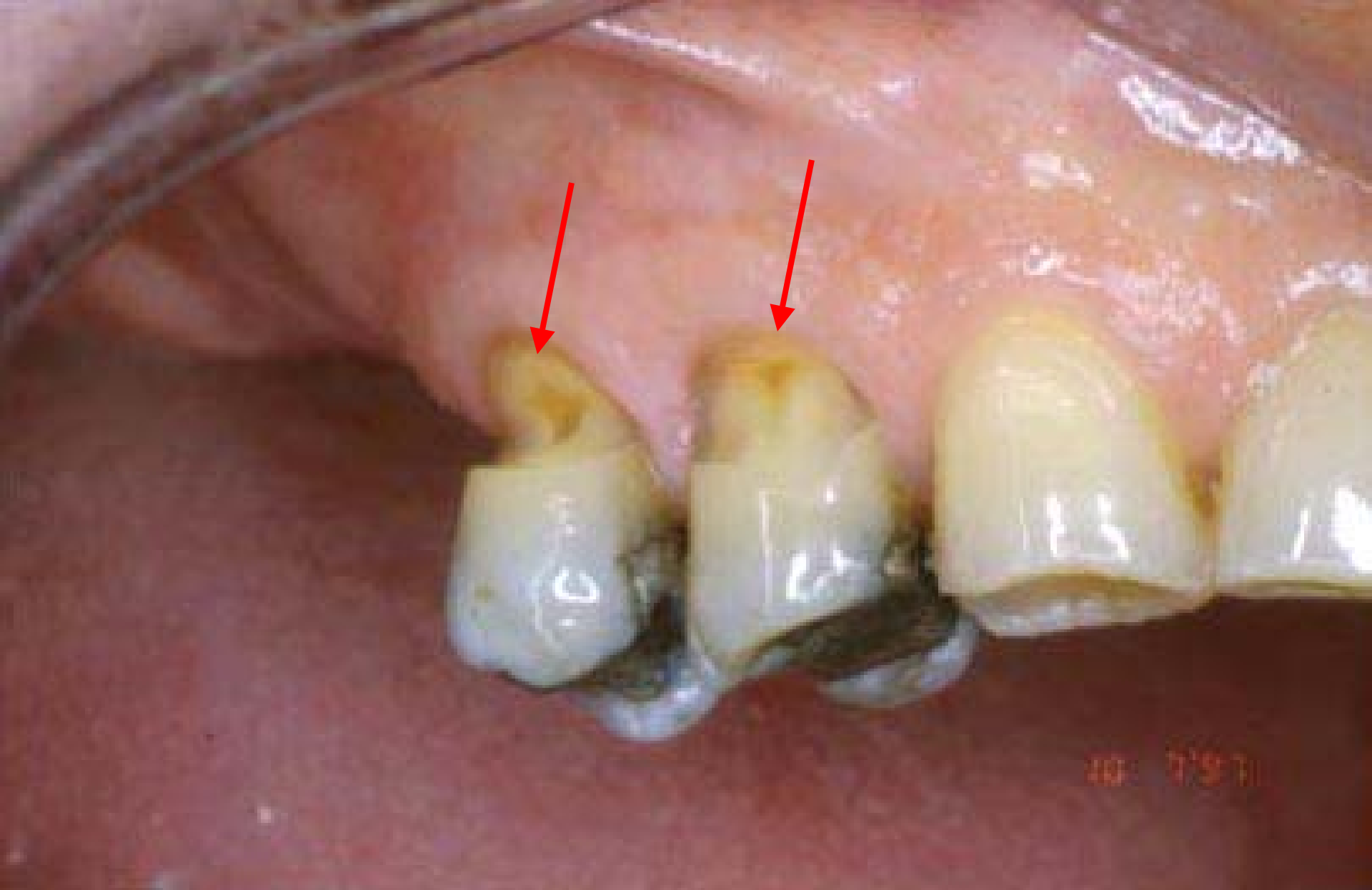
B13

Bicuspid 'rise' contributed to abfraction. End of case.

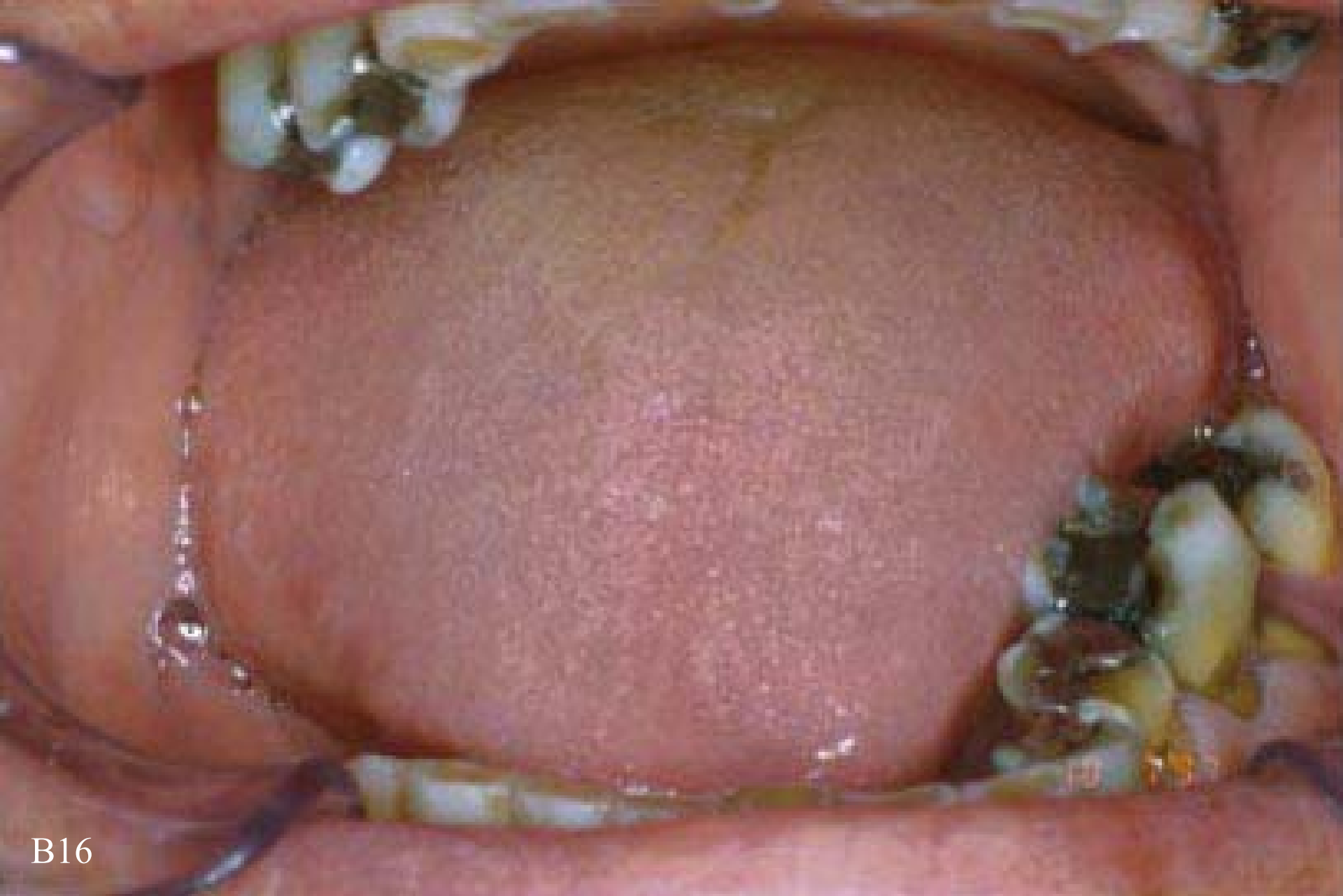


B14

**Mandibular anterior abfractions / recession / clefts.**

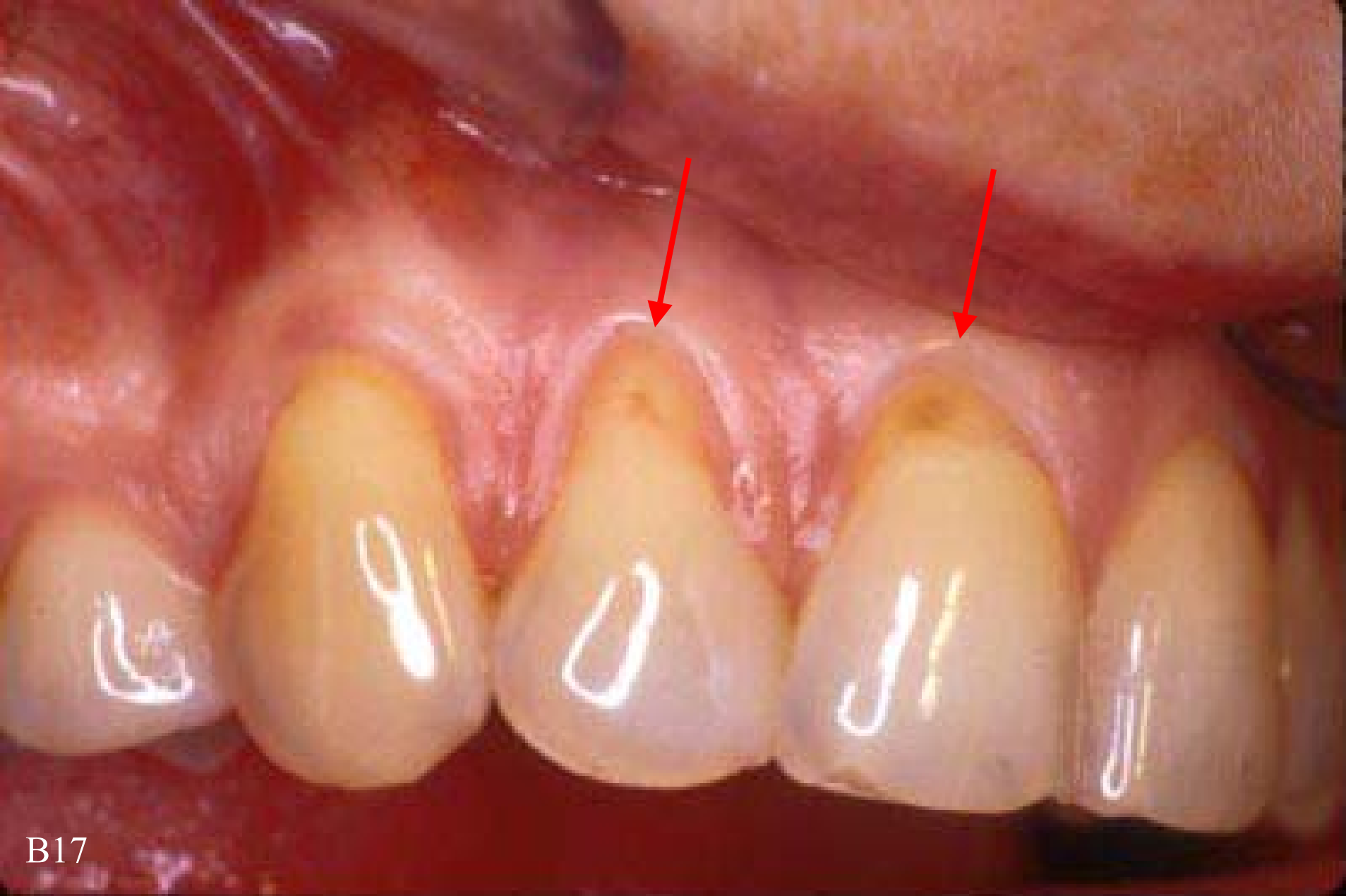

Abfractions caused by traumatic lateral forces from a tongue thrust. See next slide.



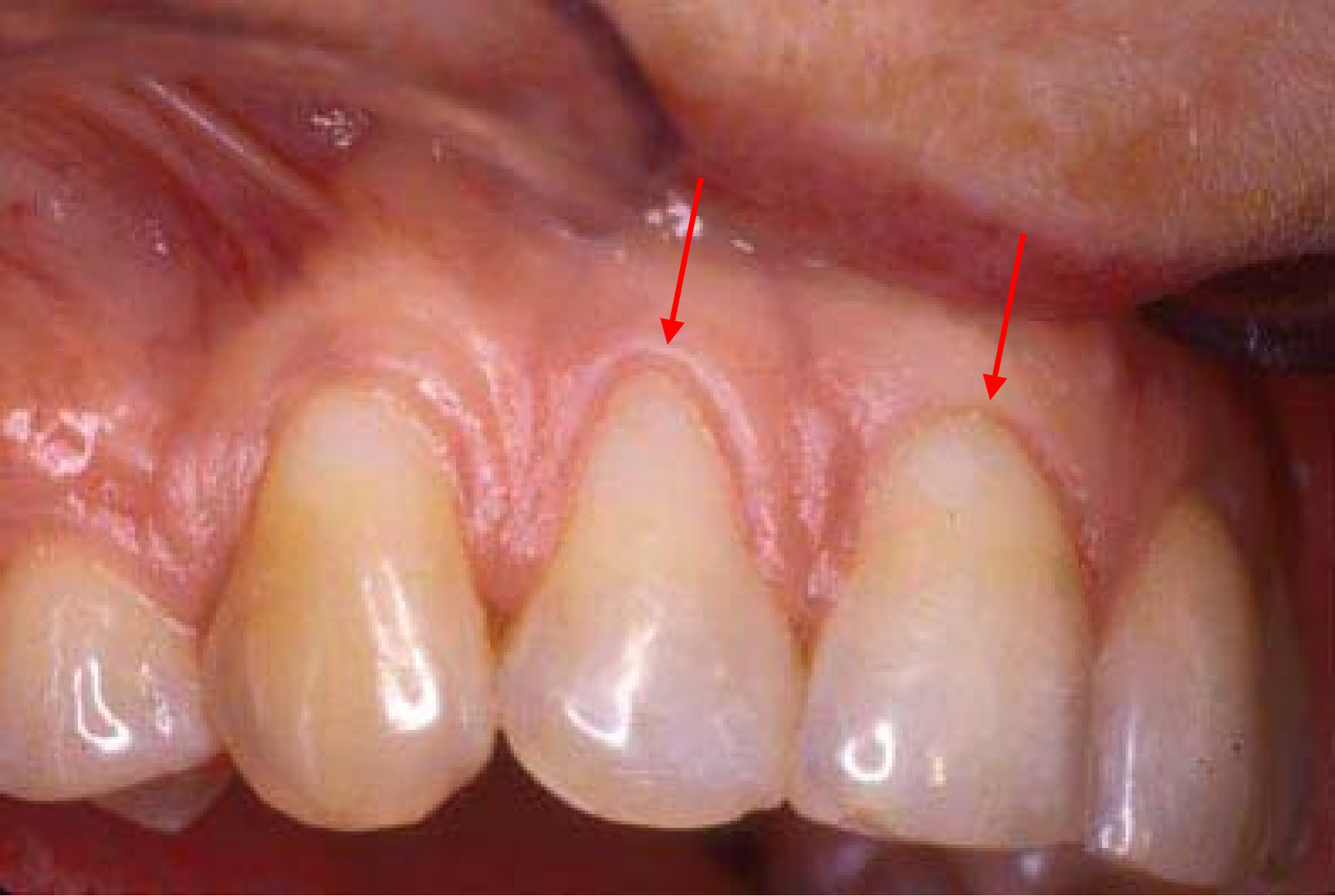B16

Tongue thrust was due to this massive tongue. End of case.



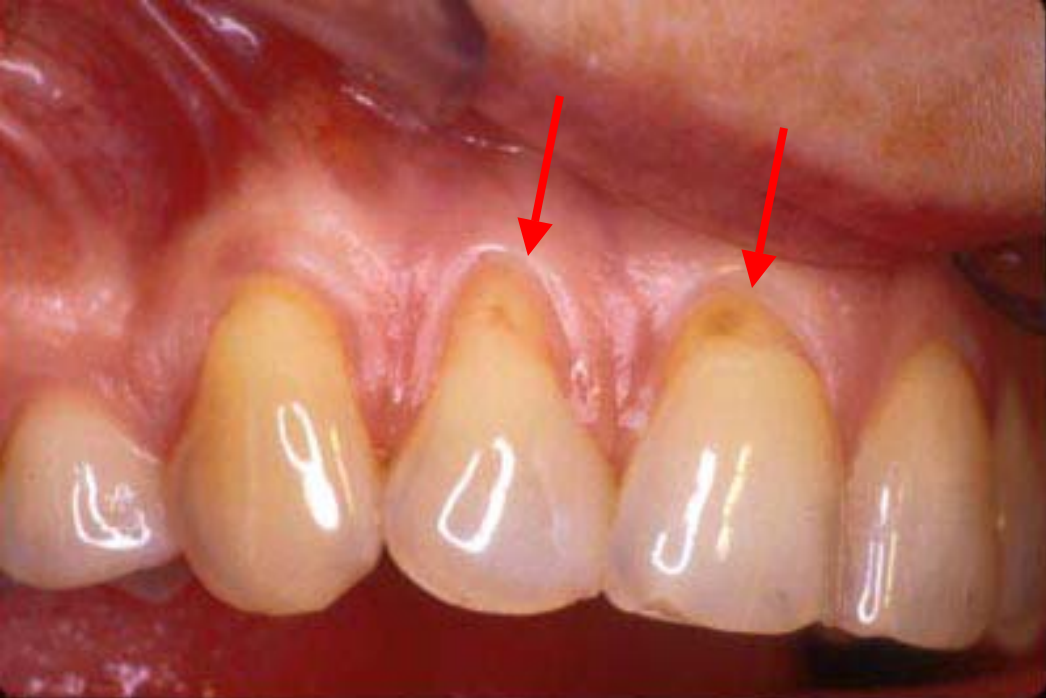B17

Abfractions before restorations. See next 3 slides.

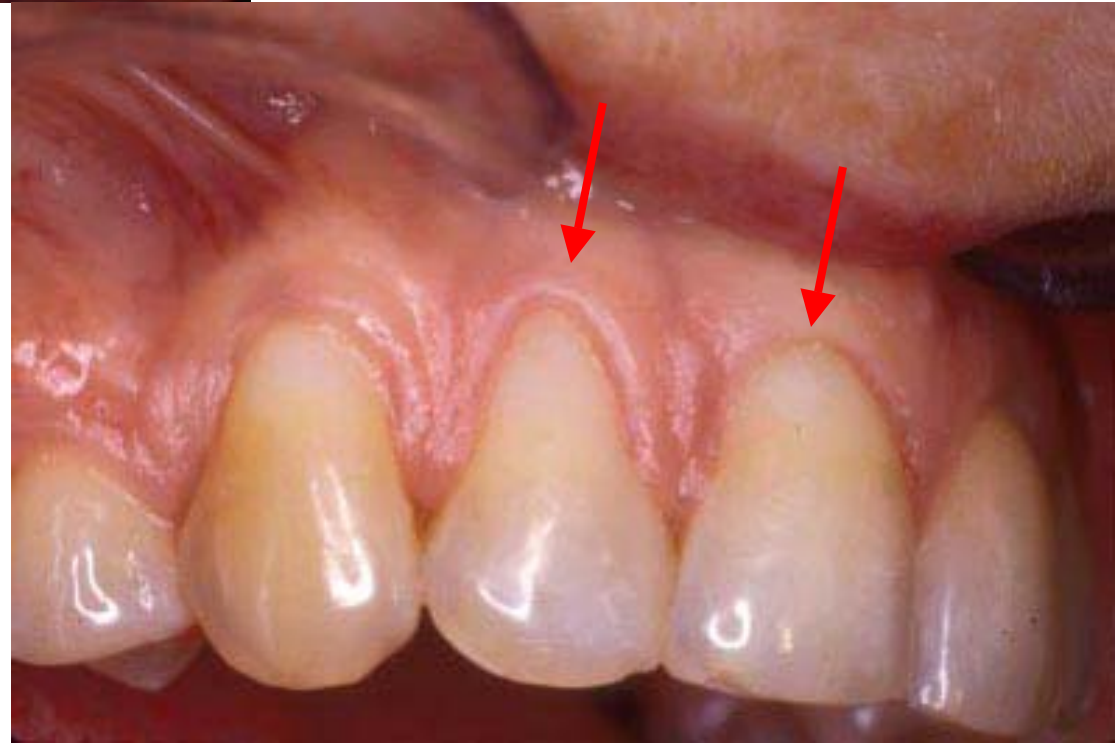

B18

Restorations completed. See next 2 slides.

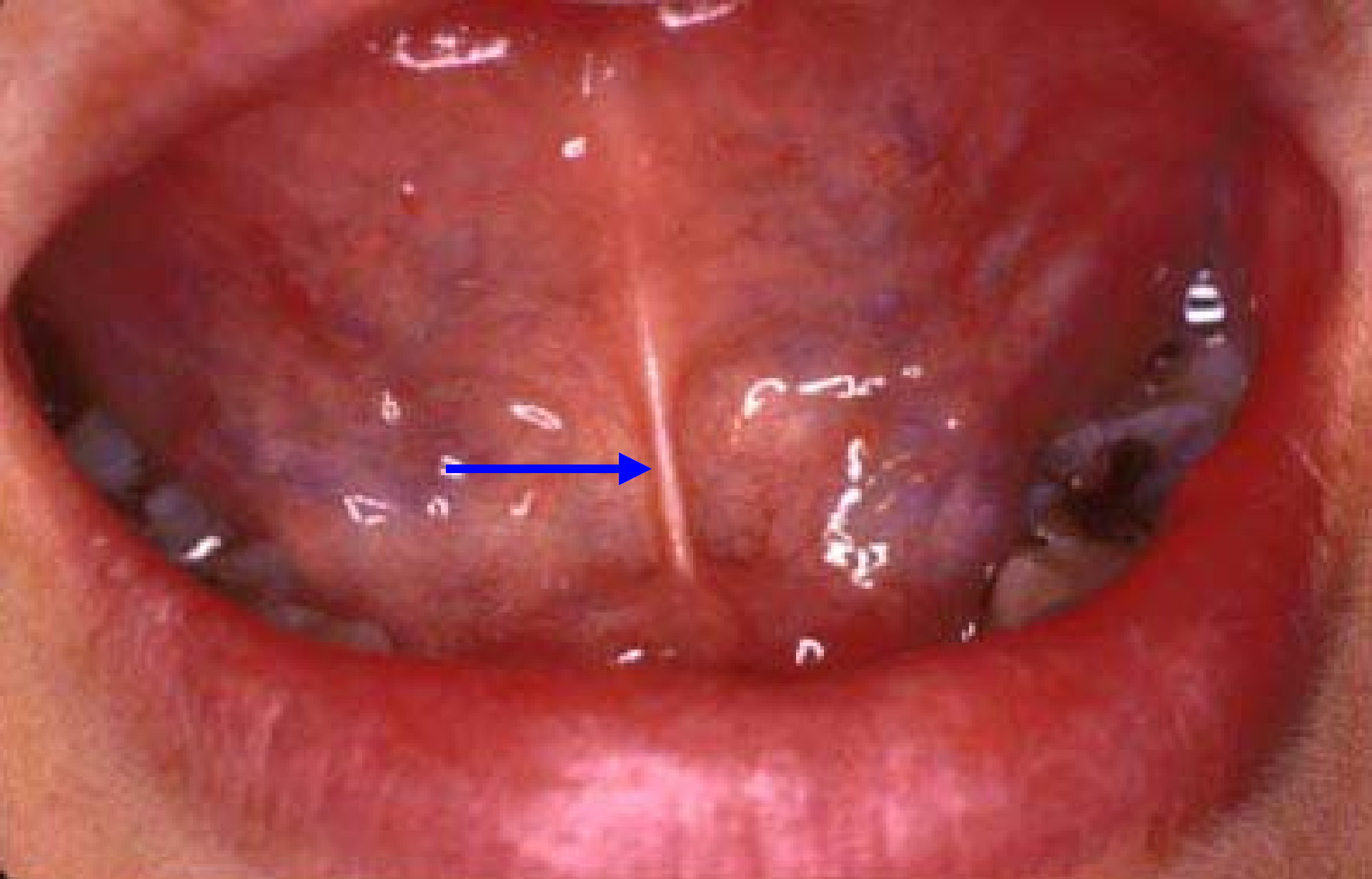

← **Before**

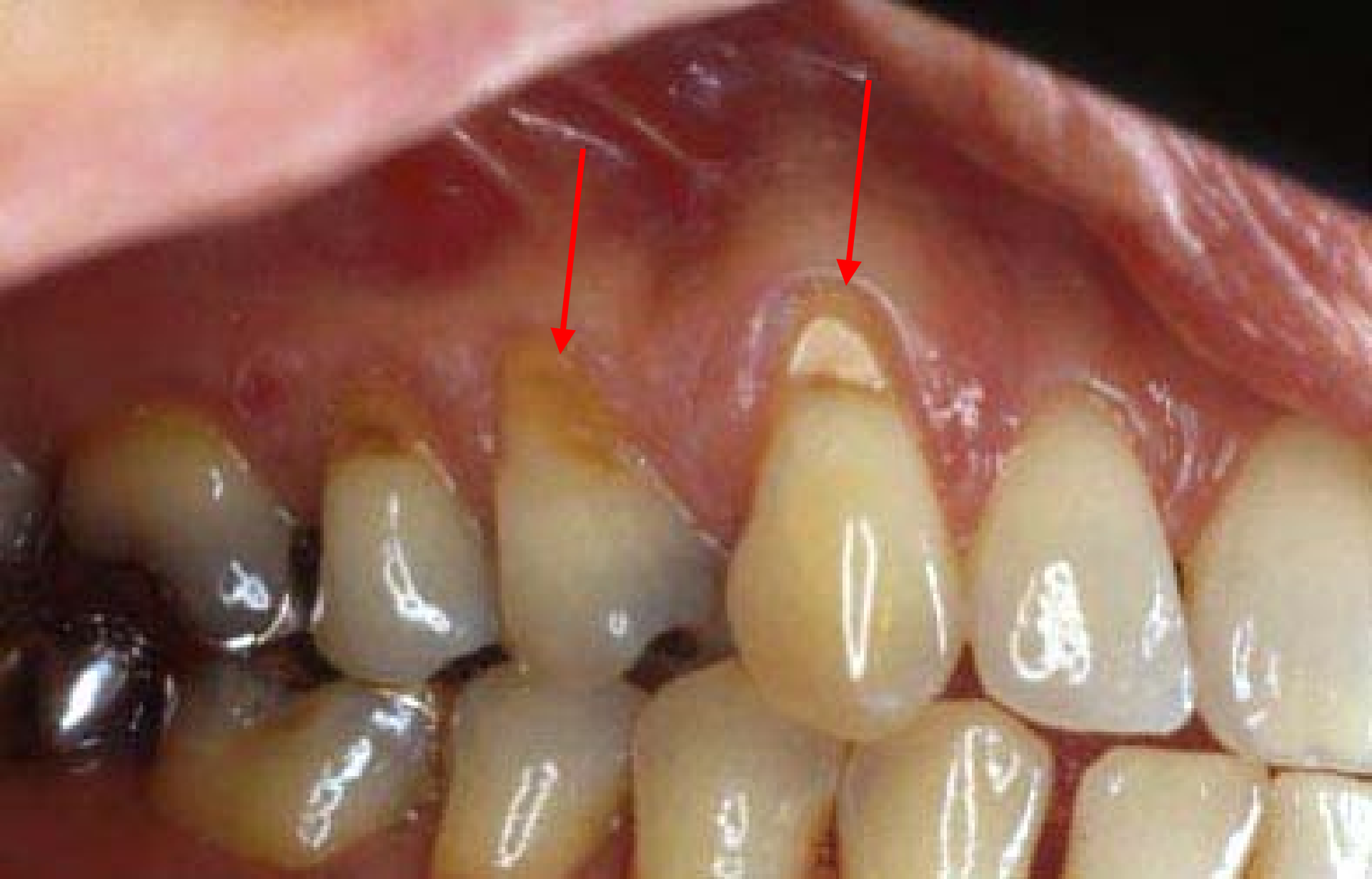


**After** →

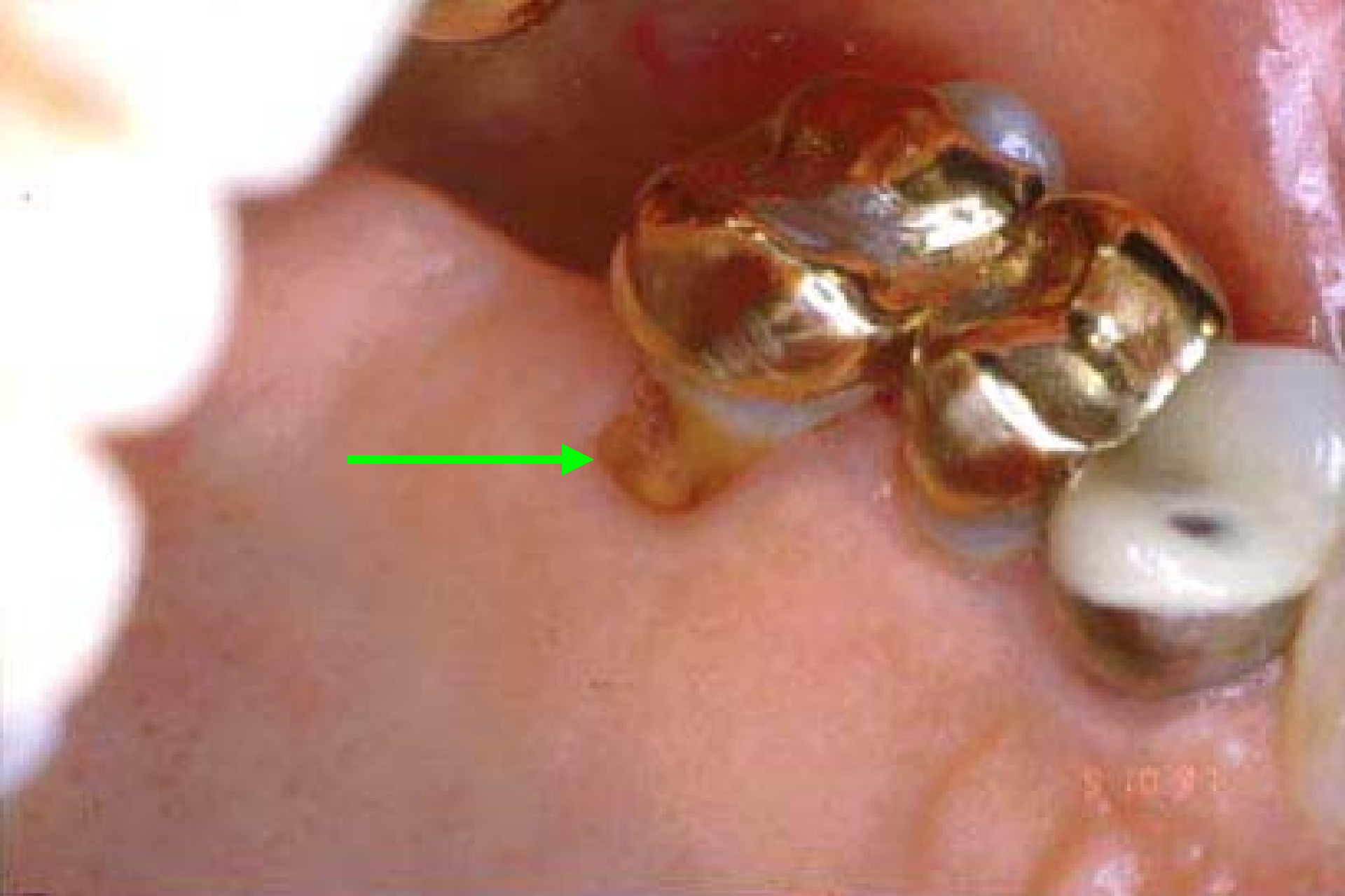
**See next slide.**



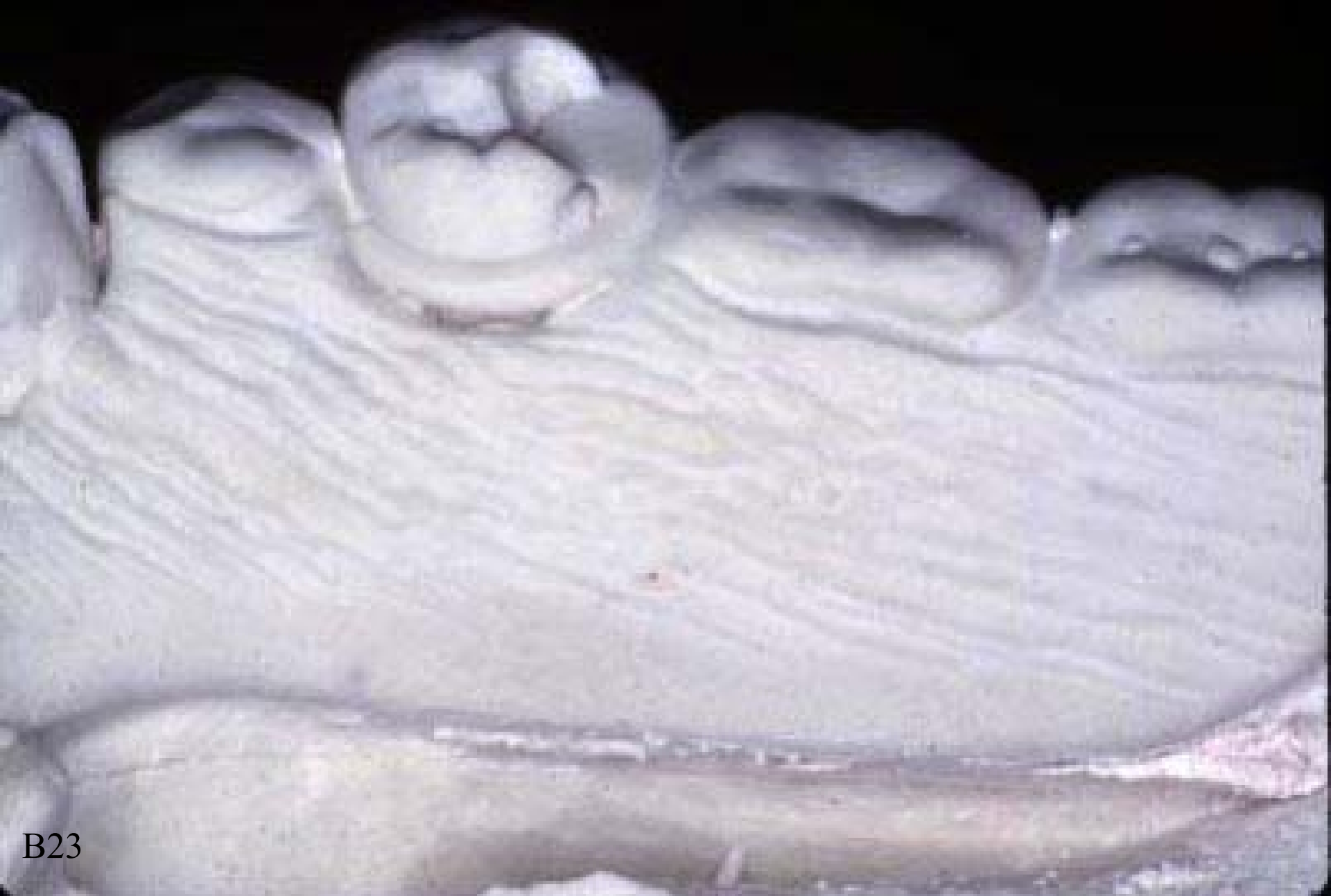Previous patient also had moderate ankyloglossia which caused a tongue thrust. End of case.



Mal-aligned cuspid and bicuspid  
were in traumatic occlusion.

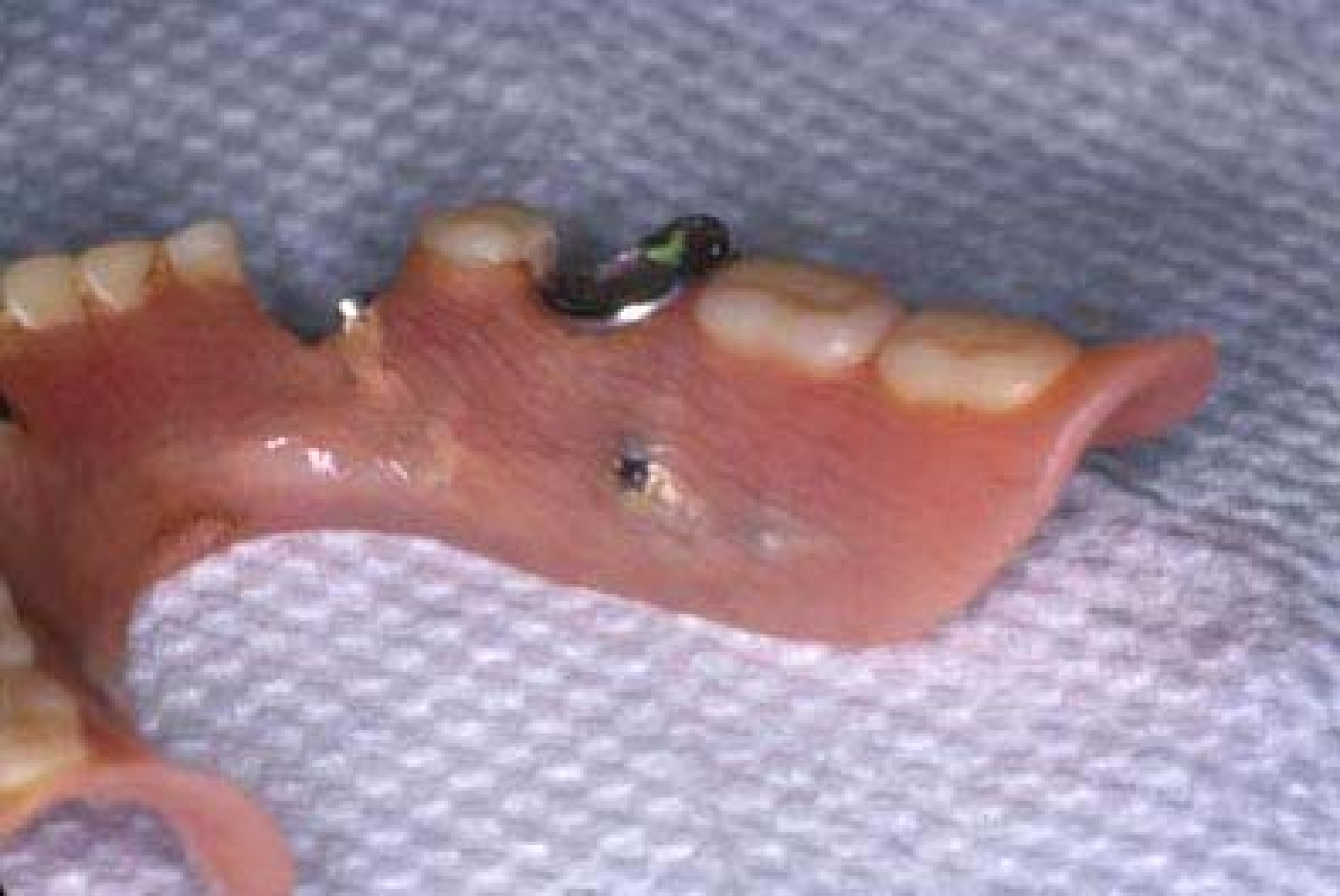

Lingual abfraction on molar.



B23

Stress lines in mandibular partial. See next 3 slides.

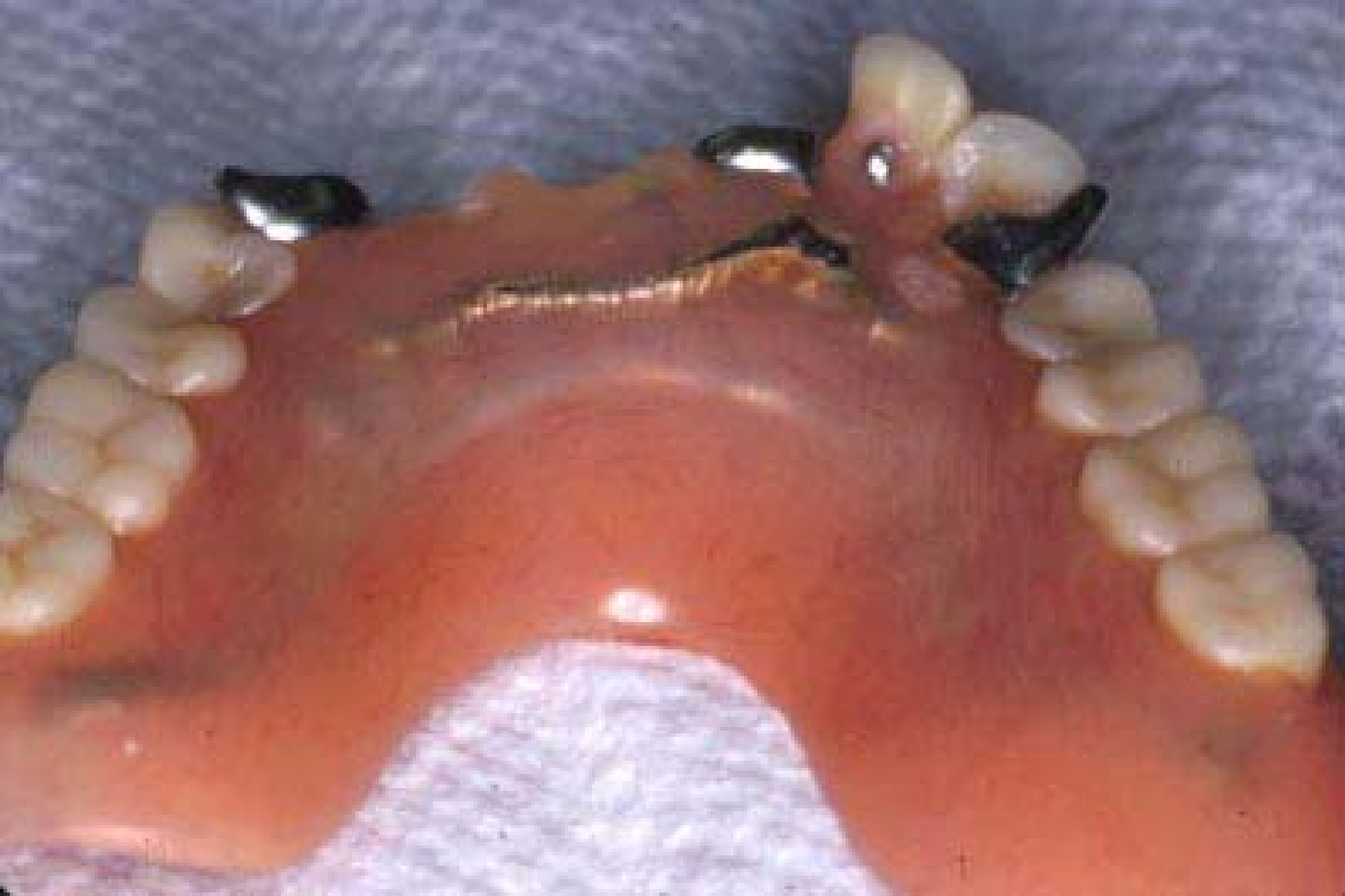

B24 Stress lines in mandibular partial. See next 2 slides.



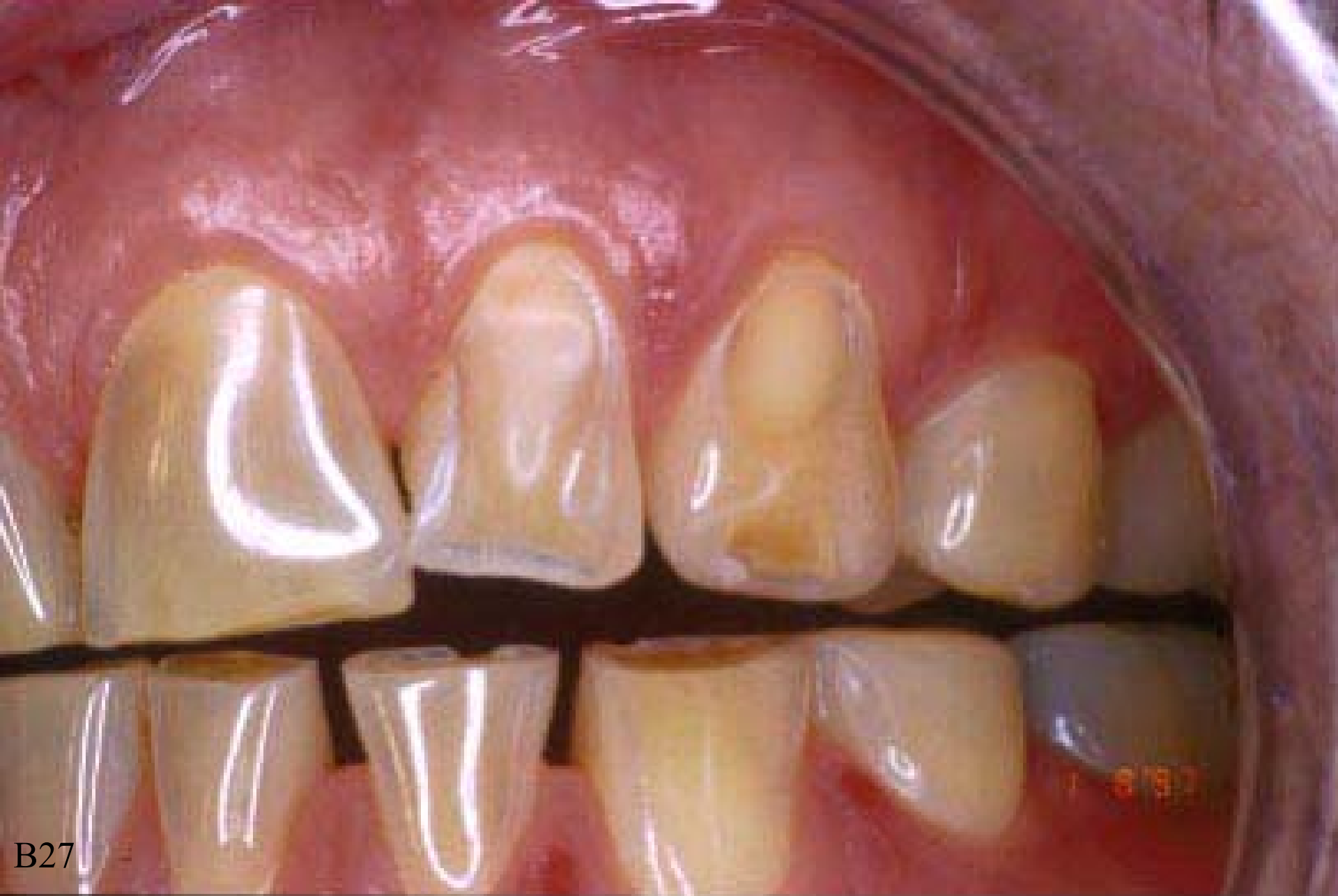B25

Stress lines in maxillary partial. See next slide.



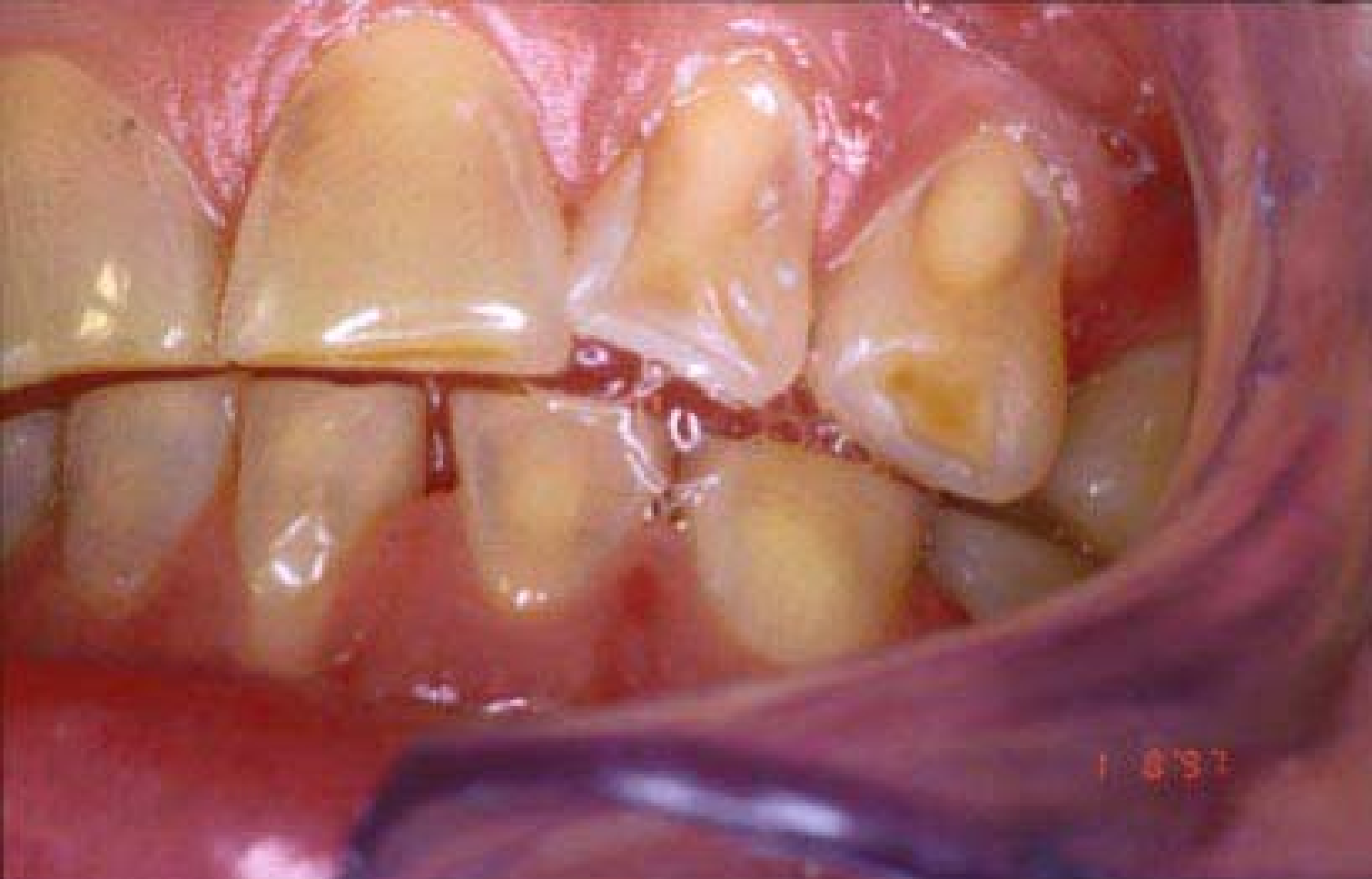B26

Stress lines in maxillary partial. End of case.

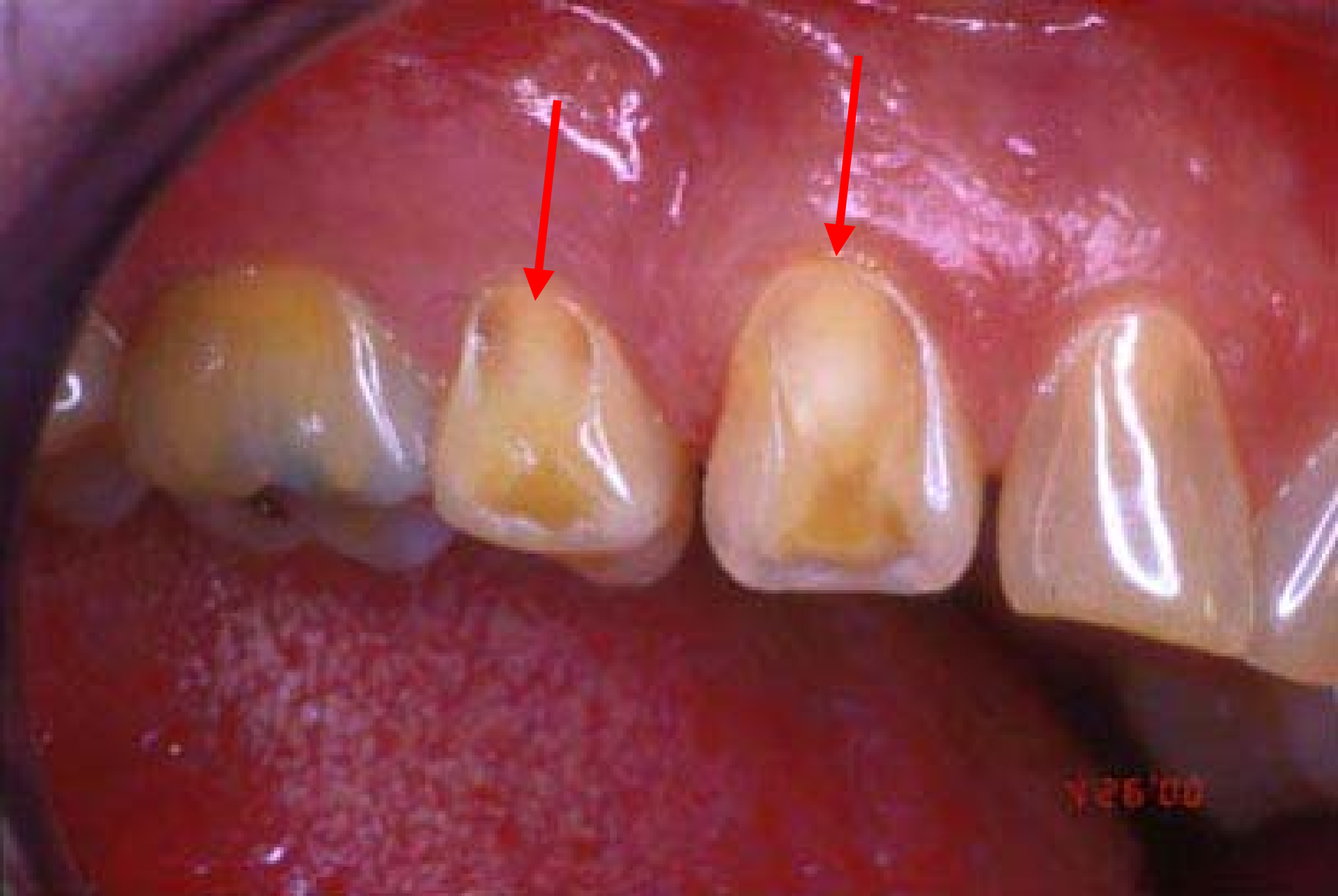

B27

Odd abfractions with flat occlusion. See next 3 slide.

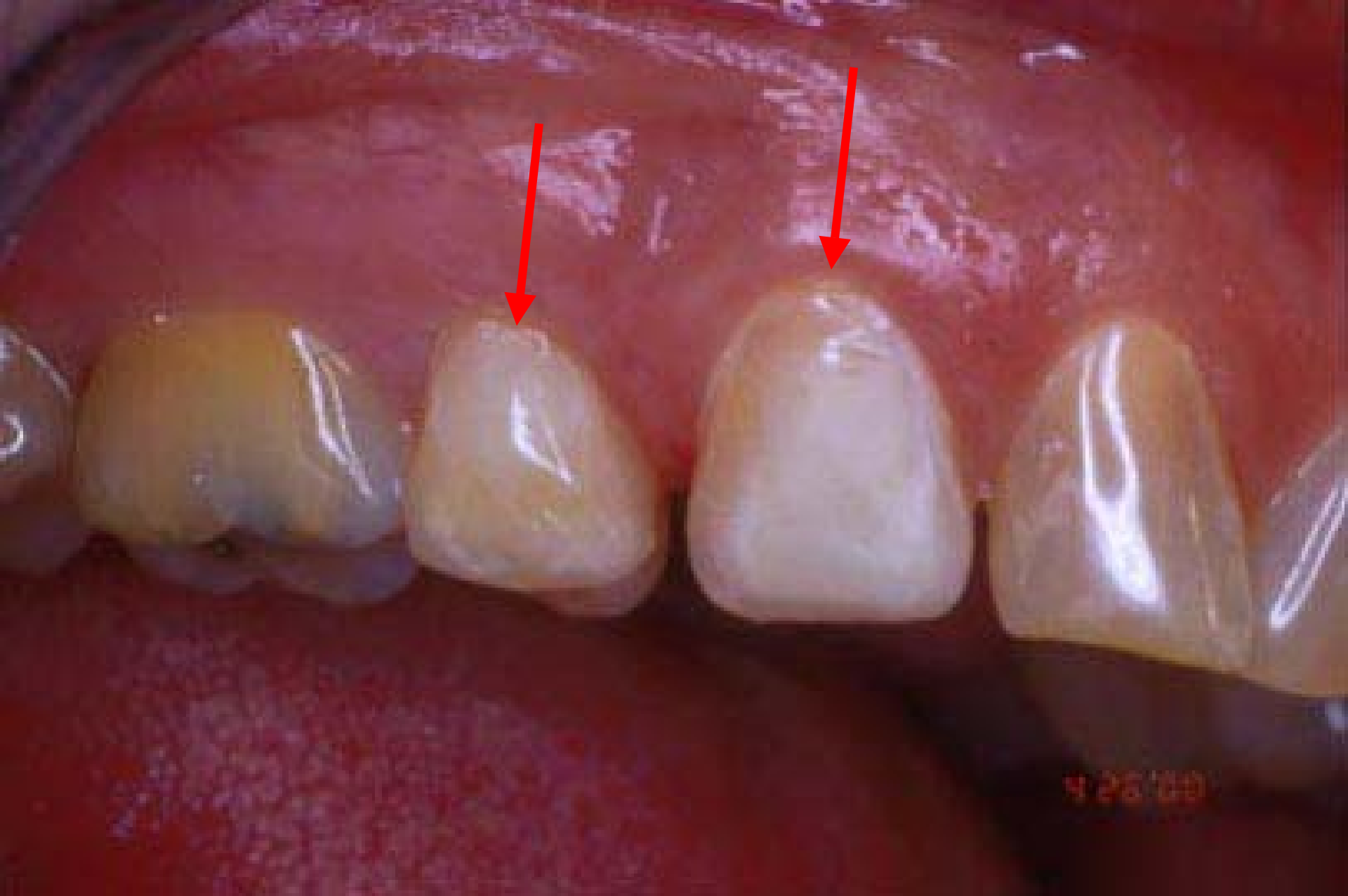

Tongue thrust and saliva coming through  
'open' space. See next 2 slide.

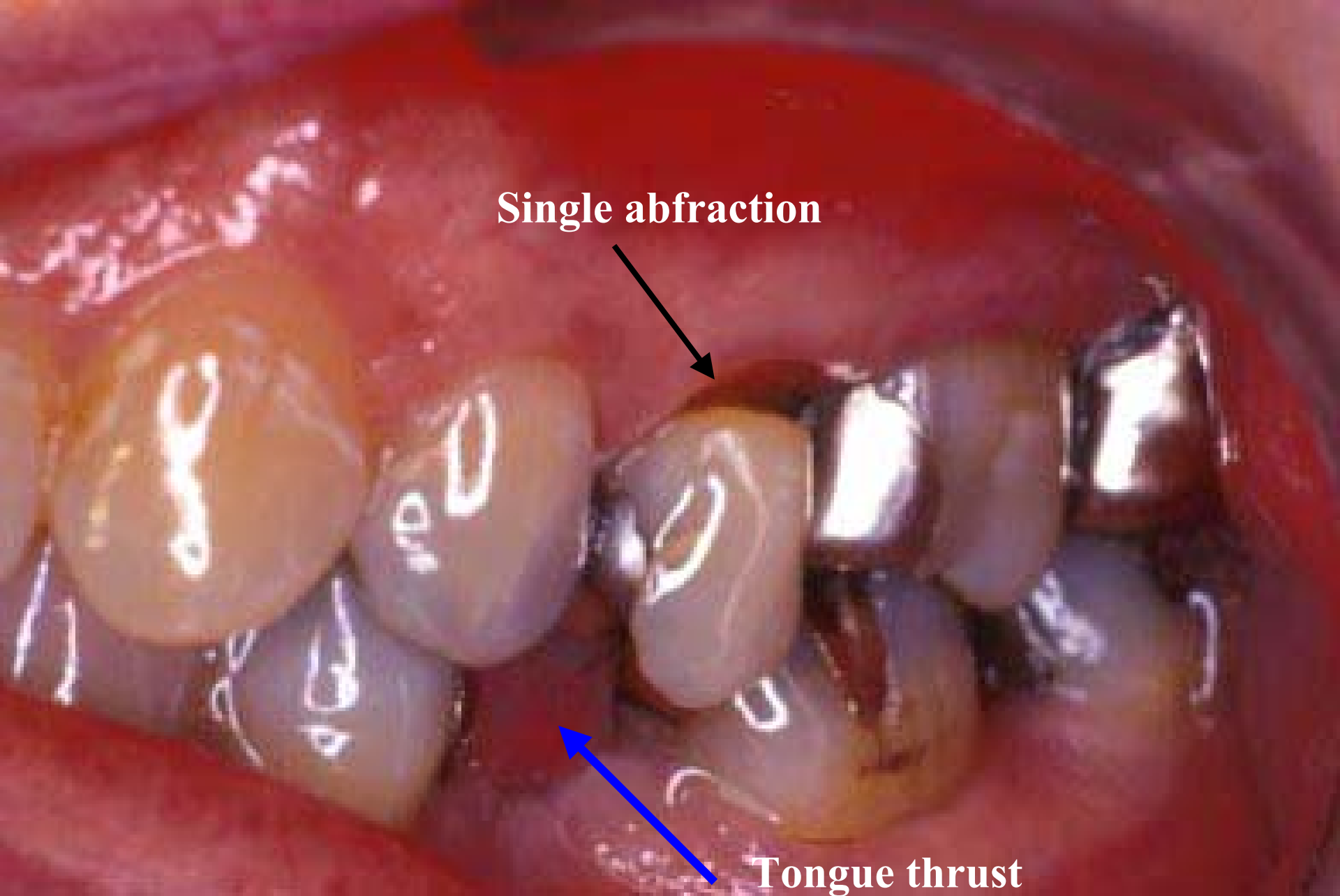


B29

Odd abfractions. See next slide.



B30 Teeth restored (difficult esthetic case).

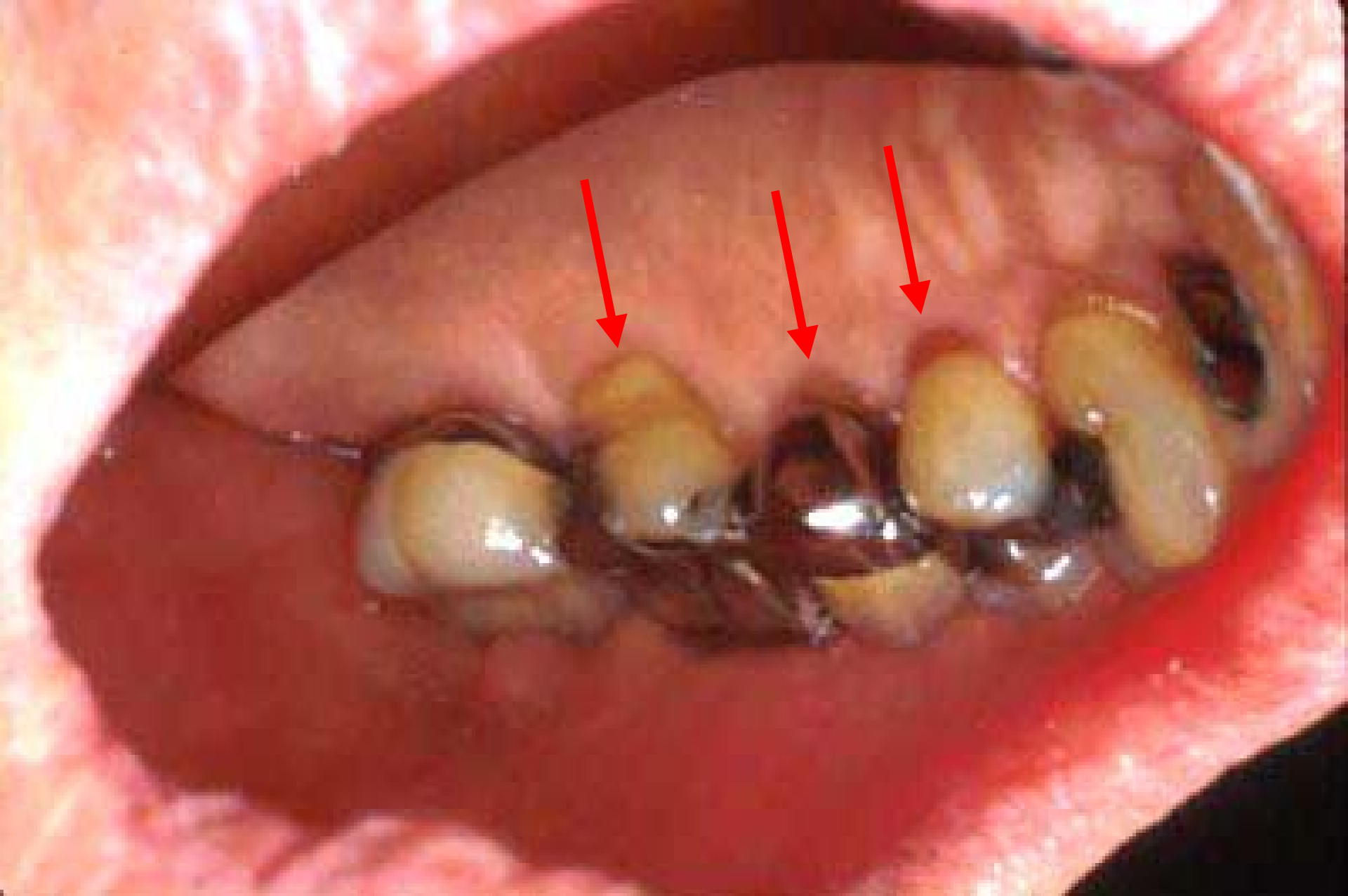

**Single abfraction**

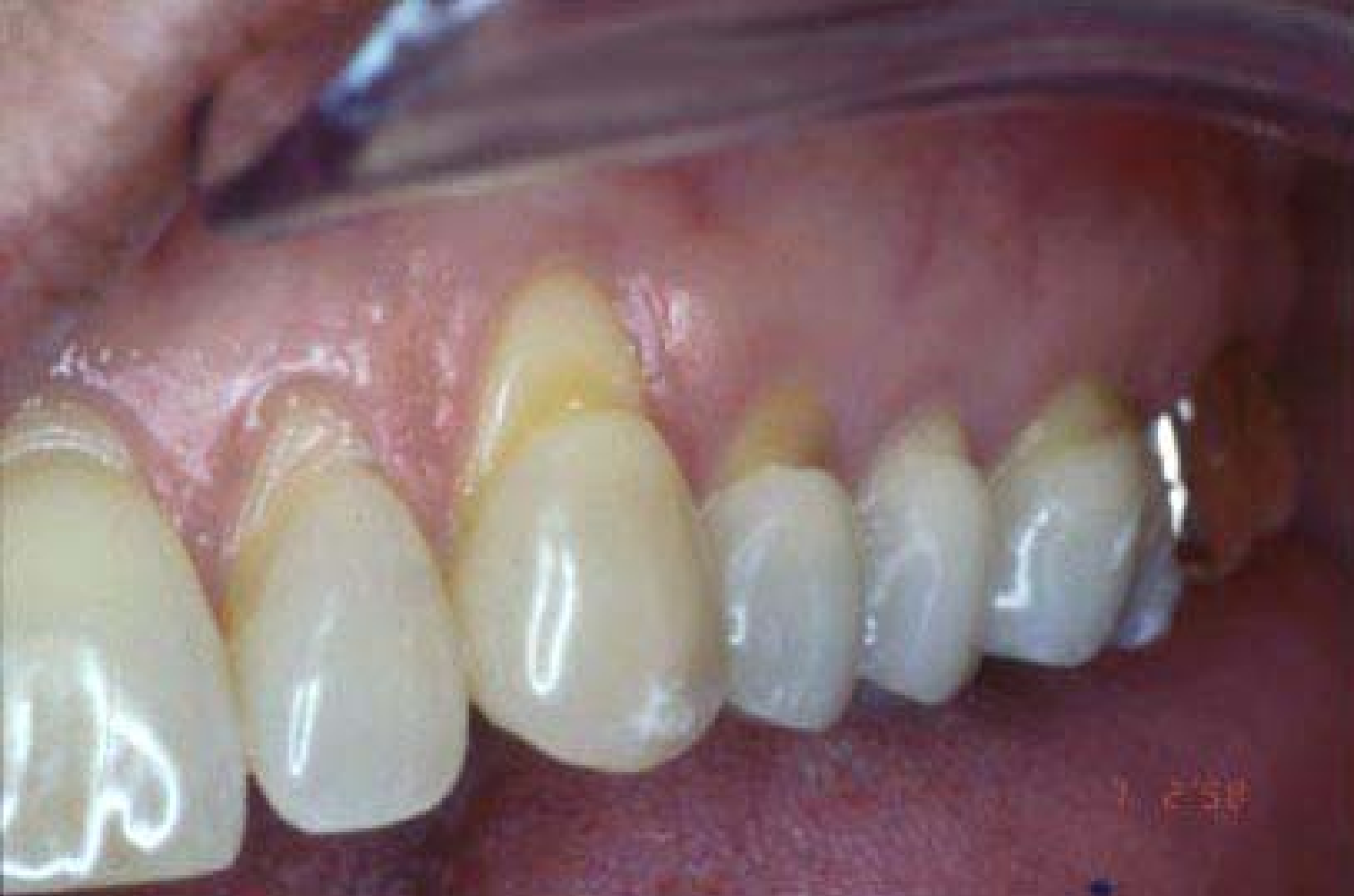**Tongue thrust**

B31

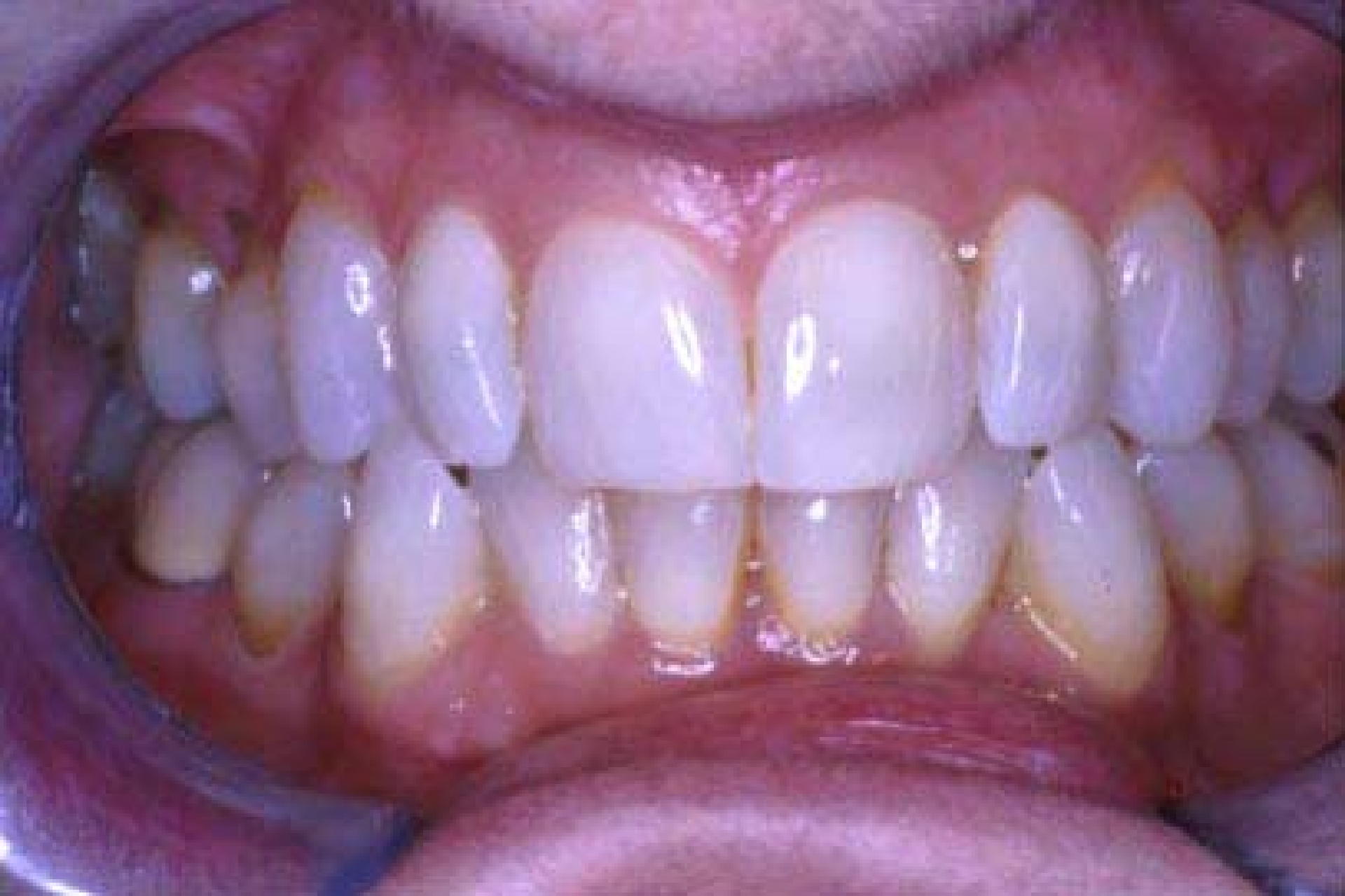**Single abfraction. Note tongue thrust (blue).**



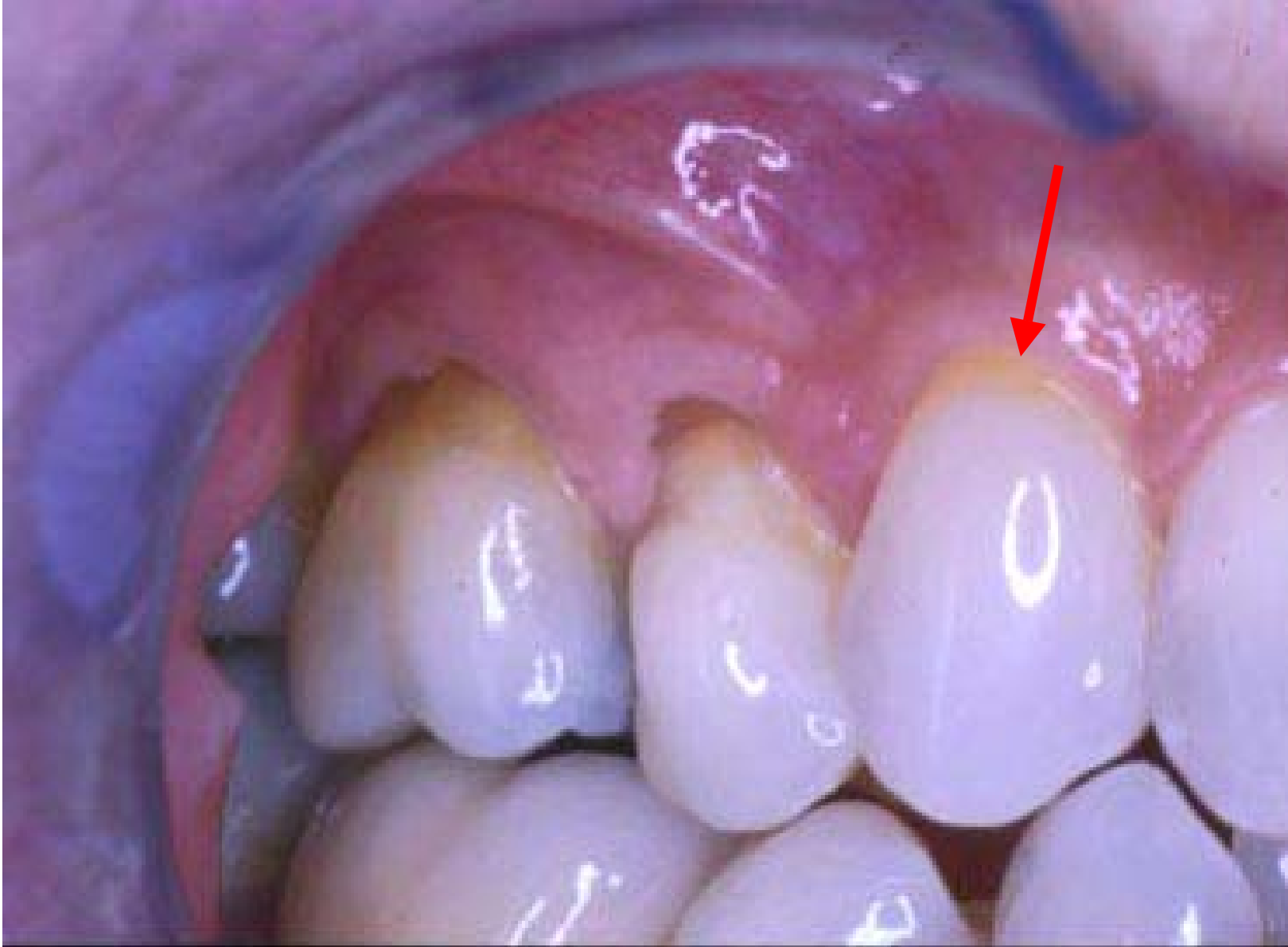
Lingual abfraction.



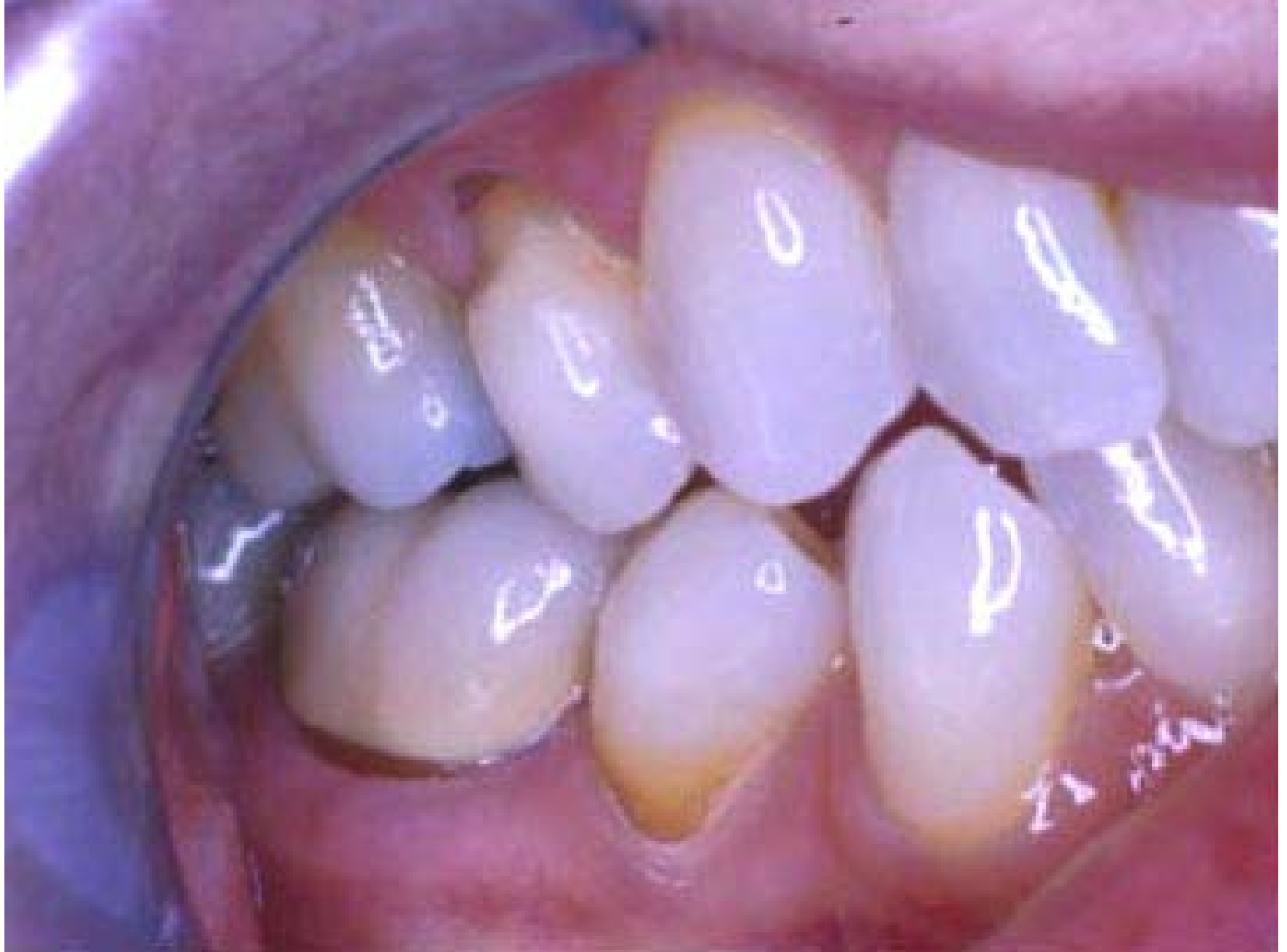Abfractions. Heavy clencher.



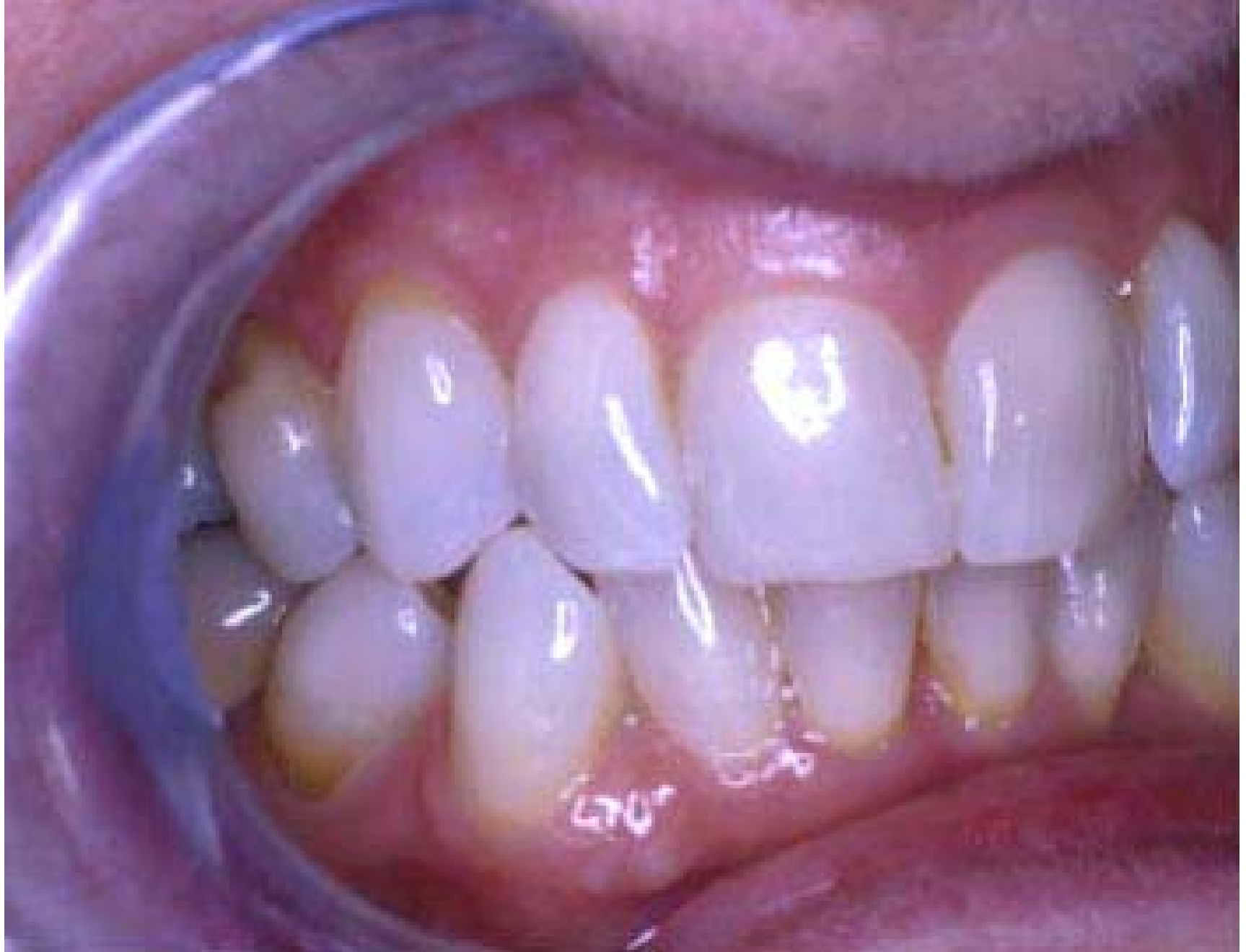B34 Anterior view (Post-whitening). (6 slide case)



Right side. Post ortho malocclusion. Bad angle to cuspid (red arrow). See next slide.

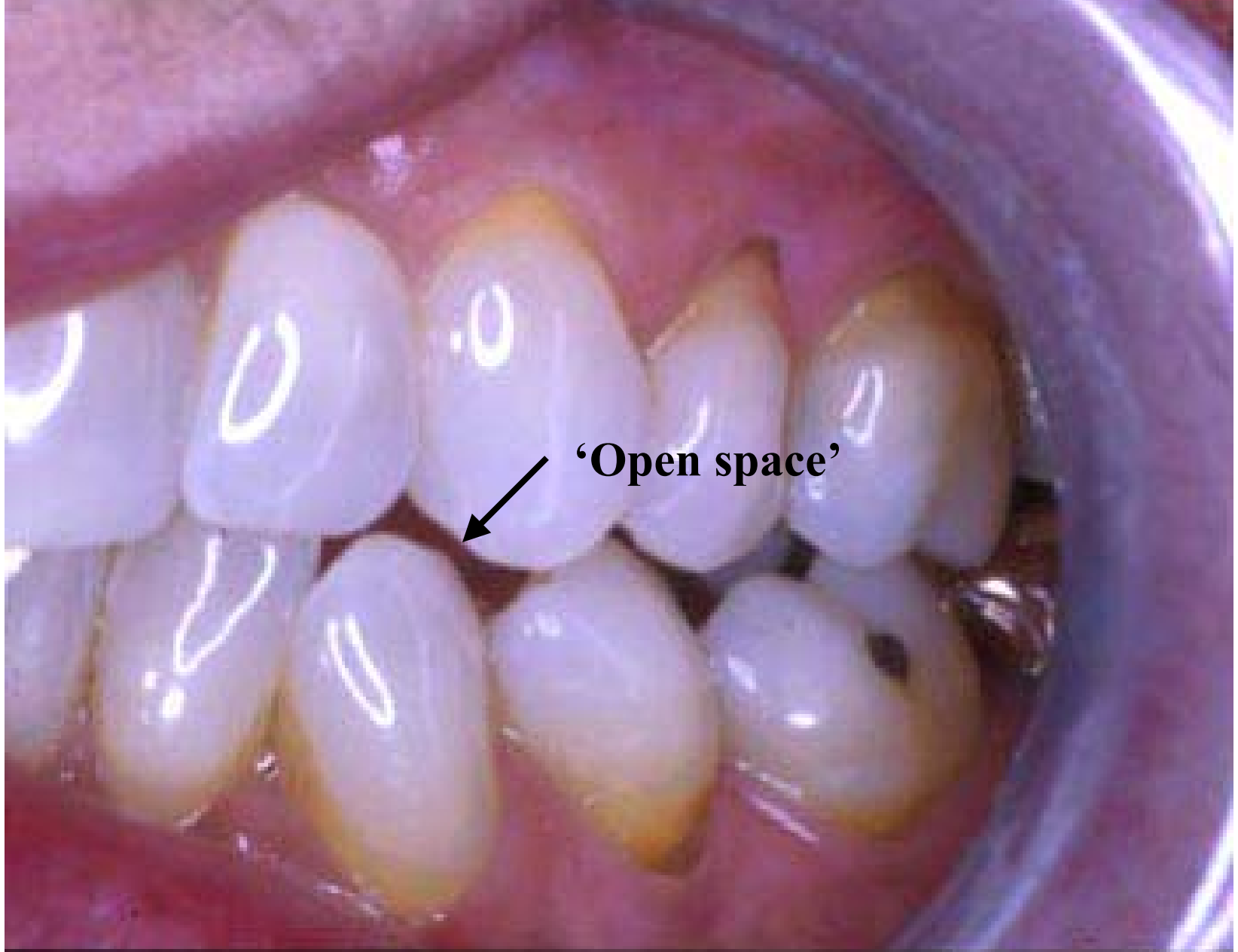


Right side abfractions. See next slide.

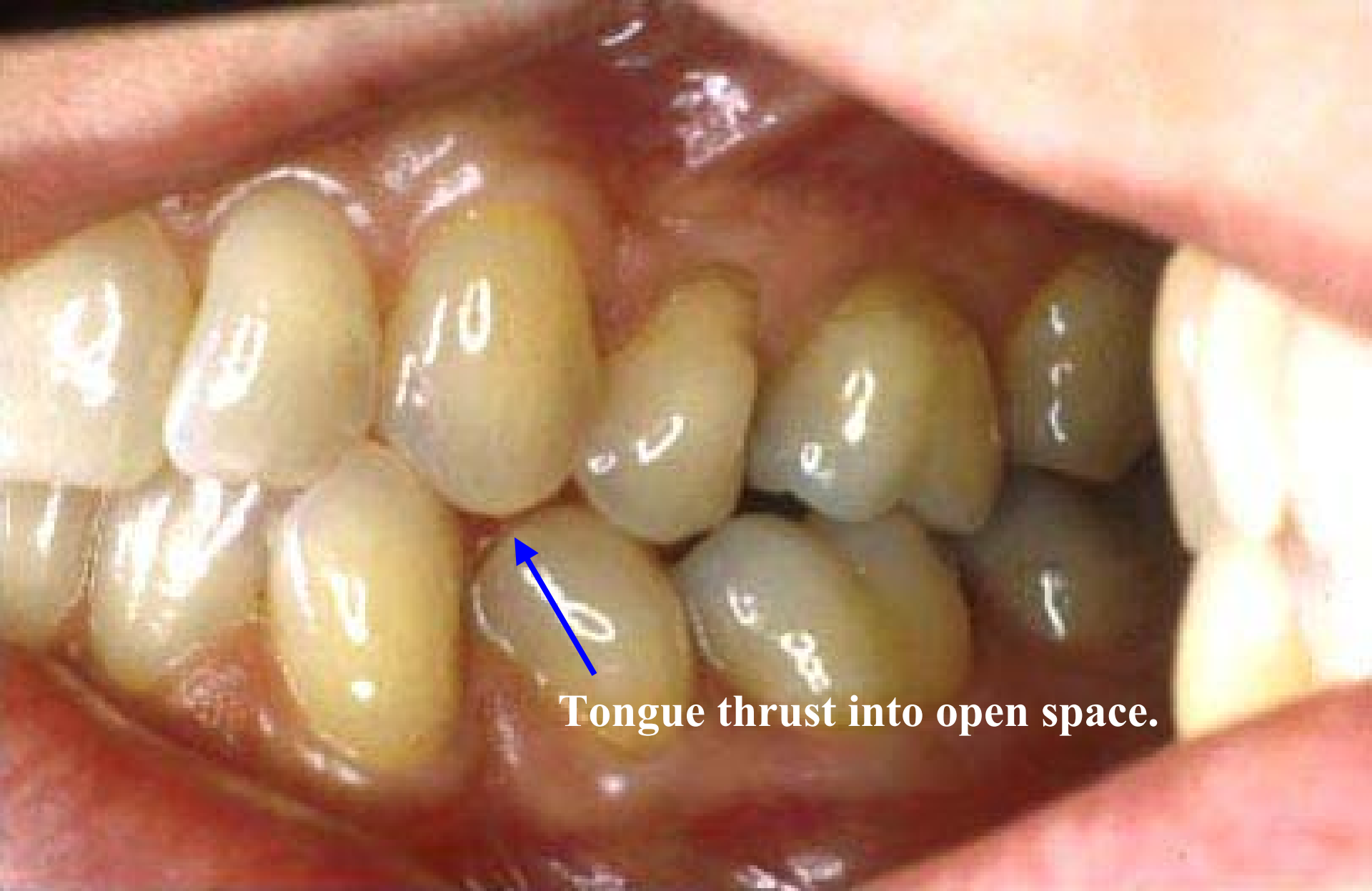


B37

Post-ortho malocclusion. See next slide.



Left side. Note 'open space'. See next slide.



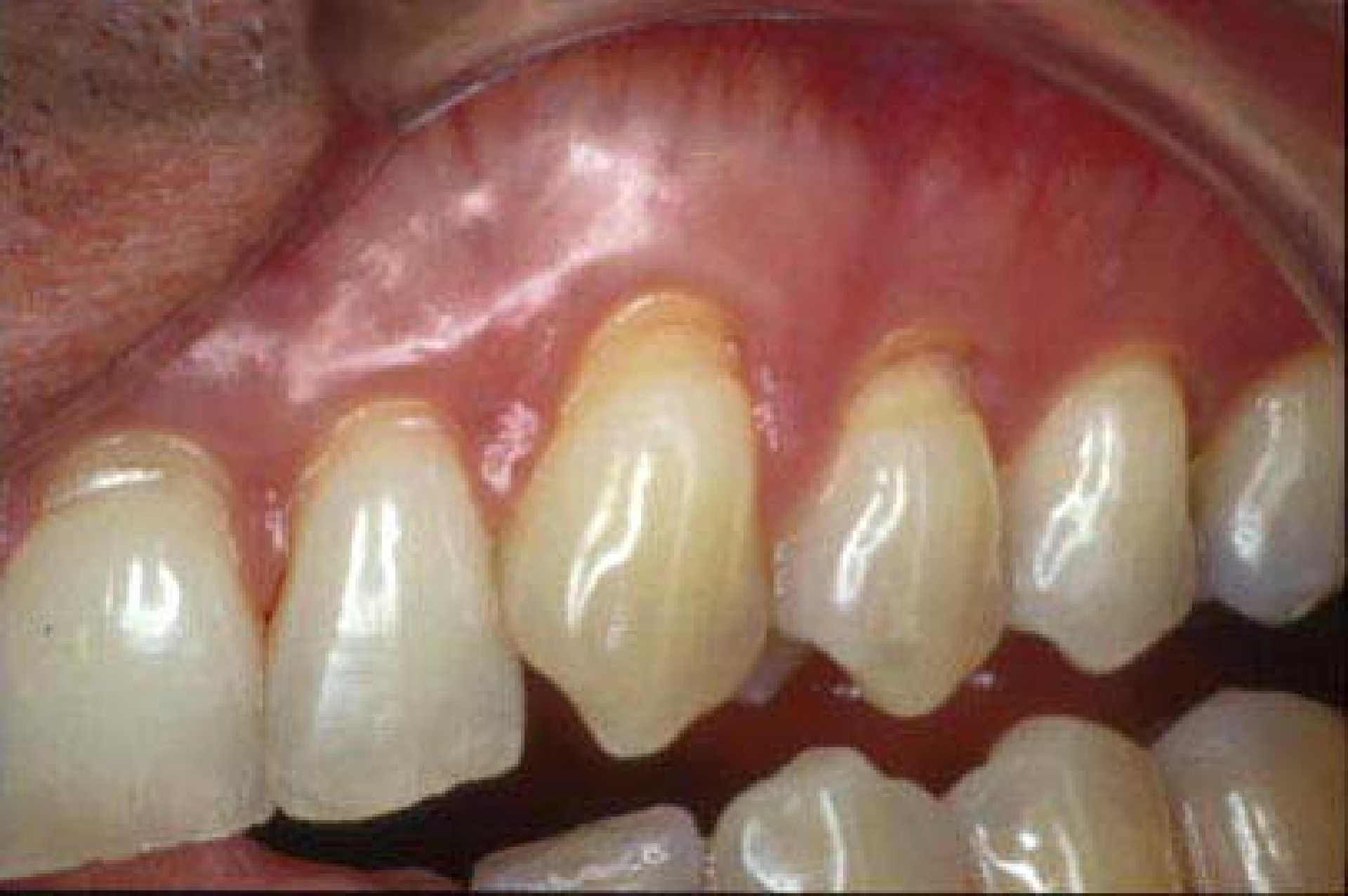Tongue thrust into open space.

Reflective view of right side. Note tongue position and

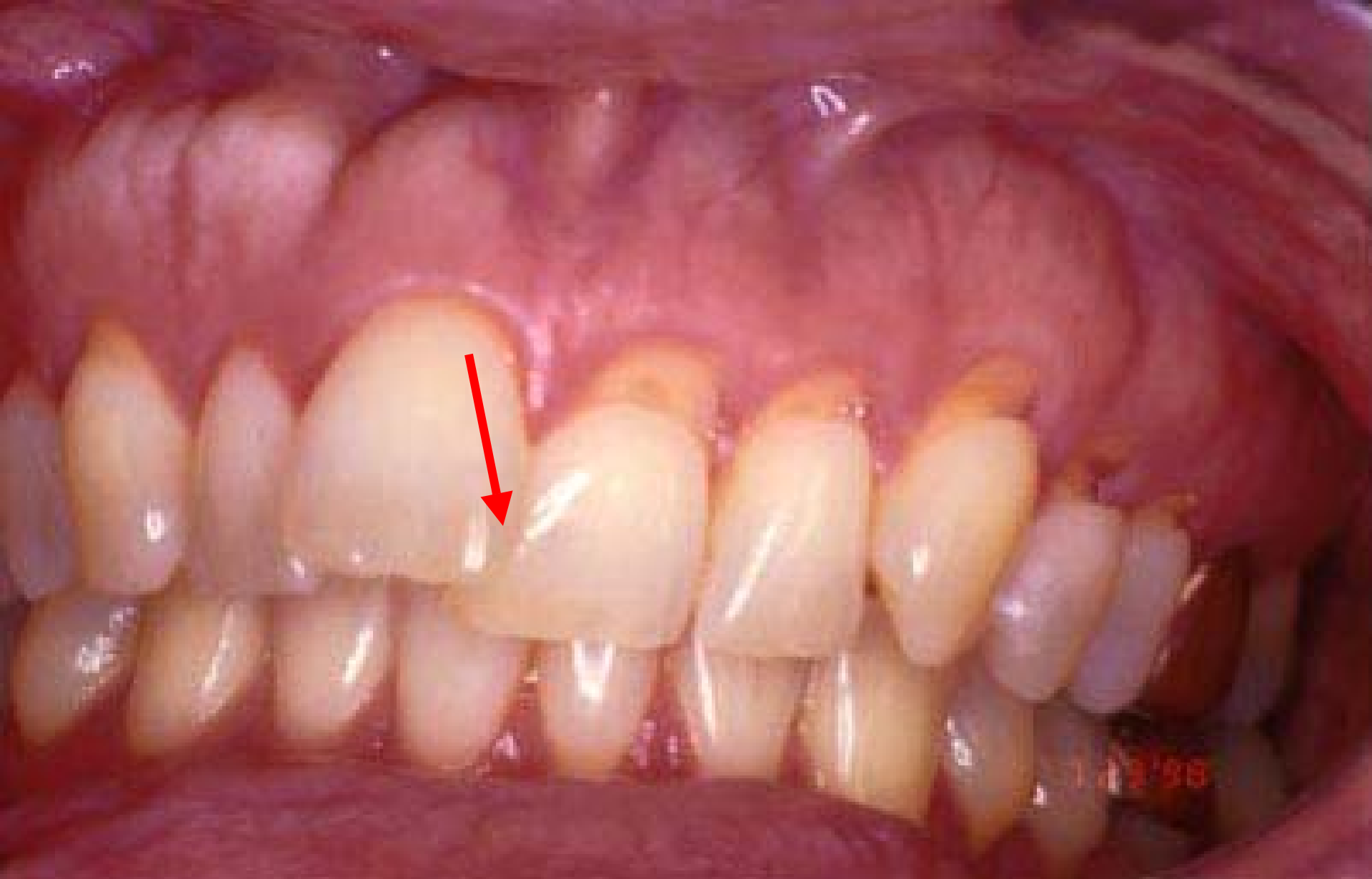B39

4 bi ortho malocclusion (Pre-whitening). End of case.

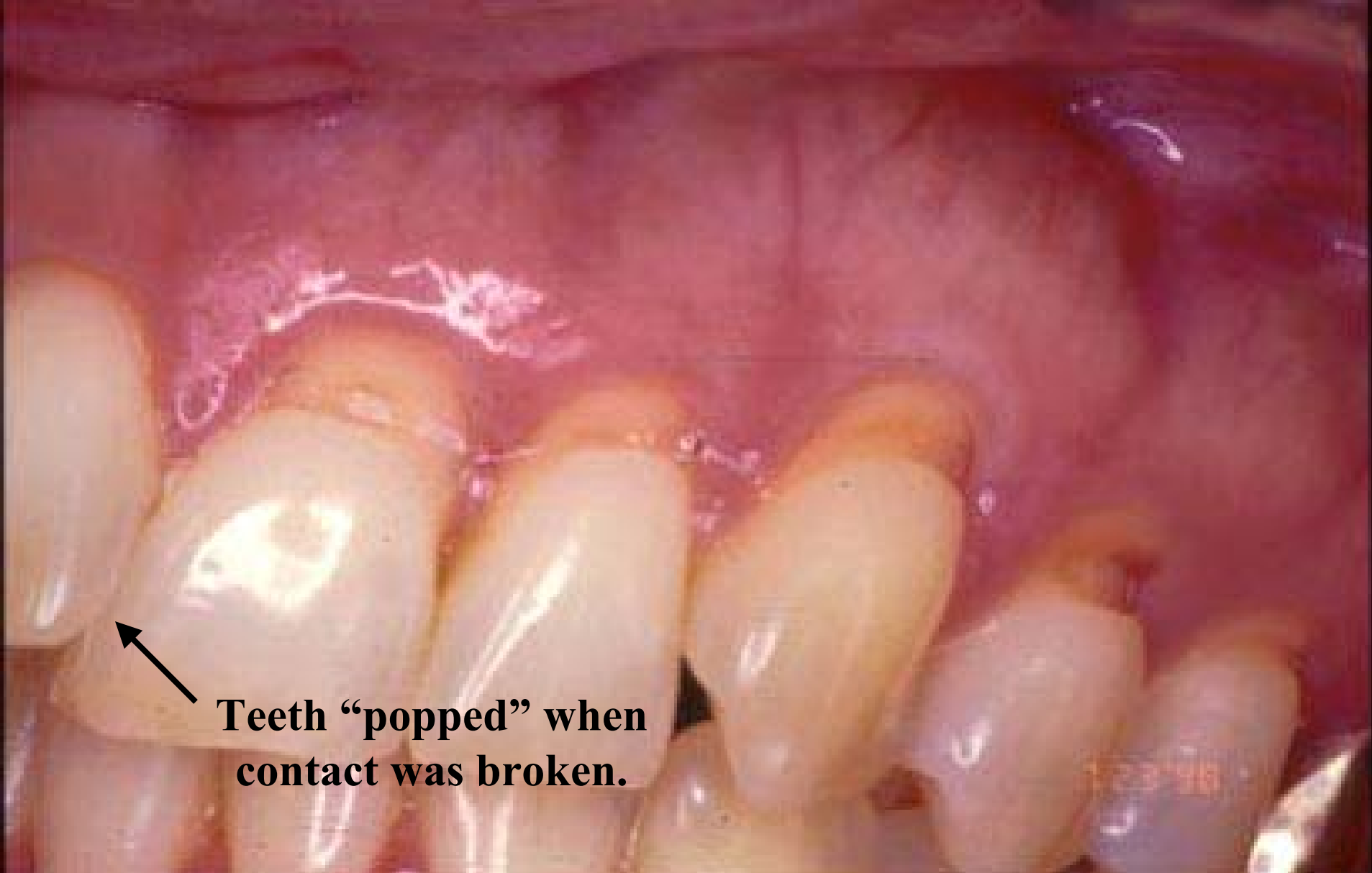
The following case of 8 slides was the most difficult case for me to determine the reason for his abstractions. It took me about 10 years to determine the reason for his abstractions.



B41 1993 Early stages of abfraction. See next 7 slides.

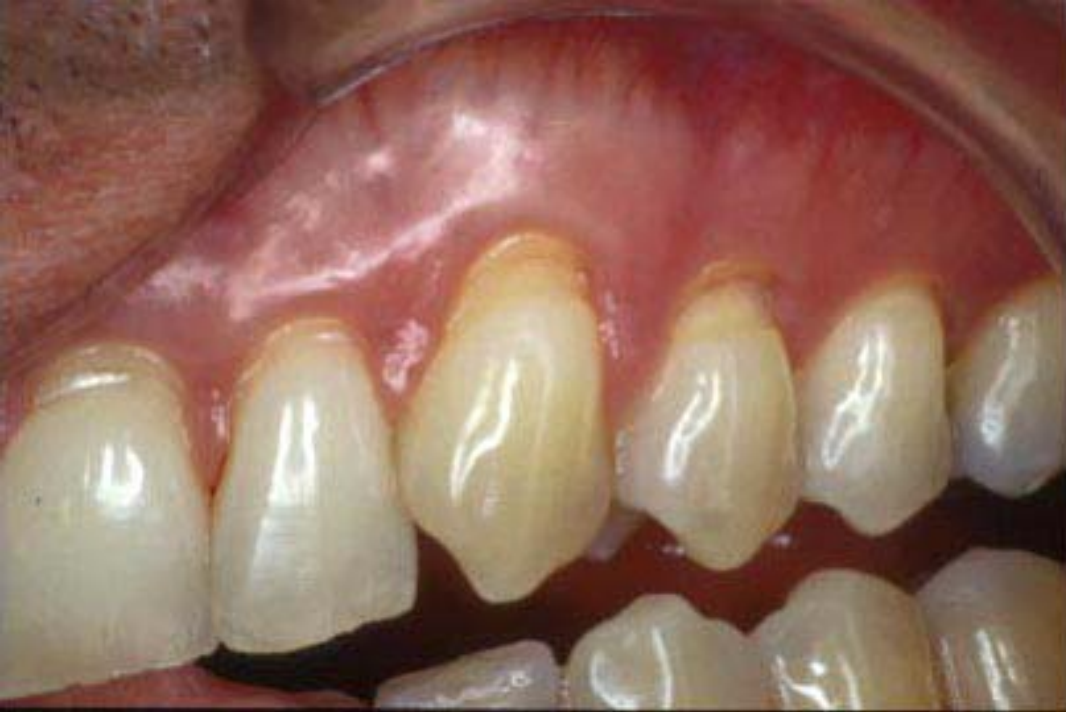

1998 - Teeth “popped” when contact between the centrals was broken. See next 6 slides.

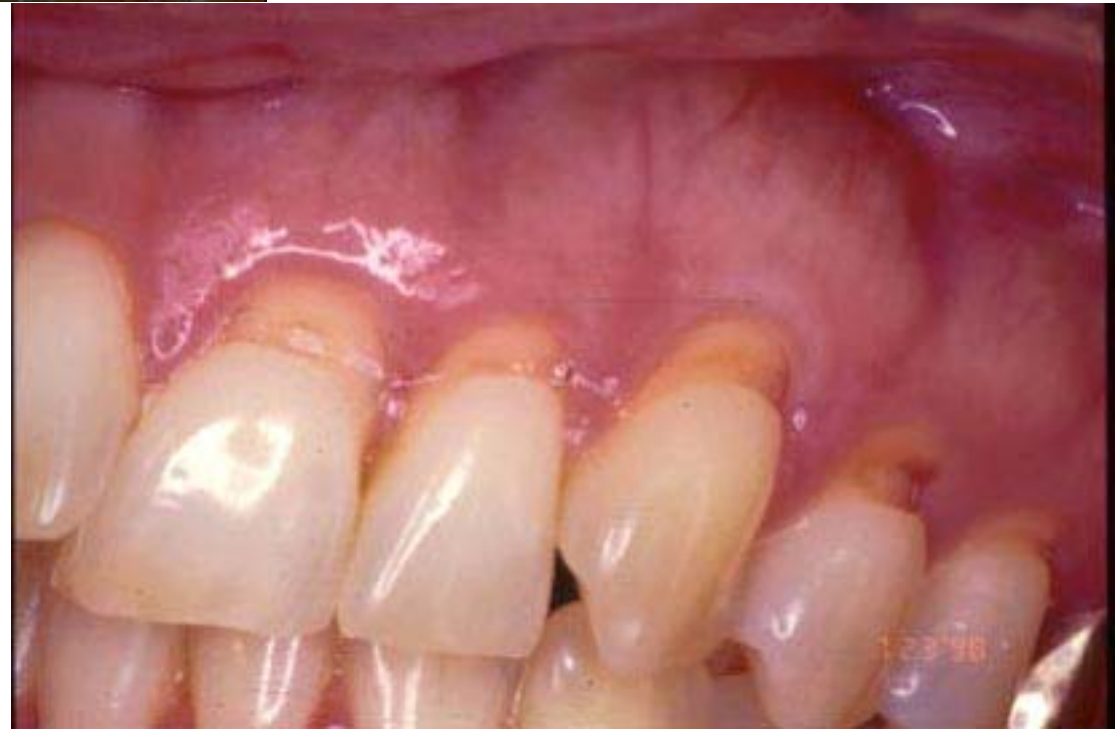

**Teeth "popped" when  
contact was broken.**

**1998 - Teeth just "popped" when  
contact was broken. See next 5 slides.**



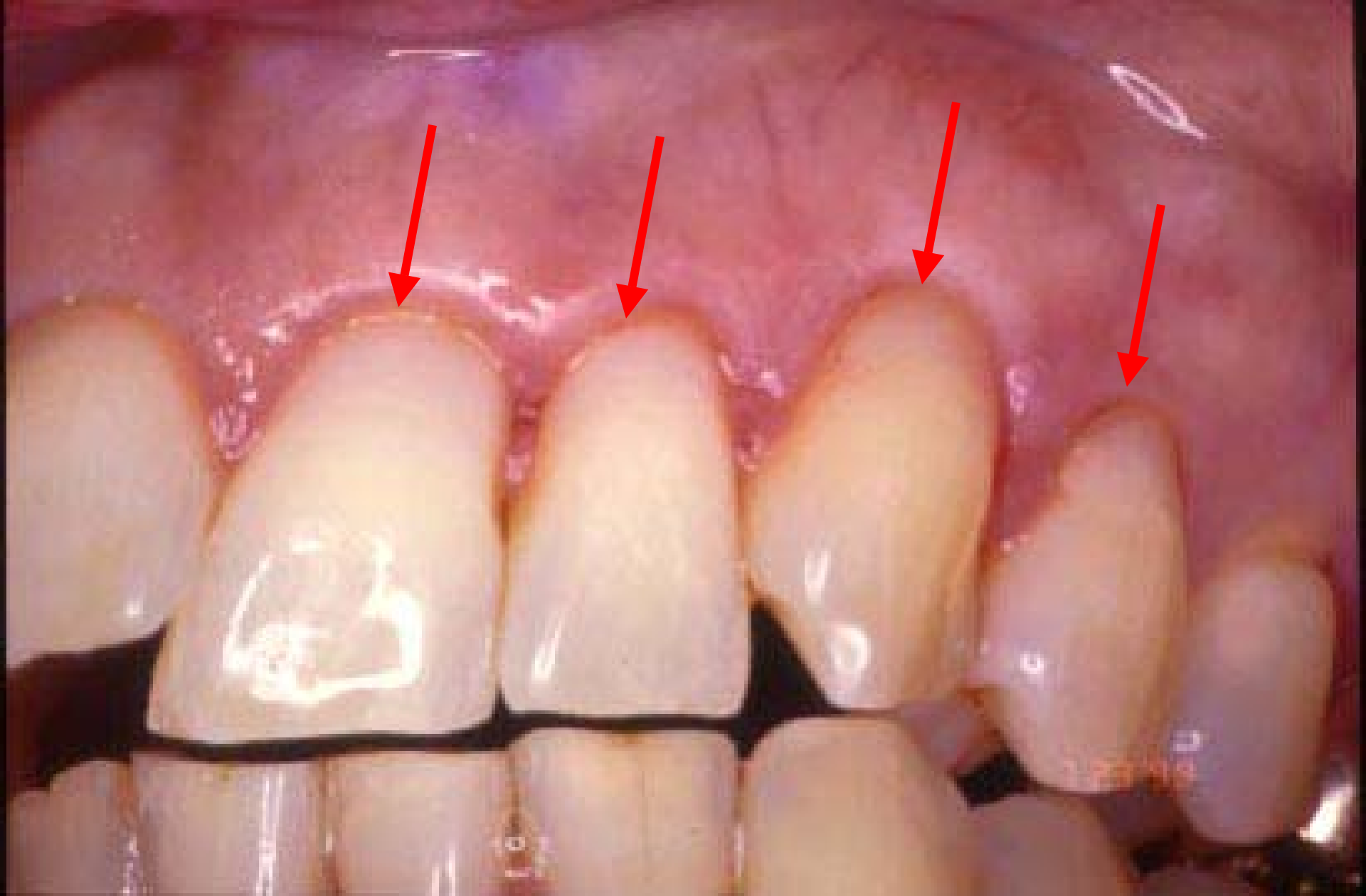
1993  
←



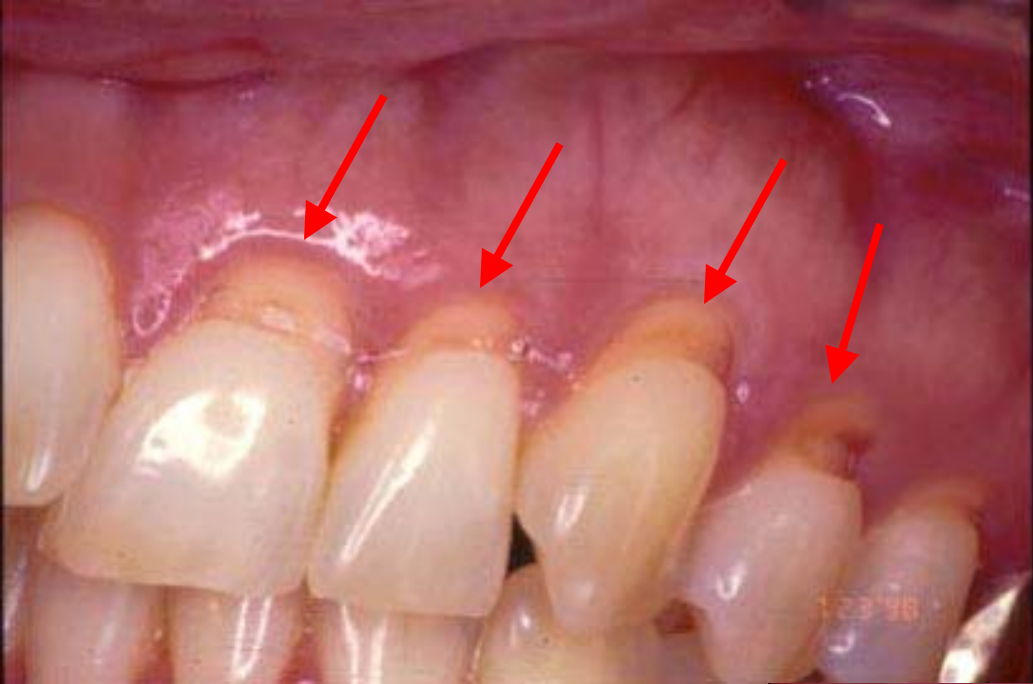1998  
→

B44

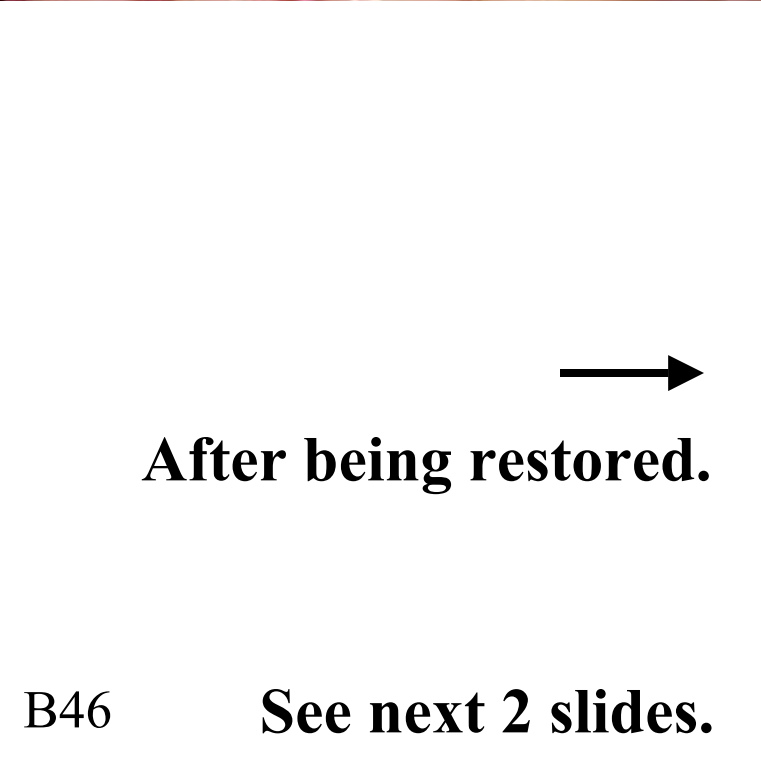
See next 4 slides.



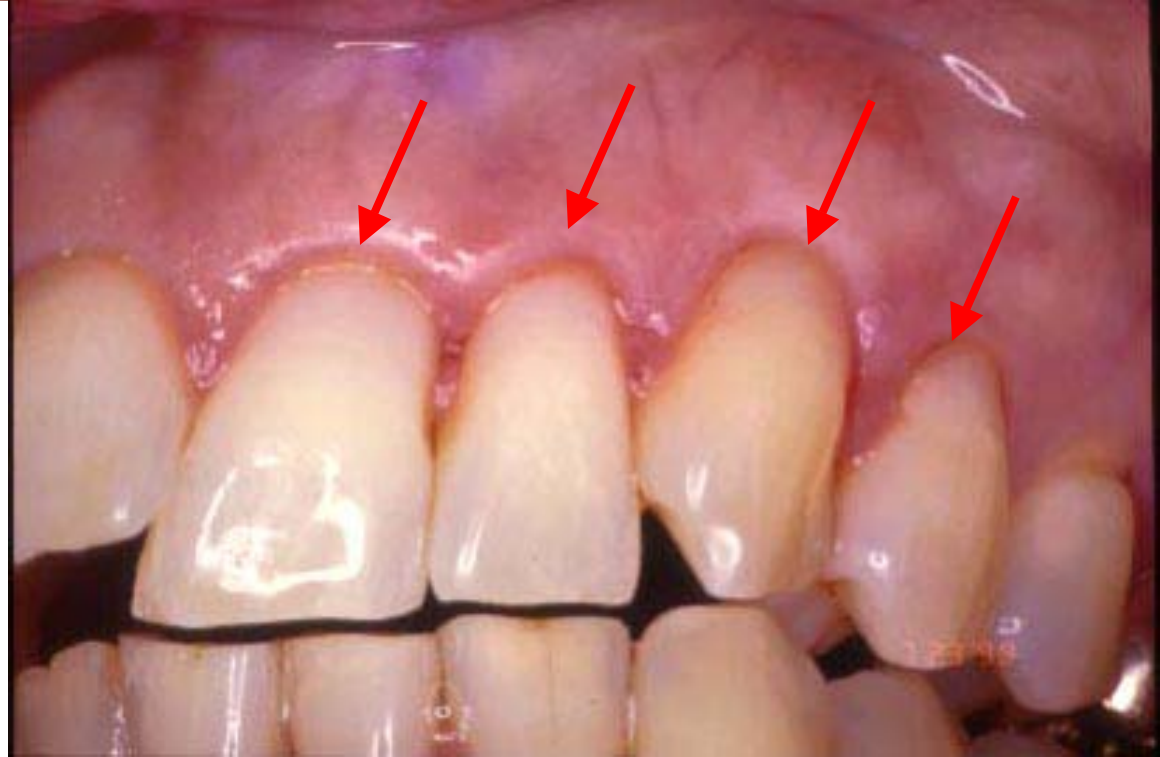1998 Abfractions restored. See next 3 slides.

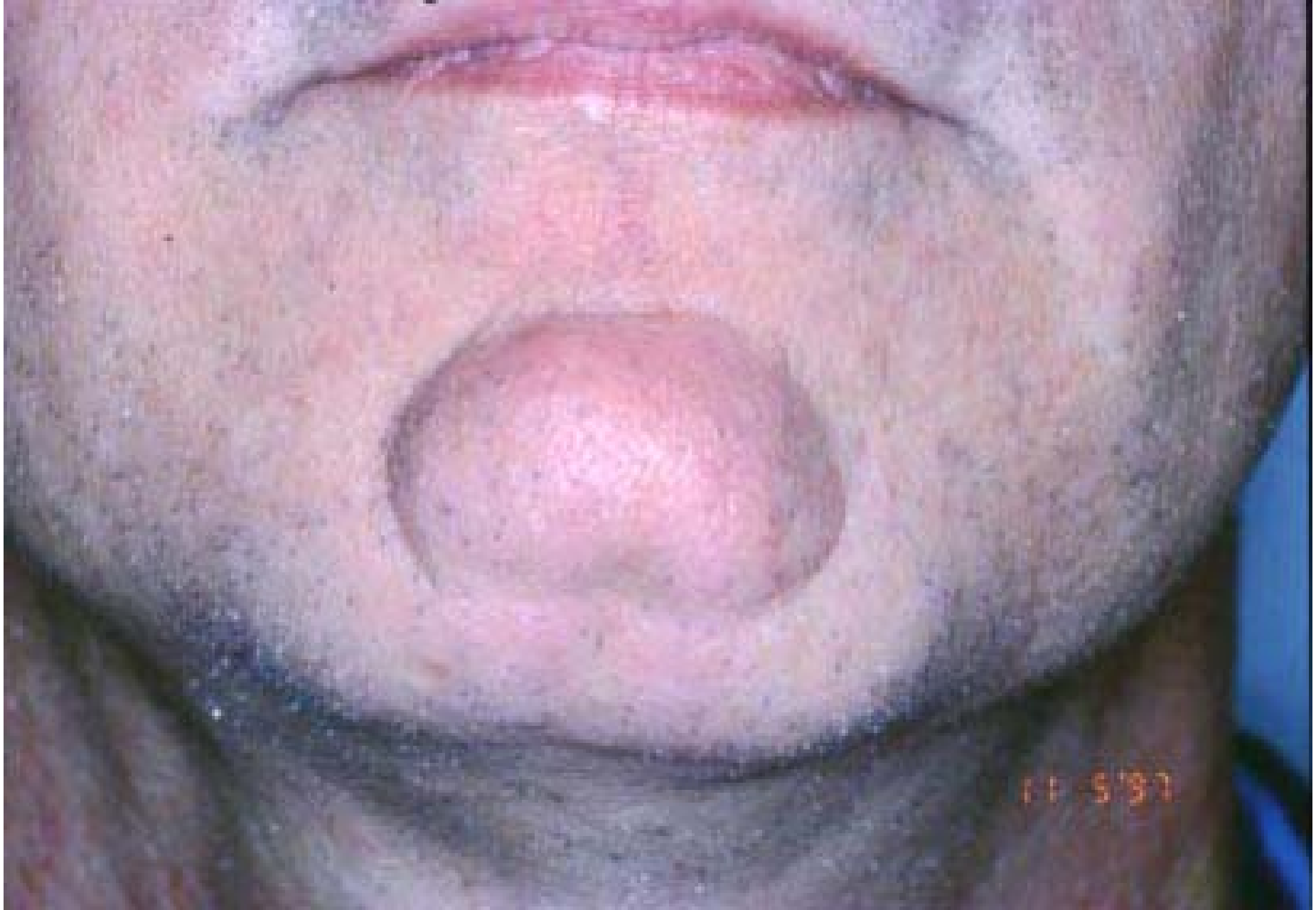

**Before being restored.**

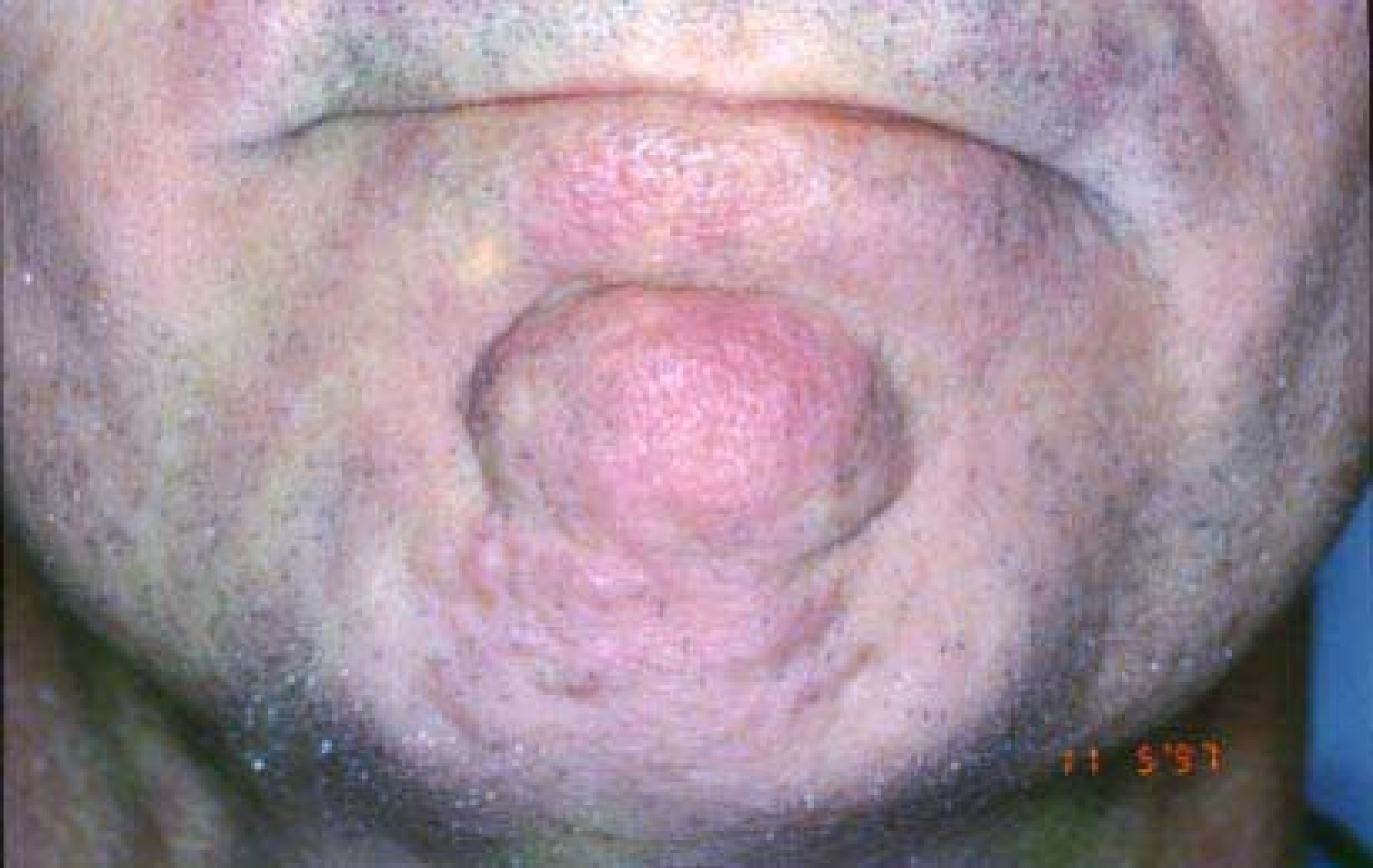

**After being restored.**

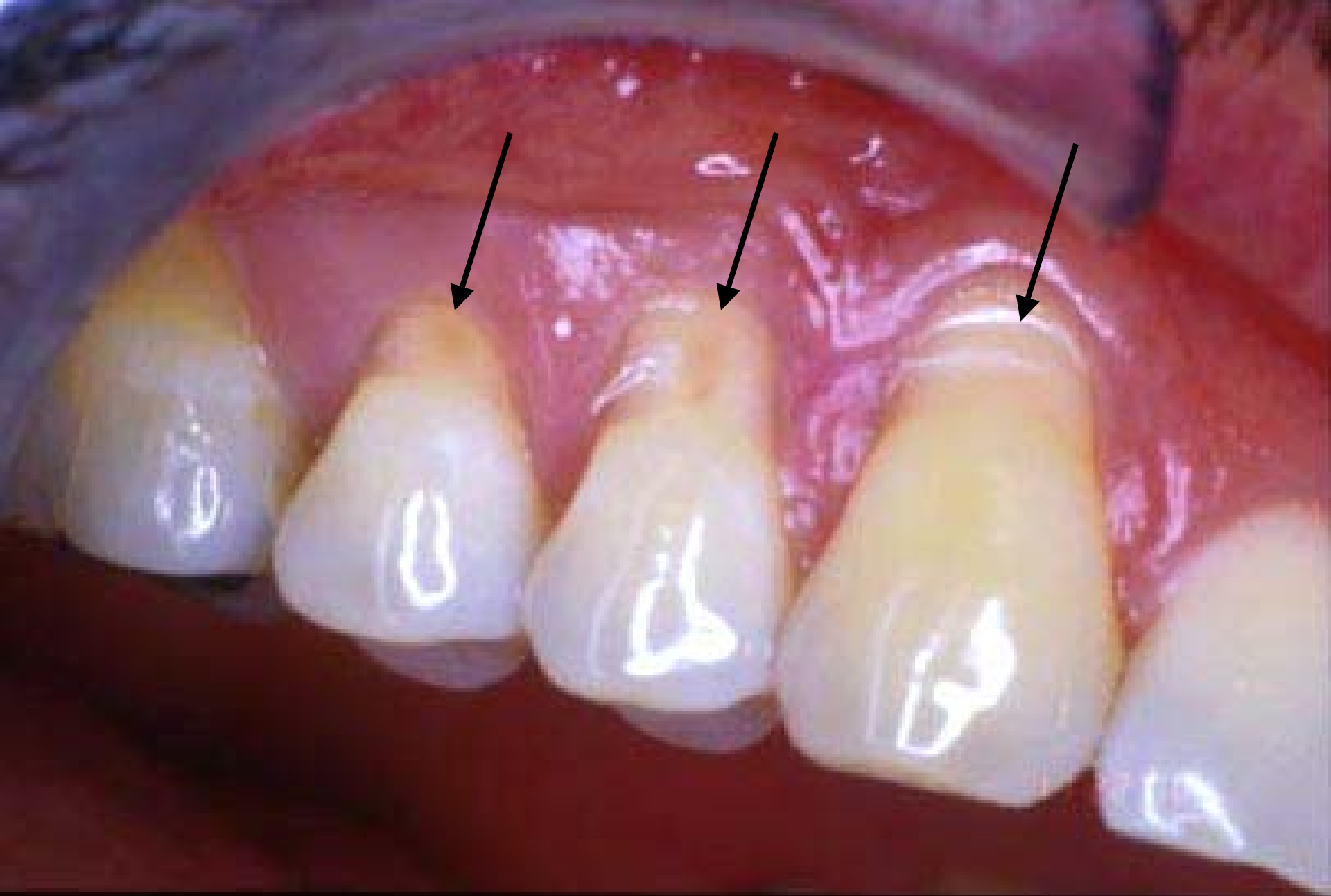




B47 1997 Mentalis (chin muscle) at rest. See next slide.

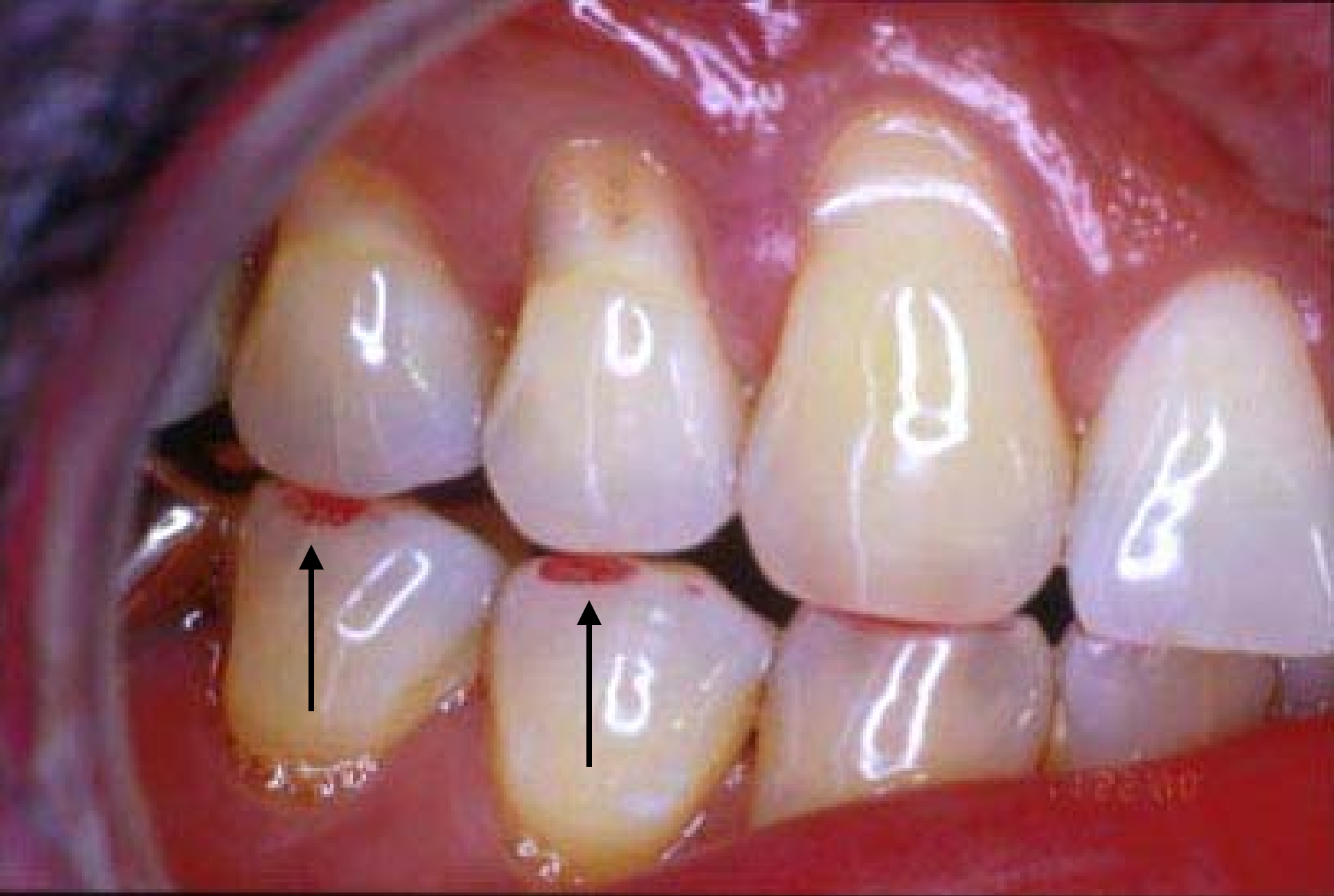


1997 - Hyperactivity of mentalis muscle during a normal swallow. End of case.

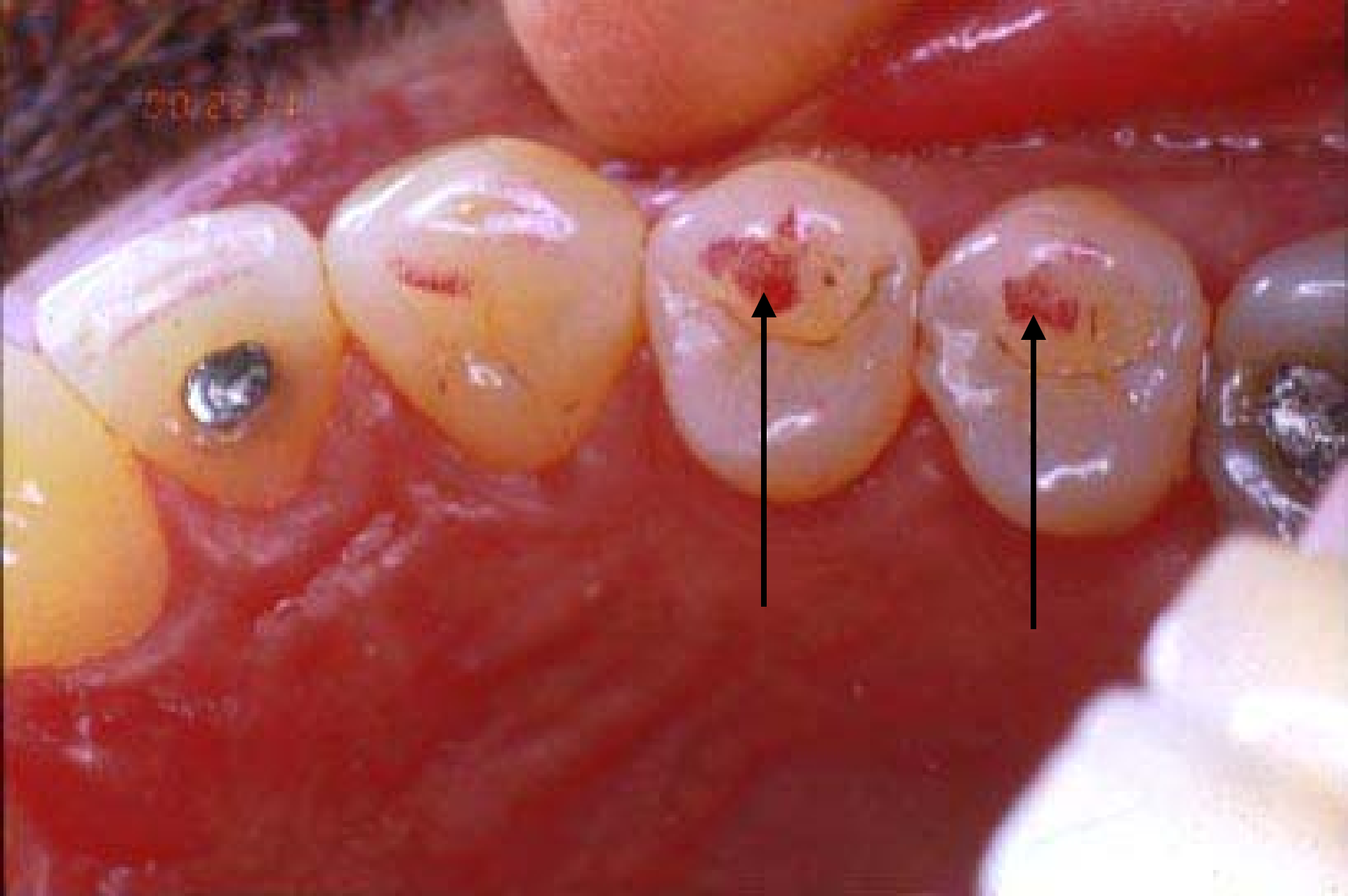


B49

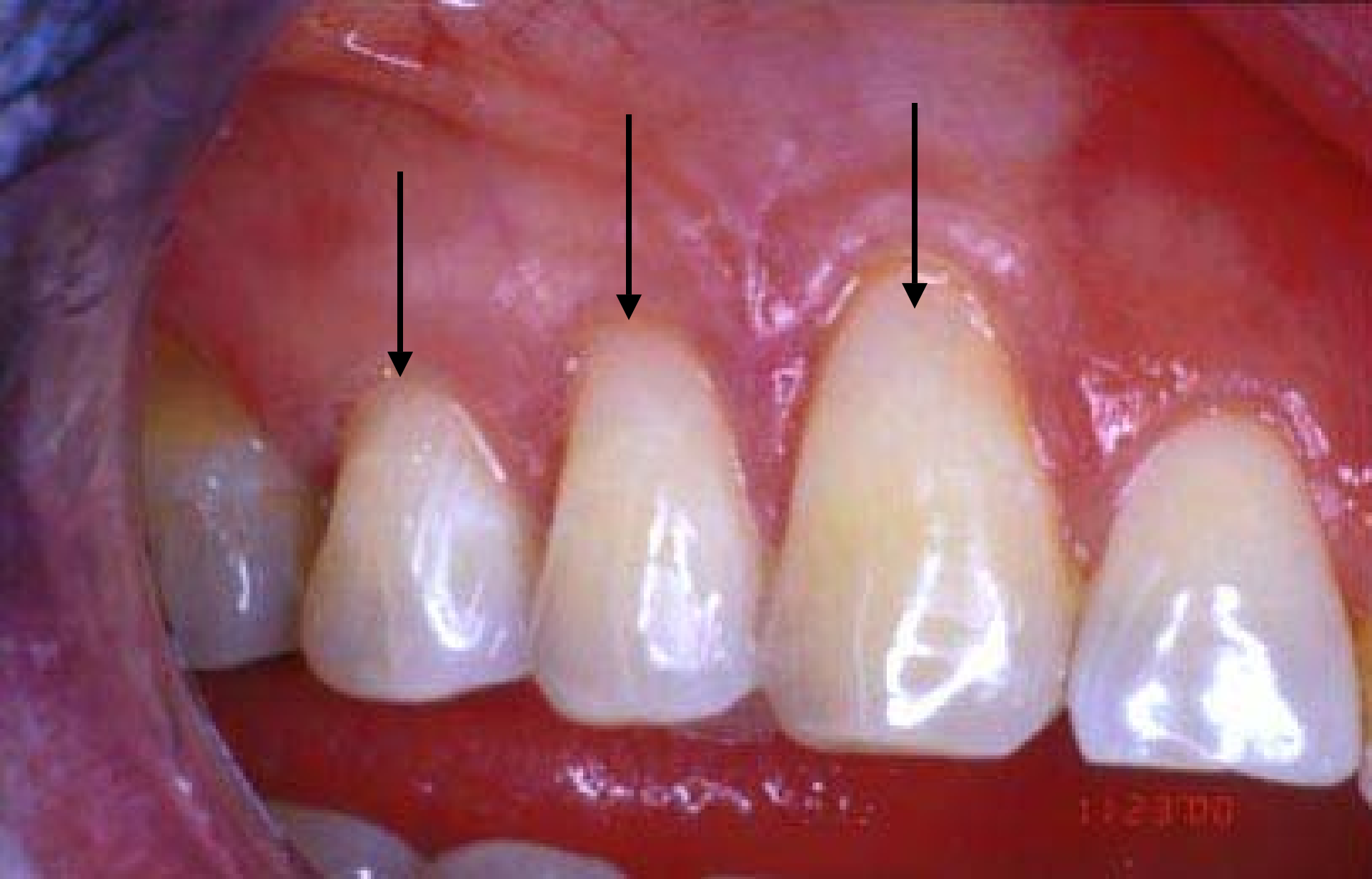
3 abfractions. See next 4 slides.



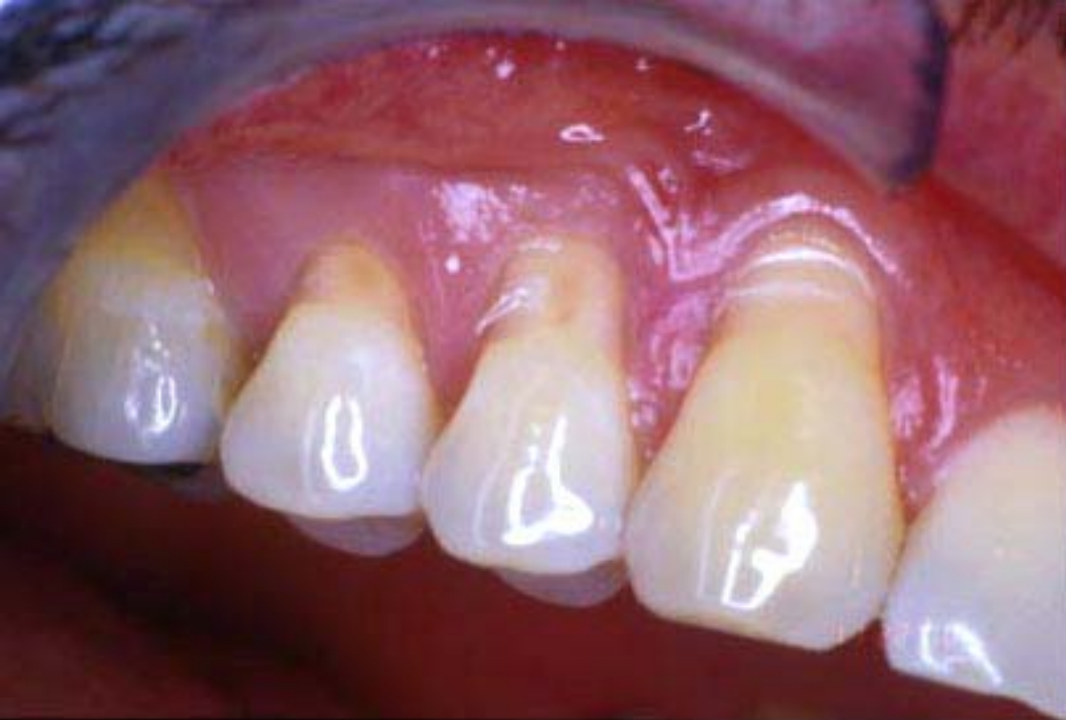B50 Interferences in excursion. See next 3 slides.



B51 Interferences on inclines. See next 2 slides.

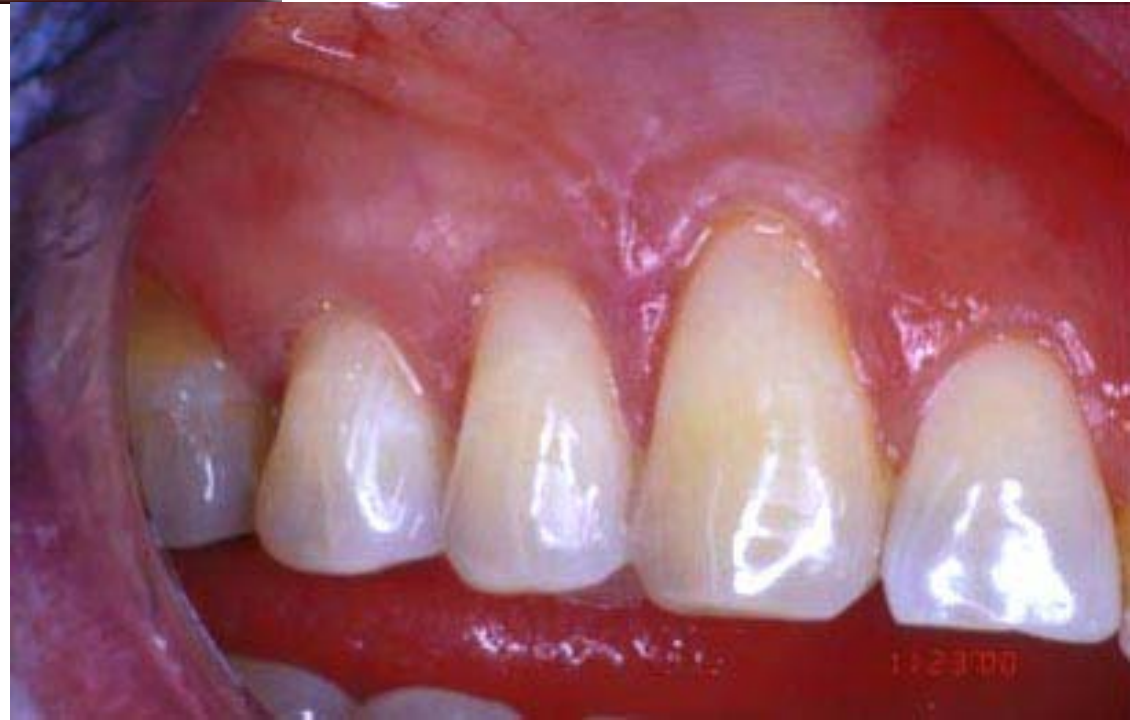

Abfractions restored. See next slide.



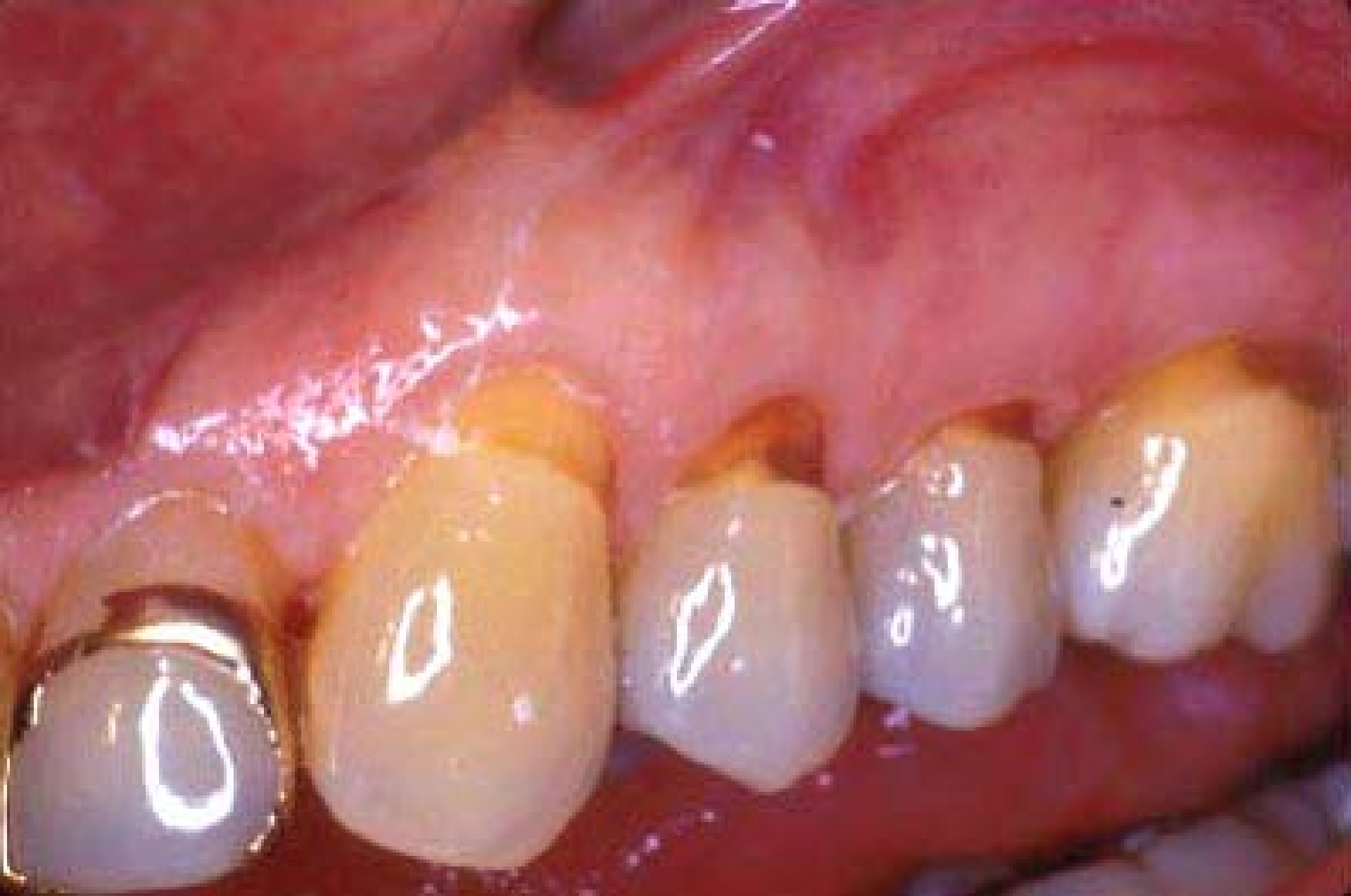← **Before**

**After restorations** →

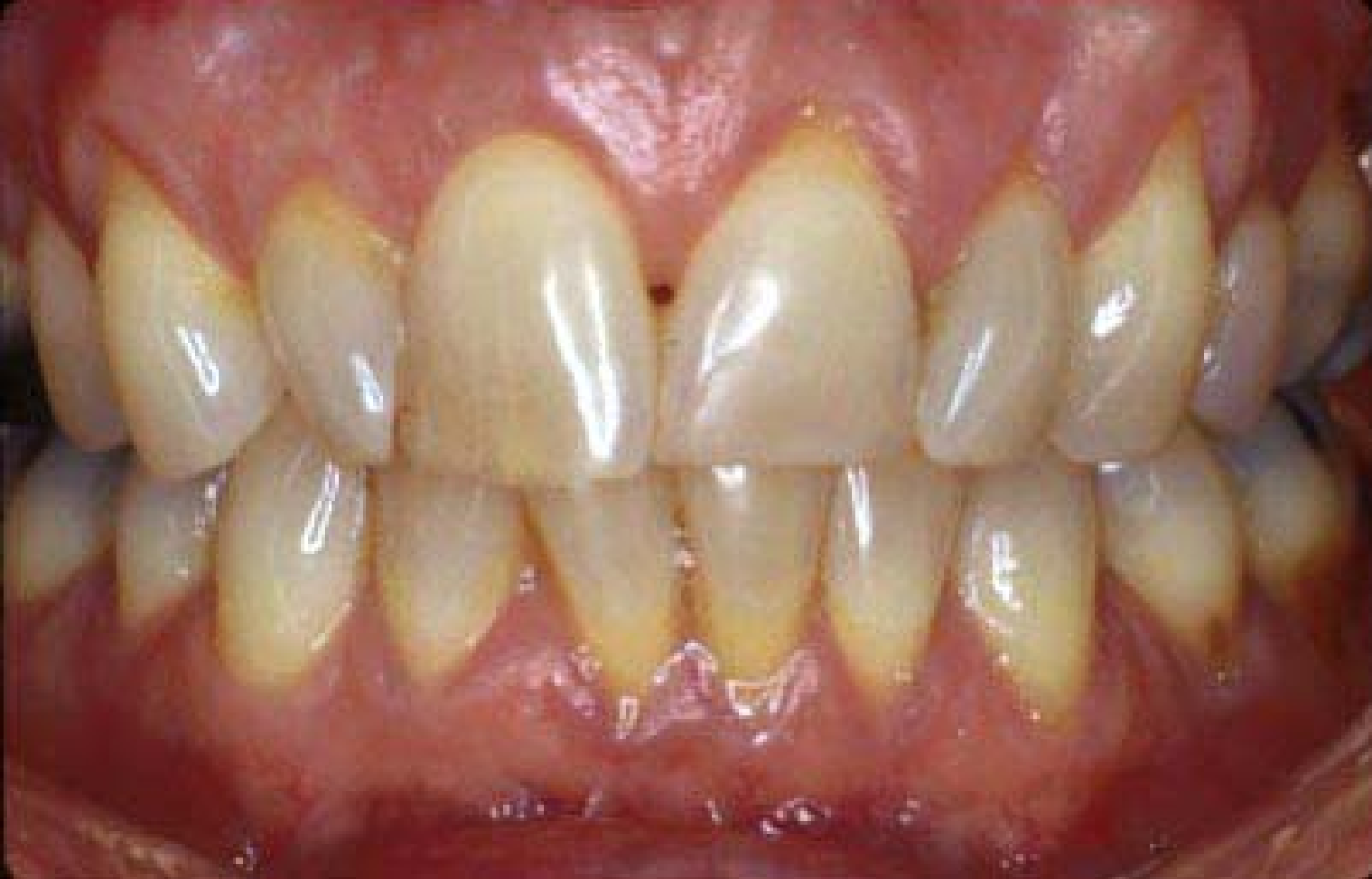

B53

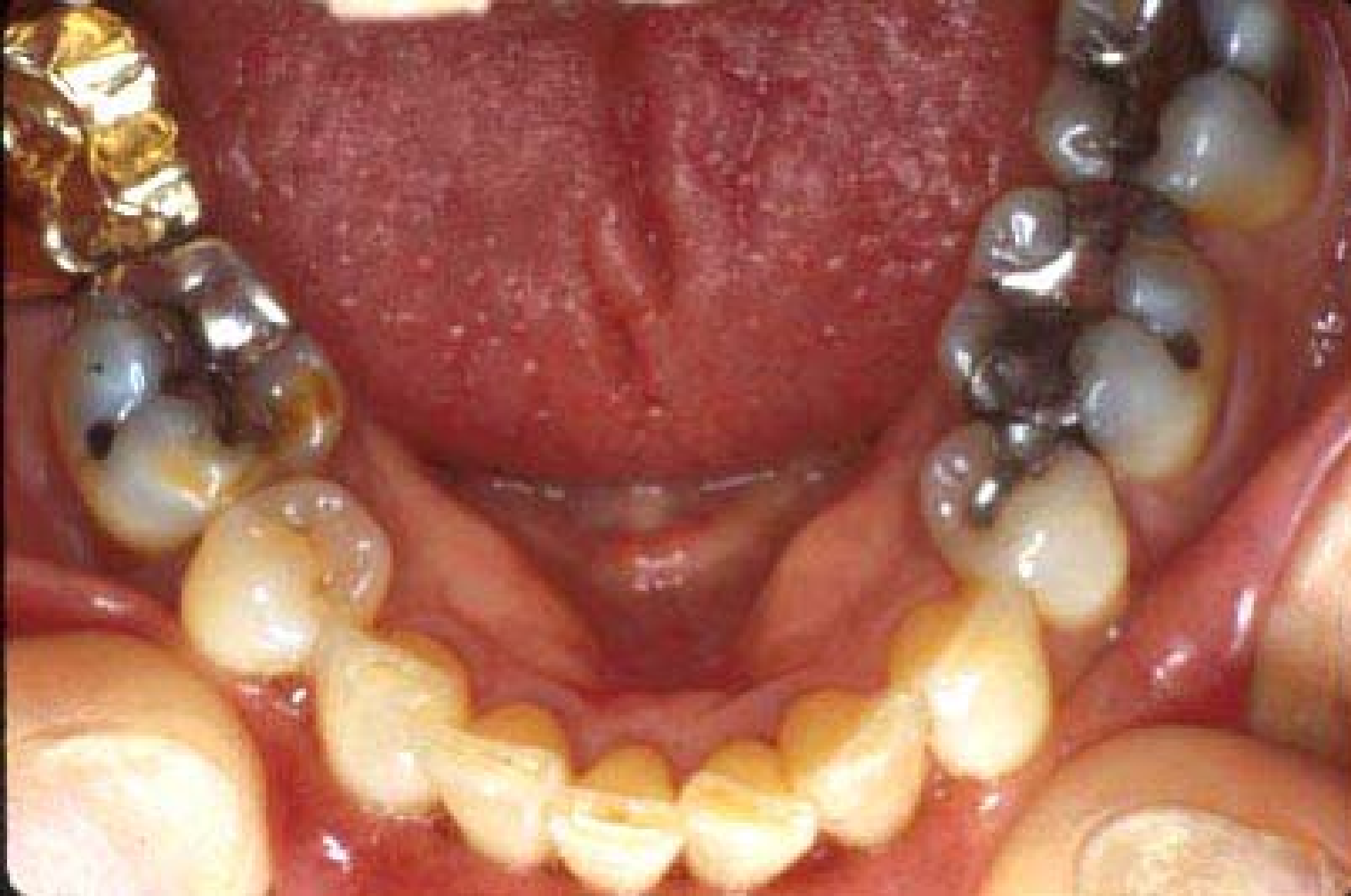**End of case.**



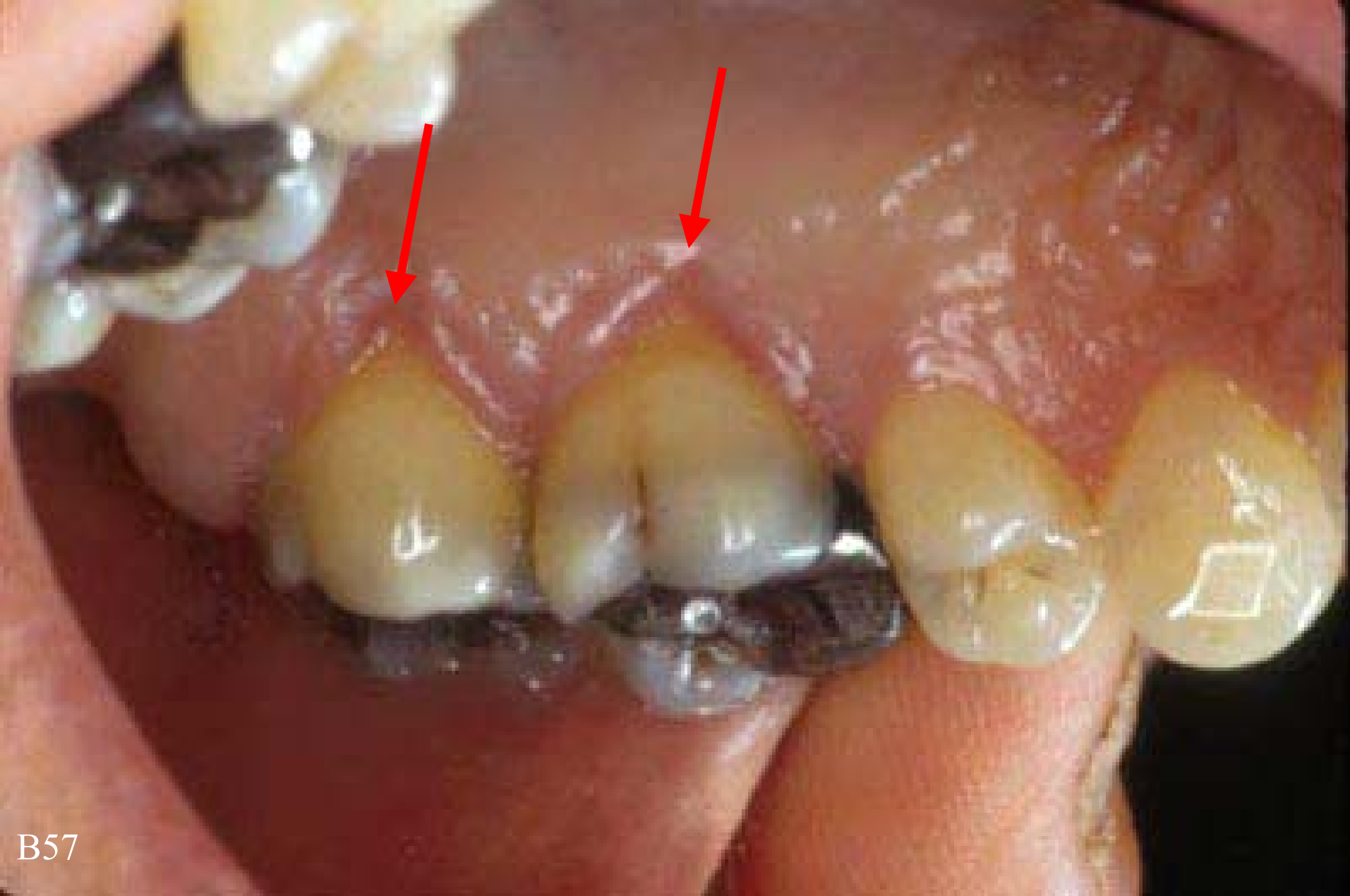Maxillary left abfractions.



Anterior view. Maxillary teeth leaning lingually. See next 2 slides.

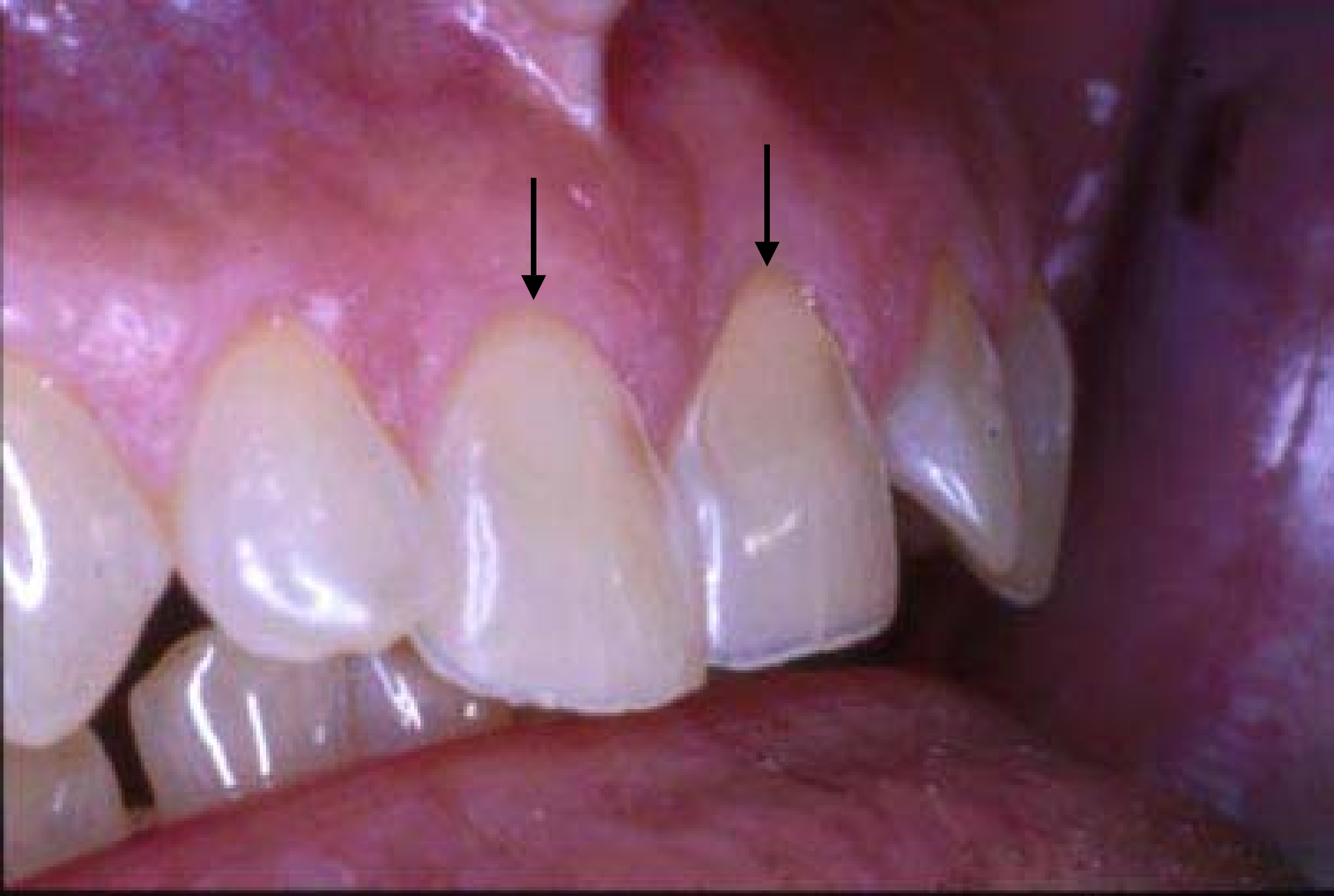

B56 Mandibular lingual tori + 4 bi ortho. See next slide.



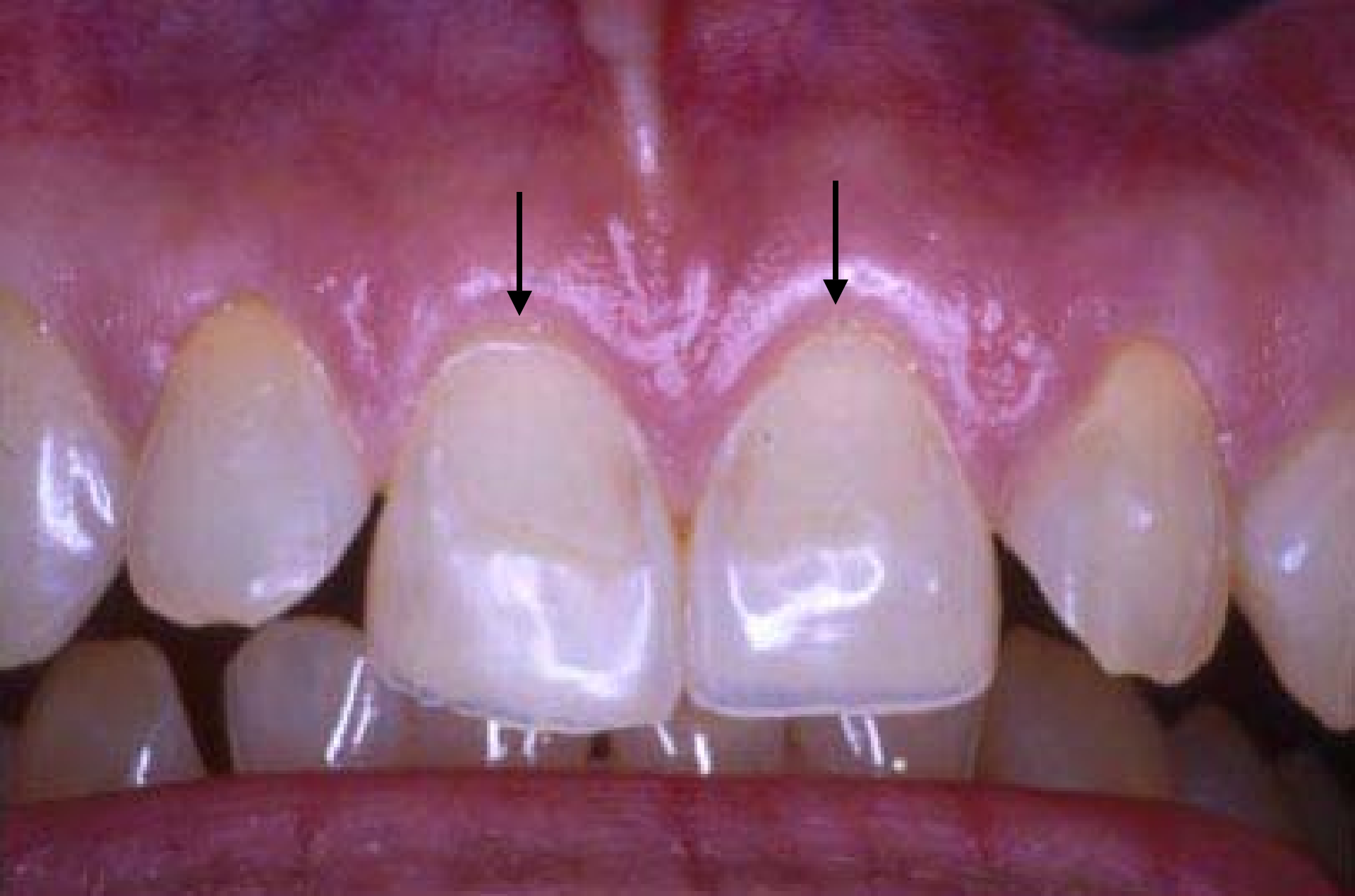B57

Lingual recession / clefts / pre-abfractions. End of case.

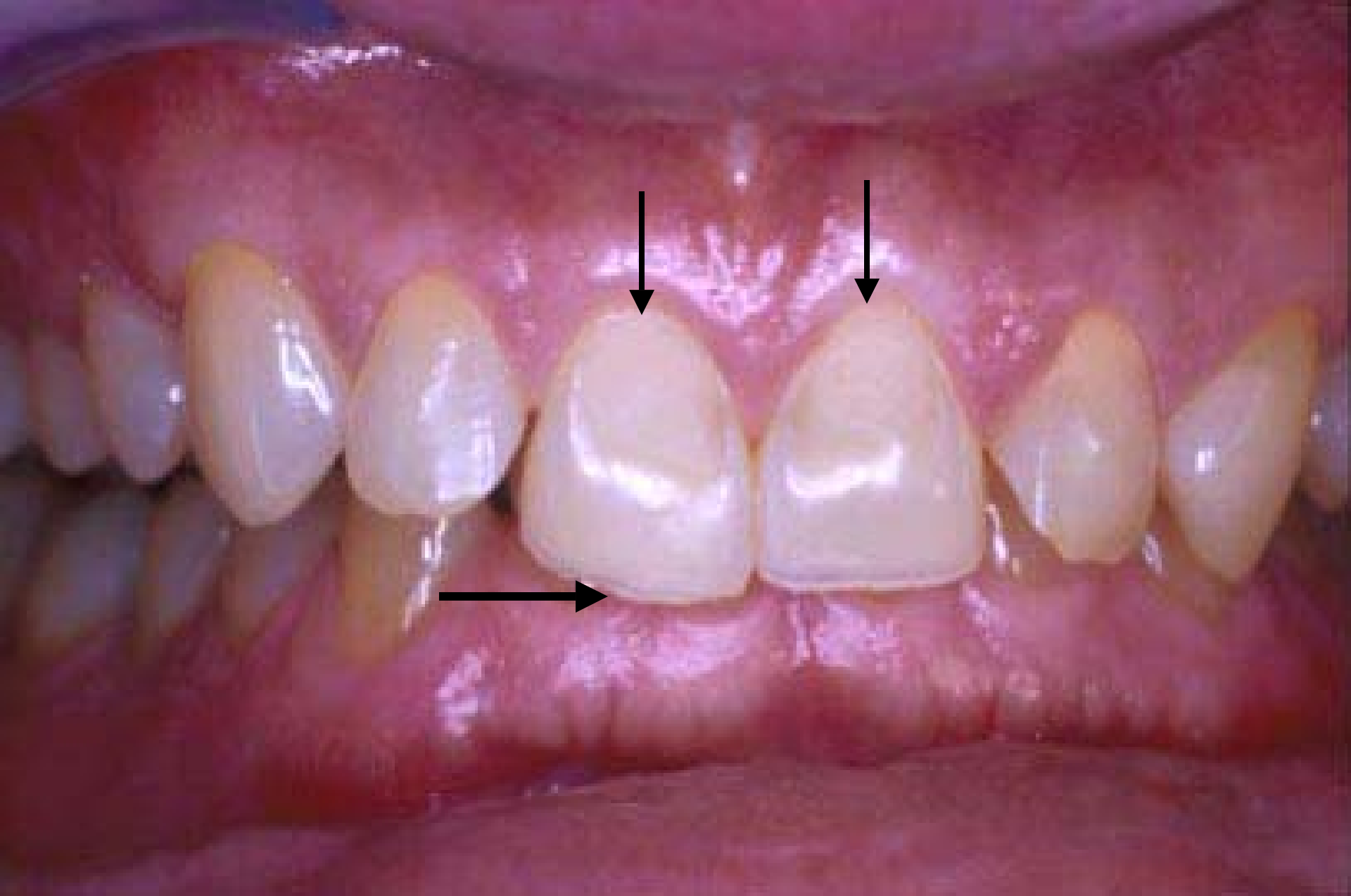


B58

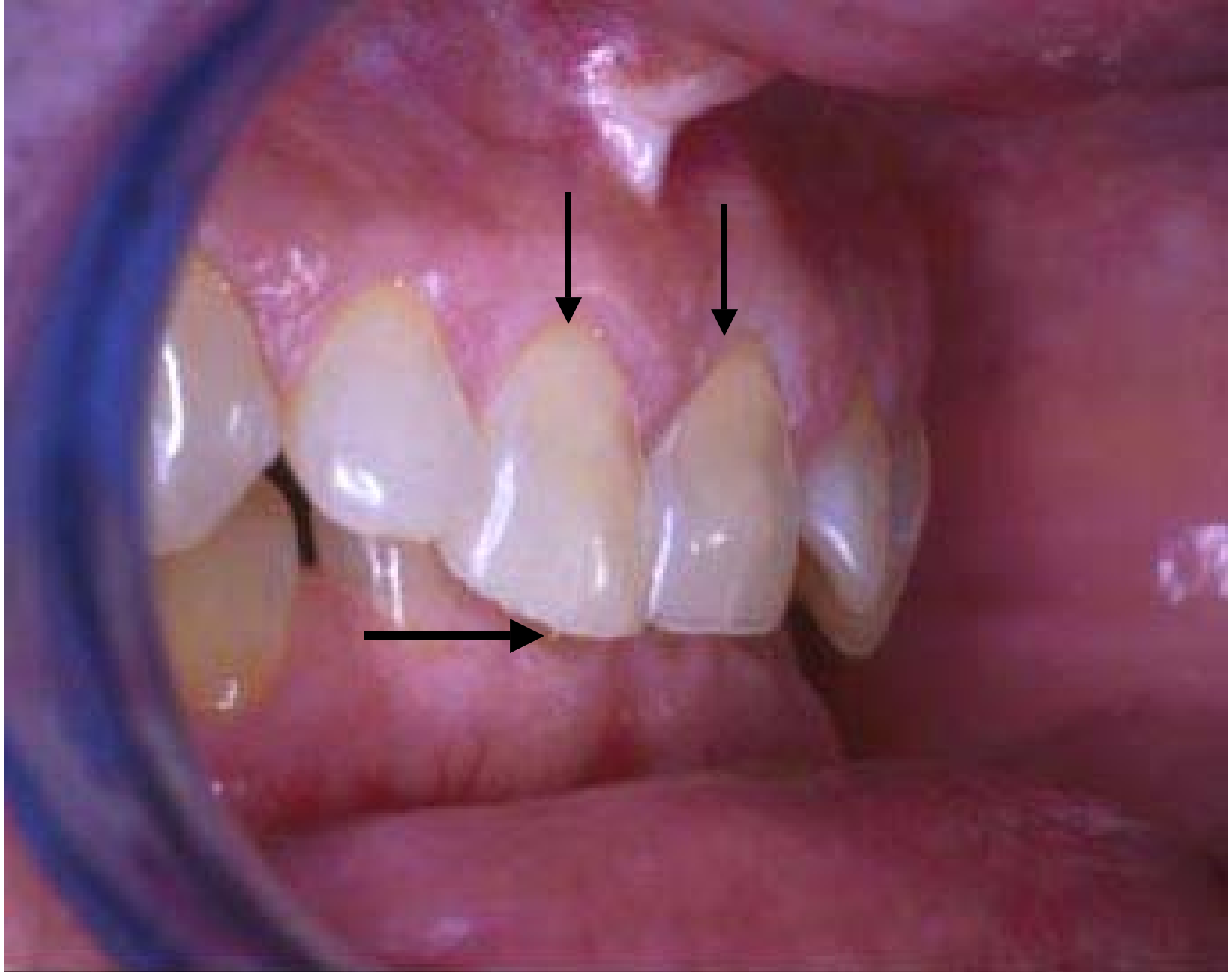
Abfractions on centrals. See next 3 slides.



B59 Abfractions on centrals. See next 2 slides.

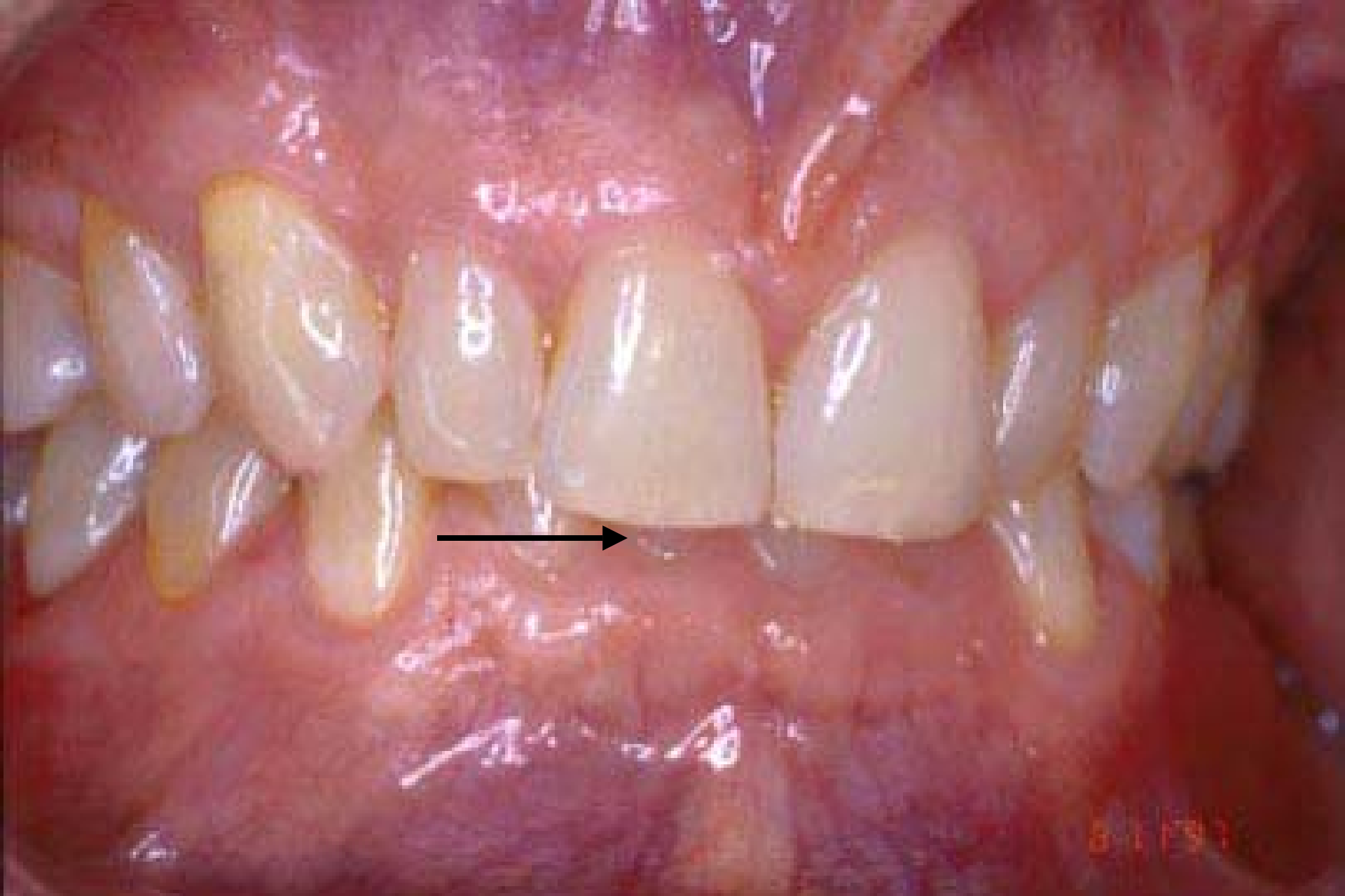

B60 100% overbite malocclusion. See next slide.

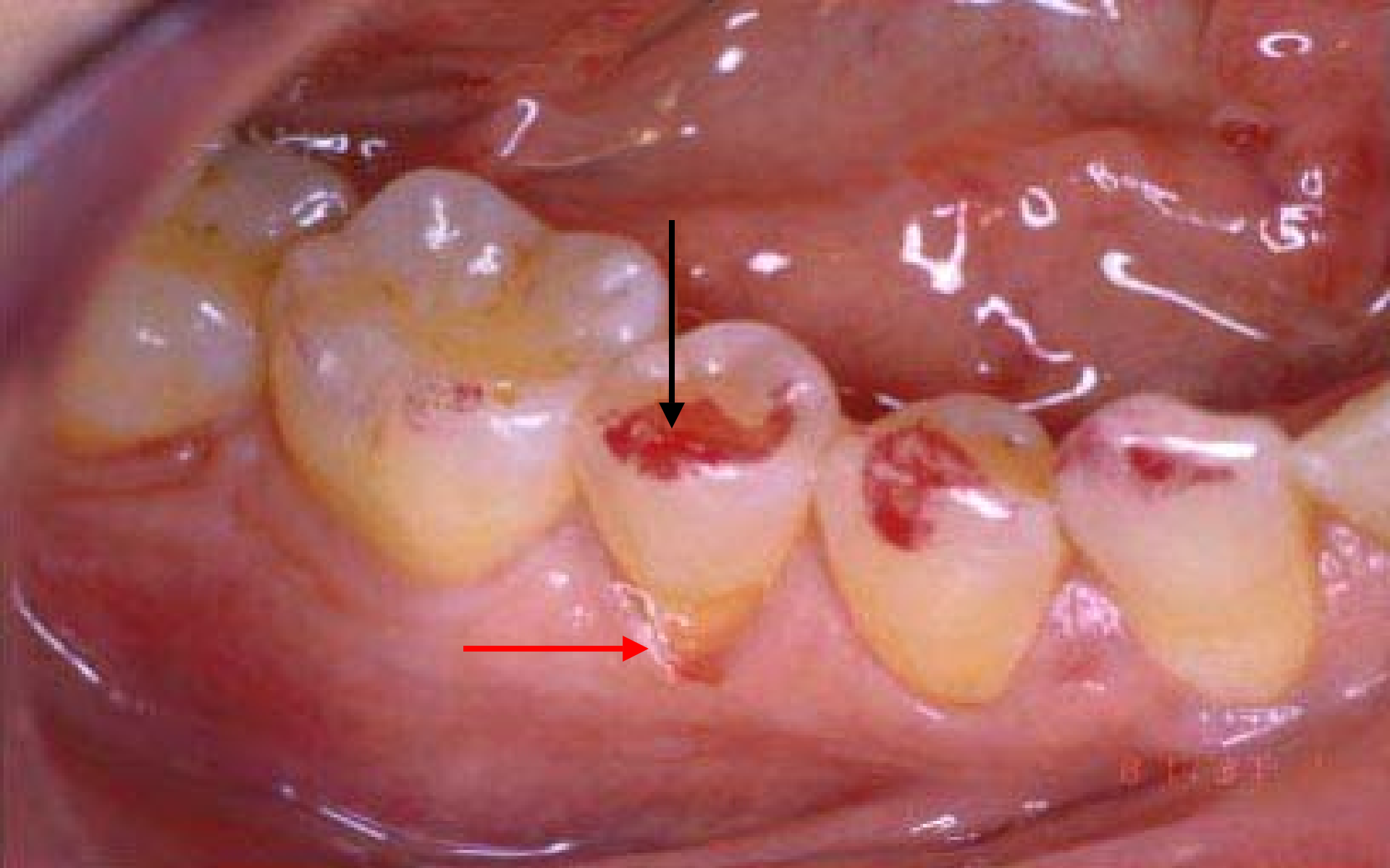


B61

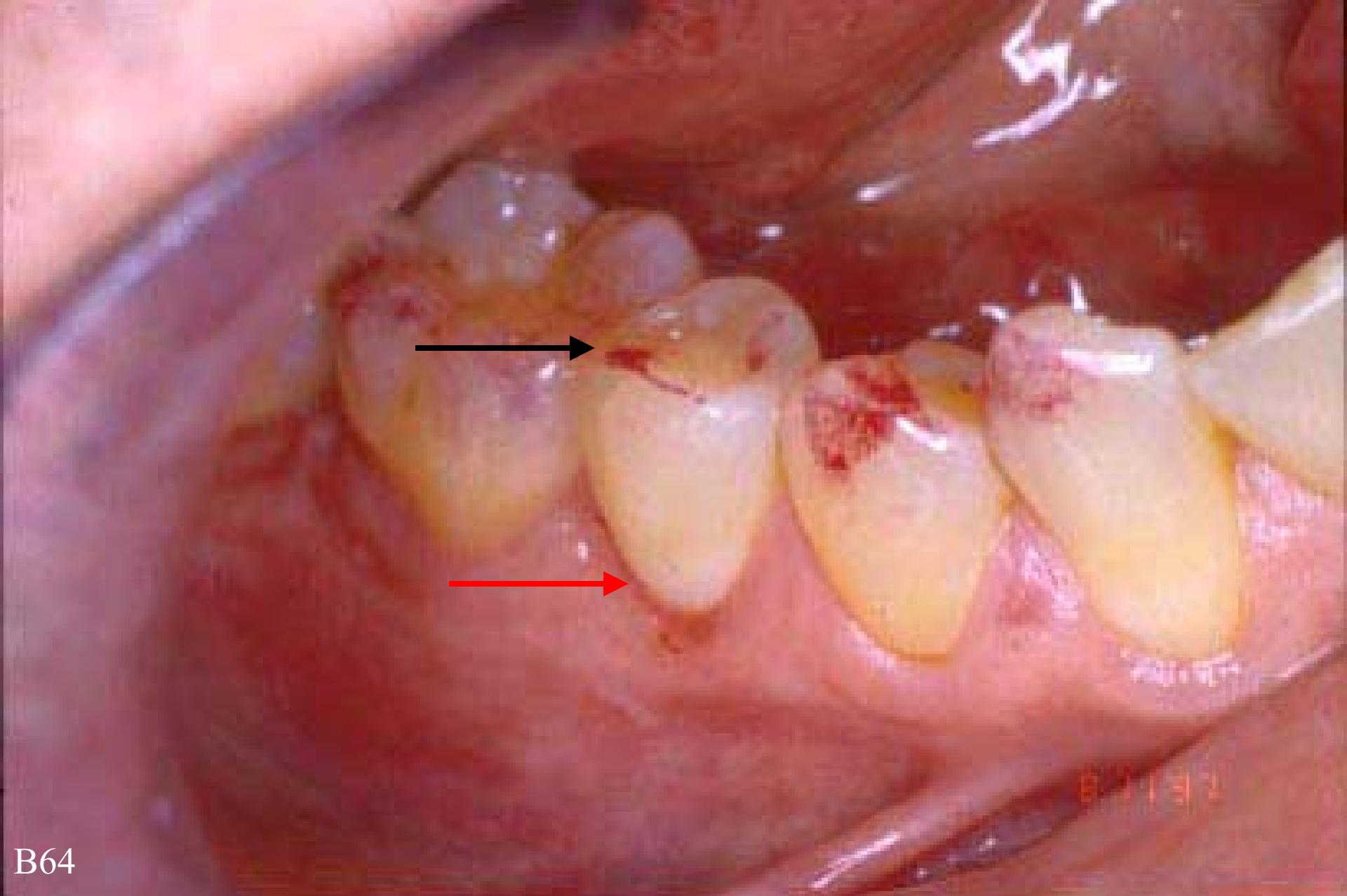
100% overbite malocclusion. End of case.



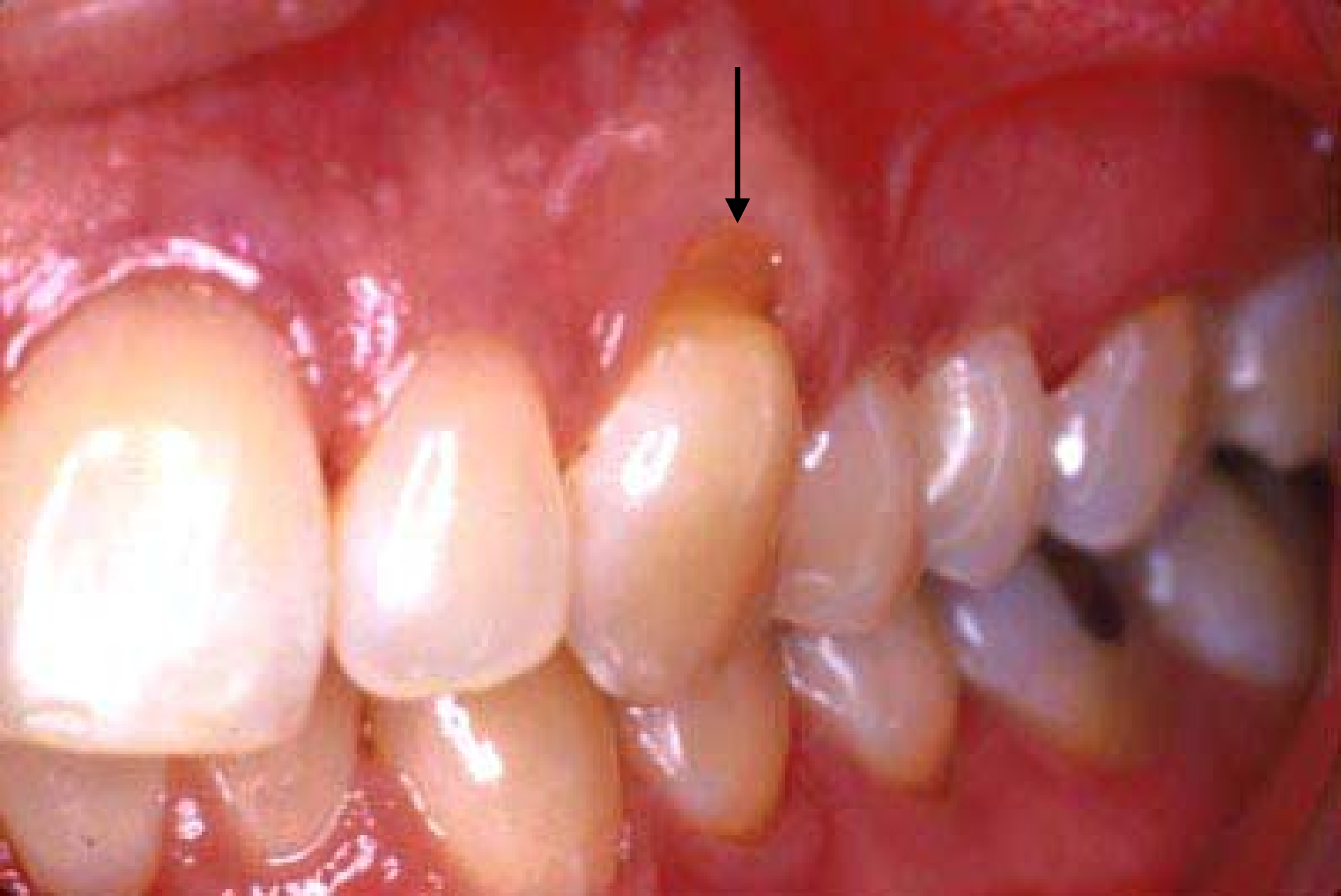Overbite malocclusion. See next 2 slides.



Abfraction #29. Heavy markings indicate occlusal trauma. See next slide.

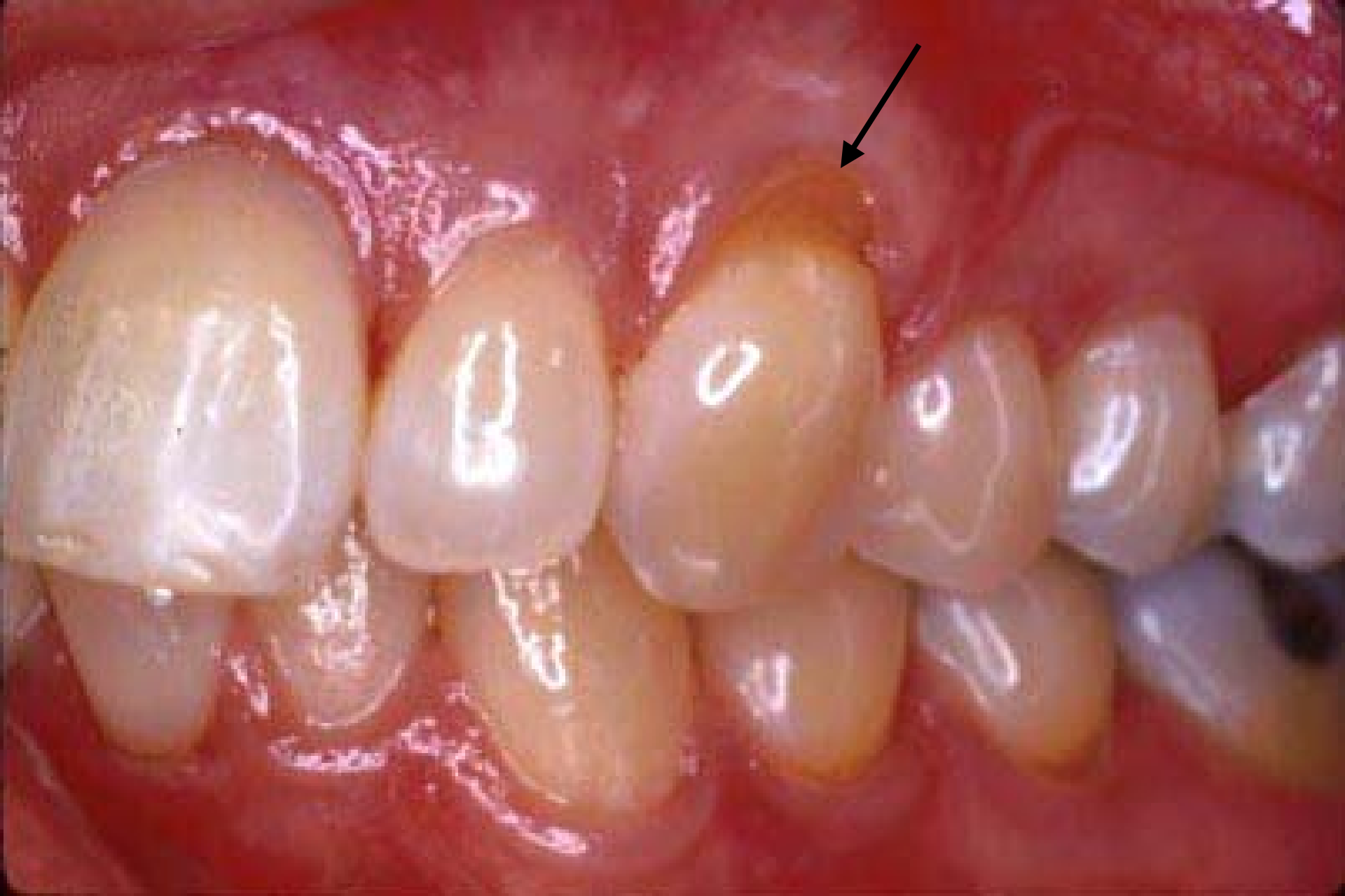

B64  
Bicuspid (#29) restored and equilibrated. End of case.



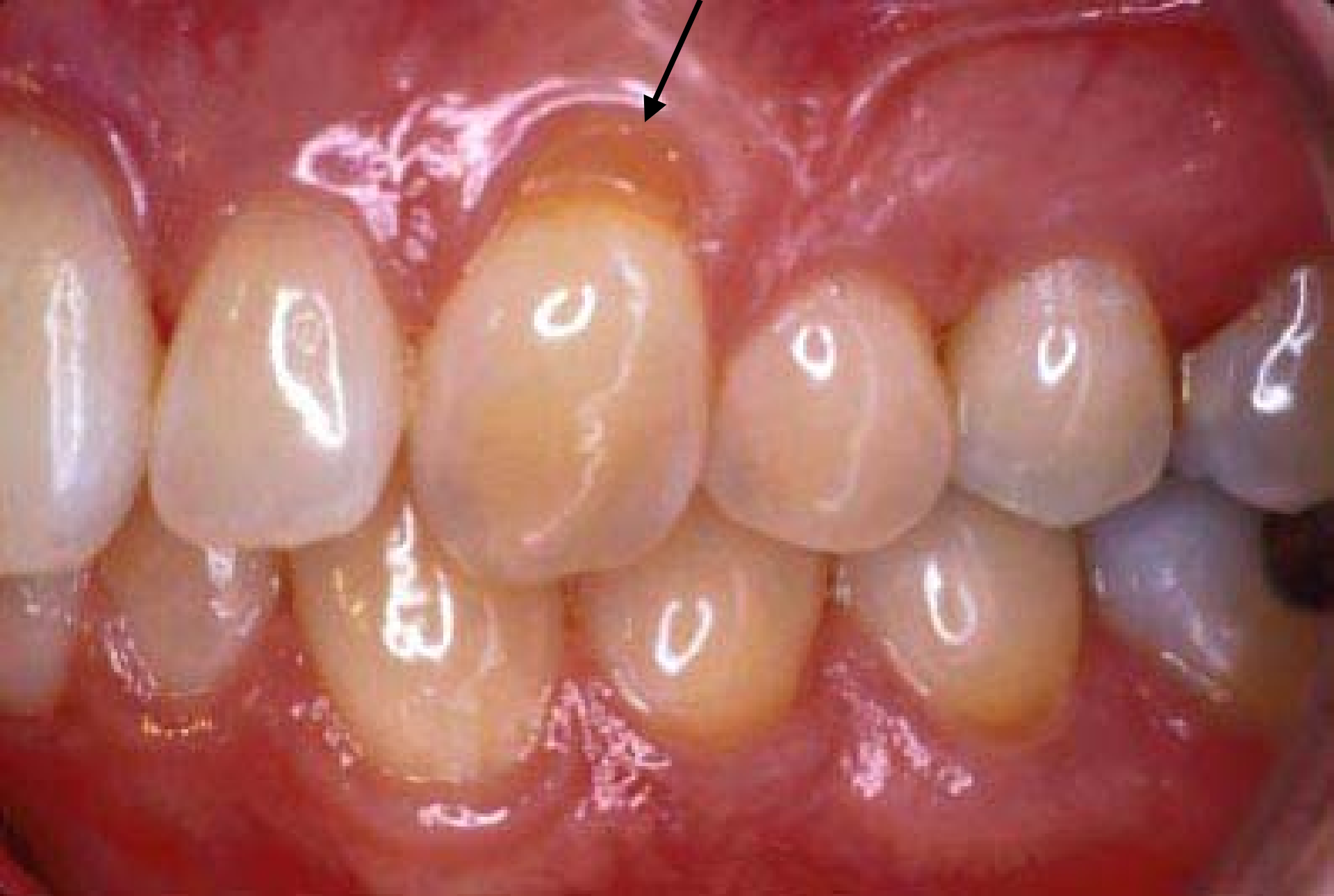B65

Single abfraction. See next 2 slides.



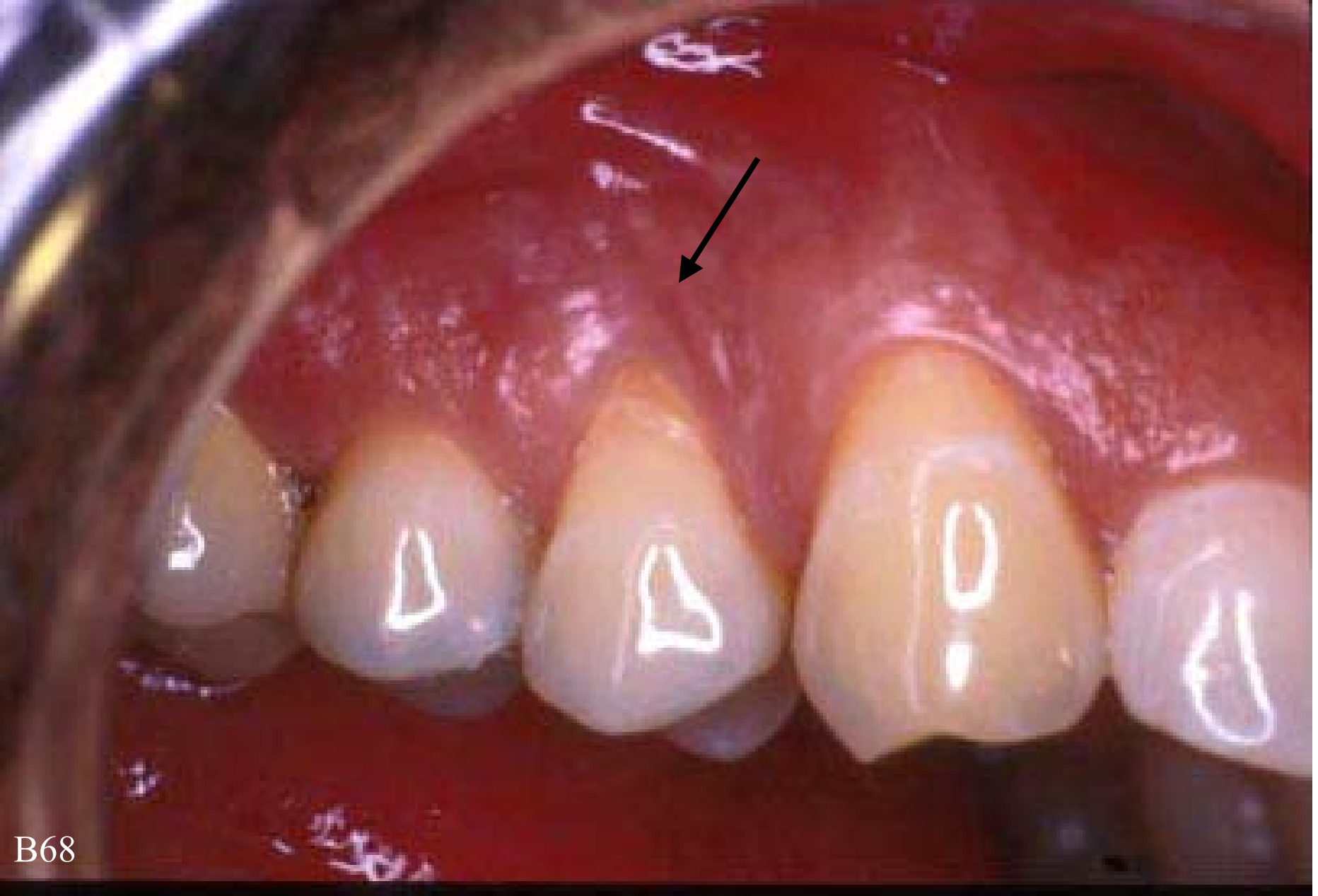
B66

Mal-aligned cuspid. See next slide.

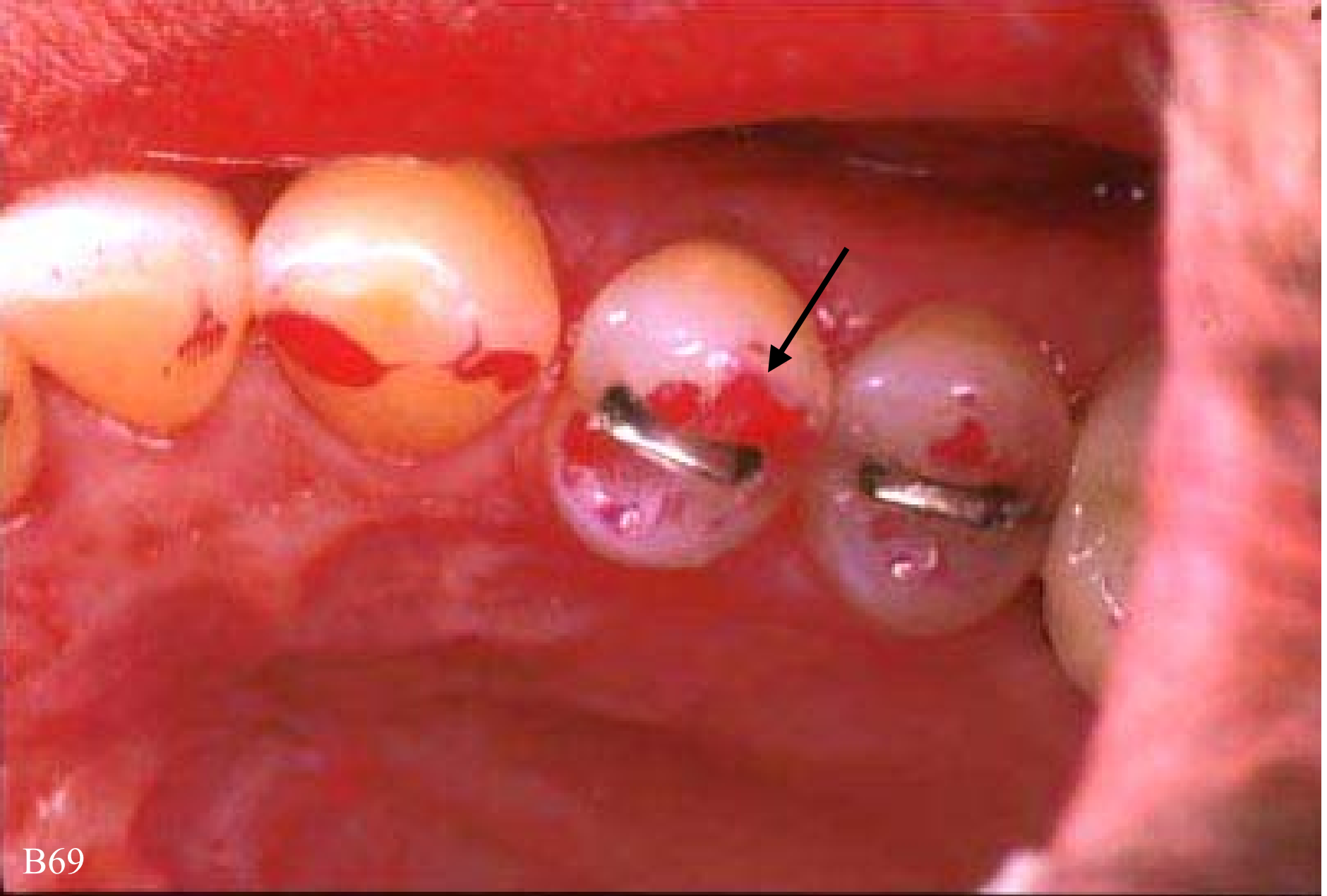


B67

Cuspid too upright (straight). End of case.

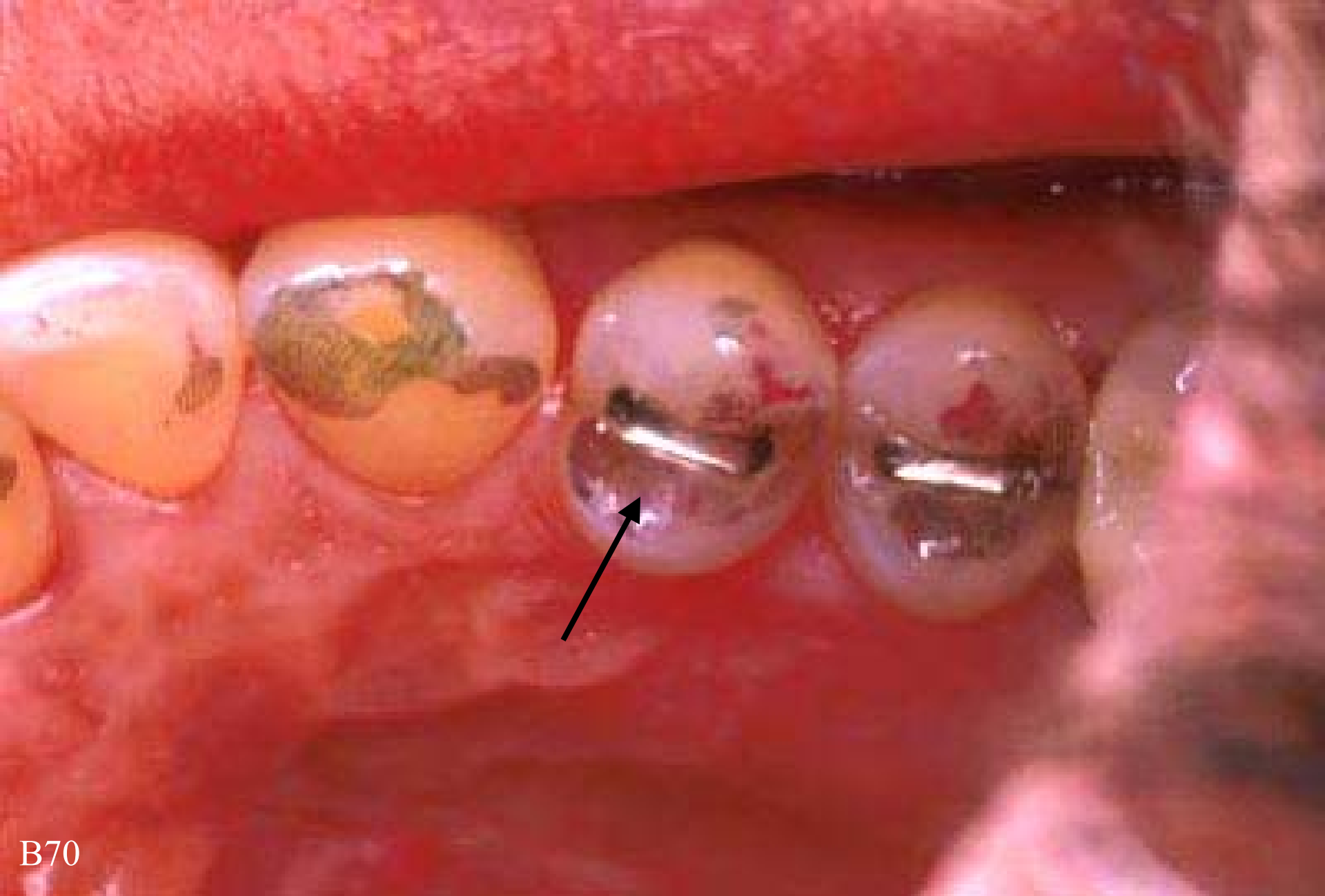

Cleft on 1st bicuspid. A pre-abfraction. See next 3 slides.



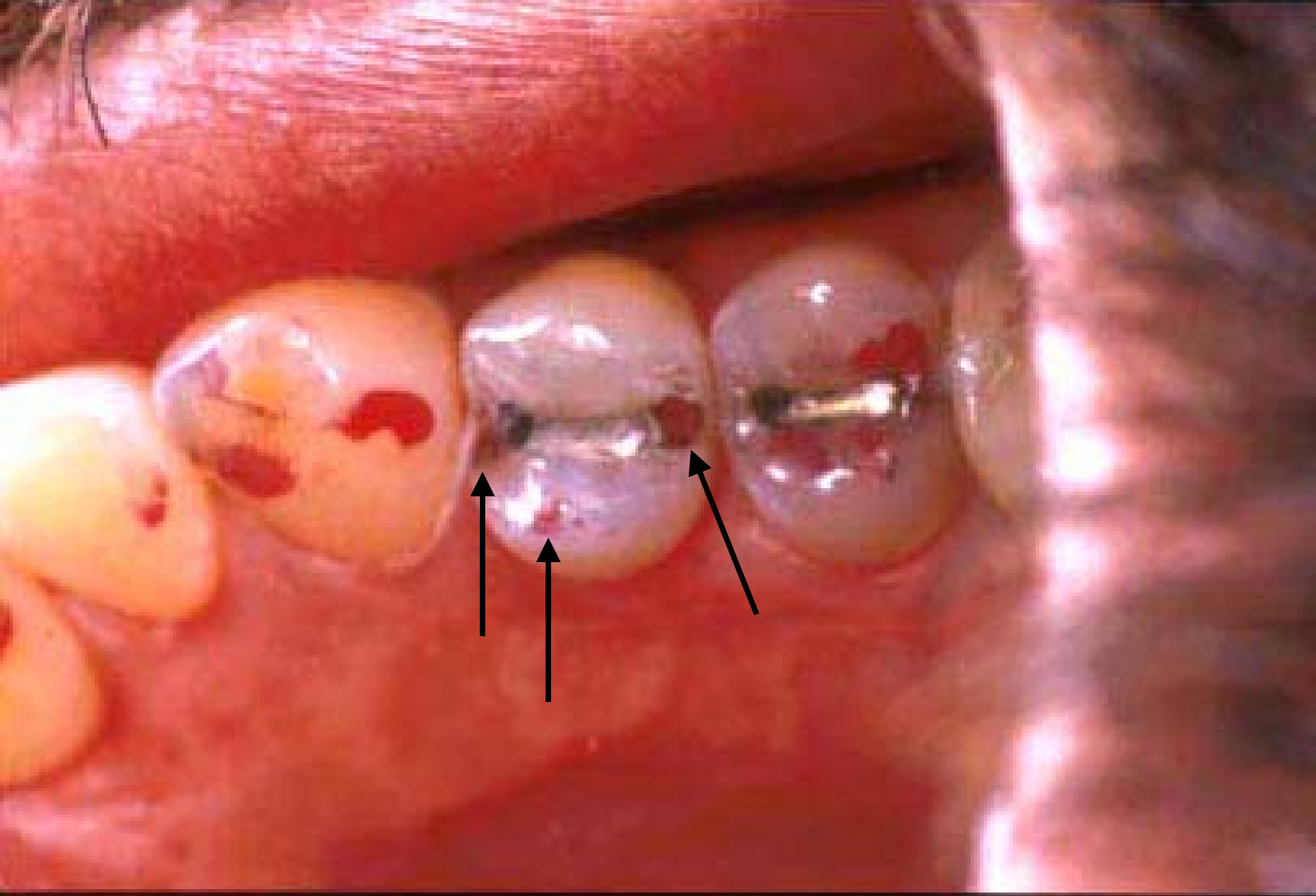
B69

Heavy occlusal markings on 1st bicuspid. See next 2 slides.



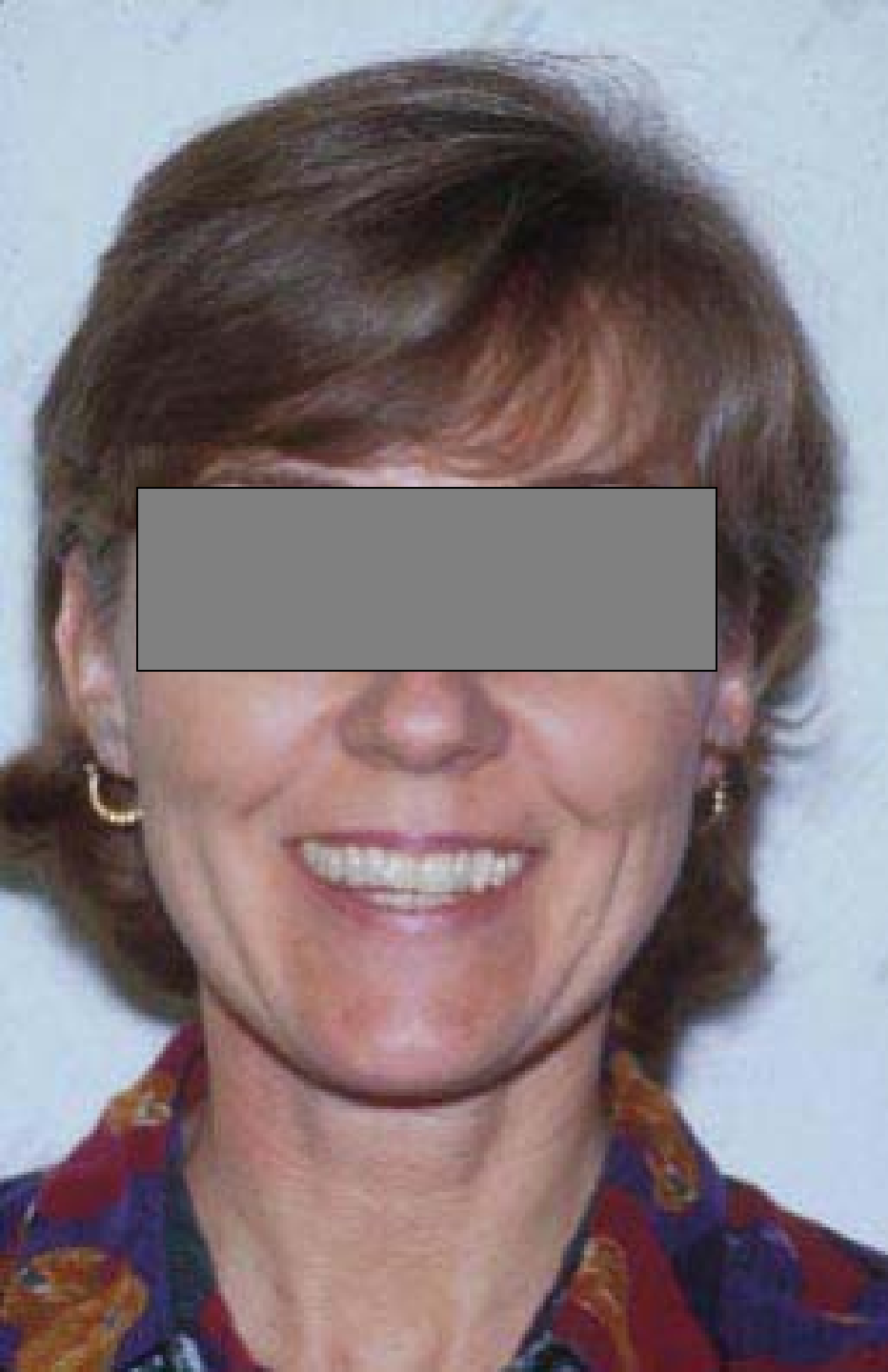B70

Heavy excursive green markings. See next slide.

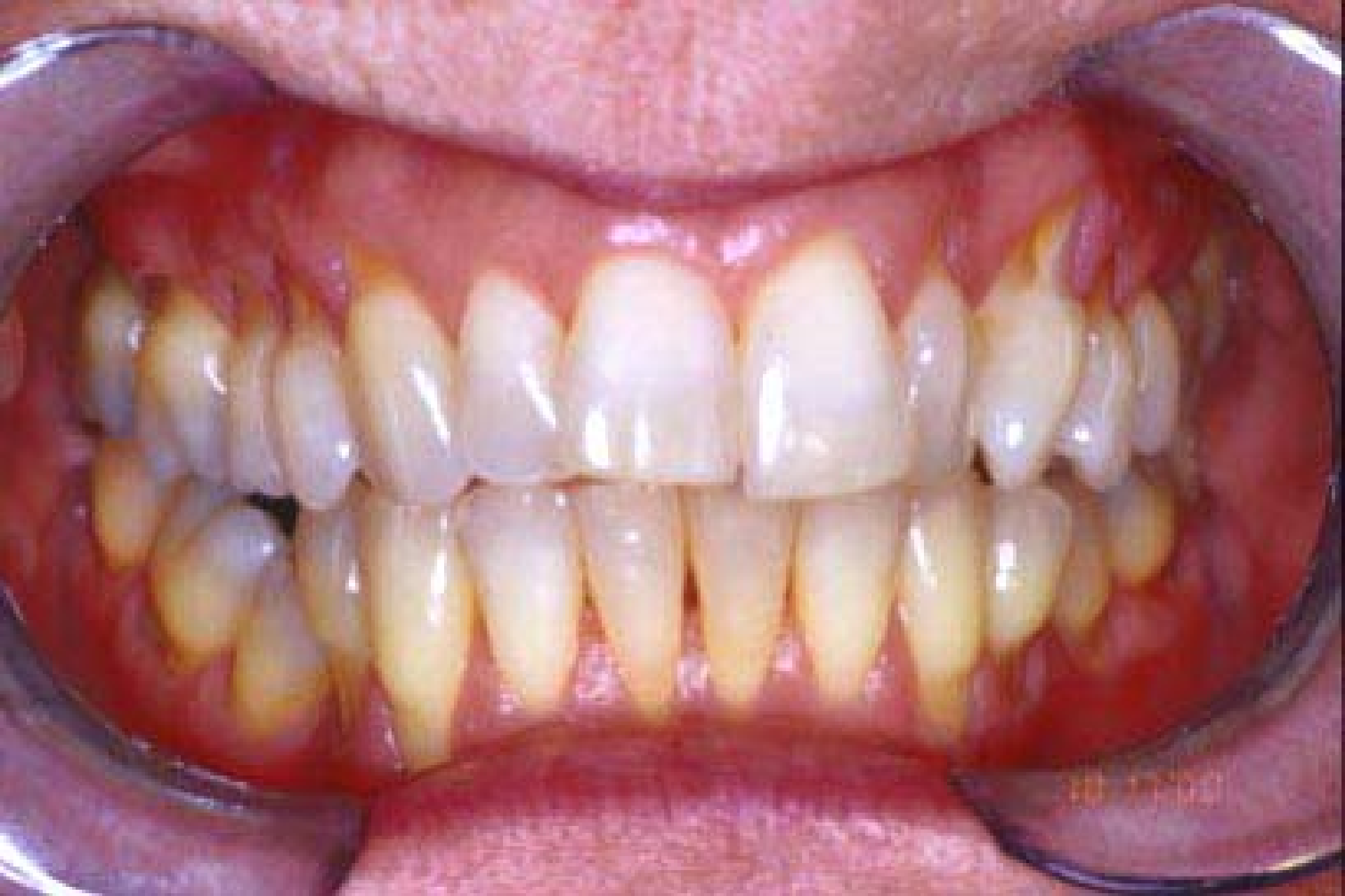

B71 Markings refined on 1st bicuspid. End of case.

In the following case of 20 slides, ankyloglossia (tight lingual frenum) caused a tongue thrust. The tongue thrust was the main factor for the development of the malocclusion and multiple abfractions in this adult female. **Most of what you see in this case could have been prevented** if the physician had just clipped the lingual frenum at birth.

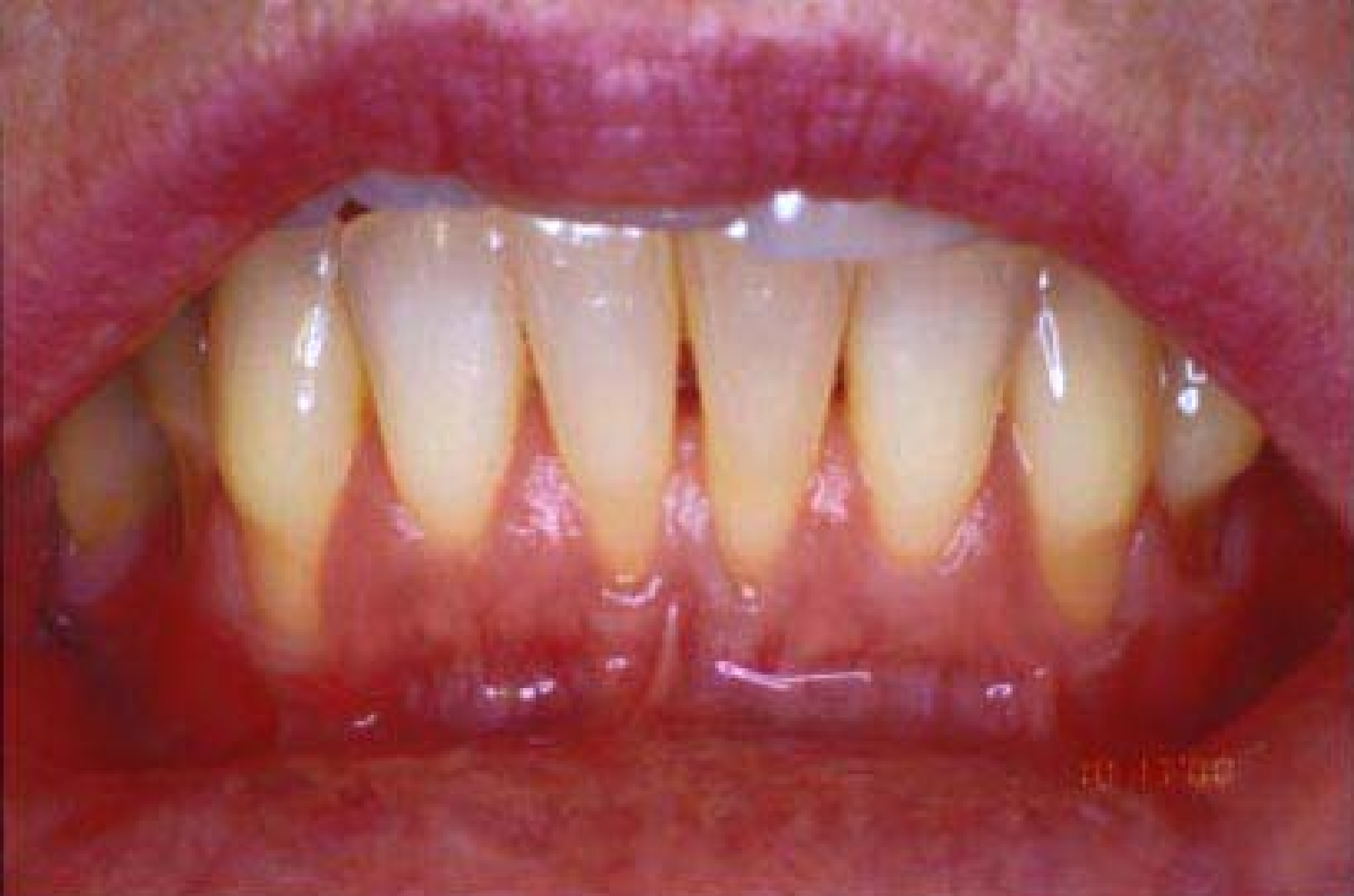

A pretty lady with  
a pretty smile.

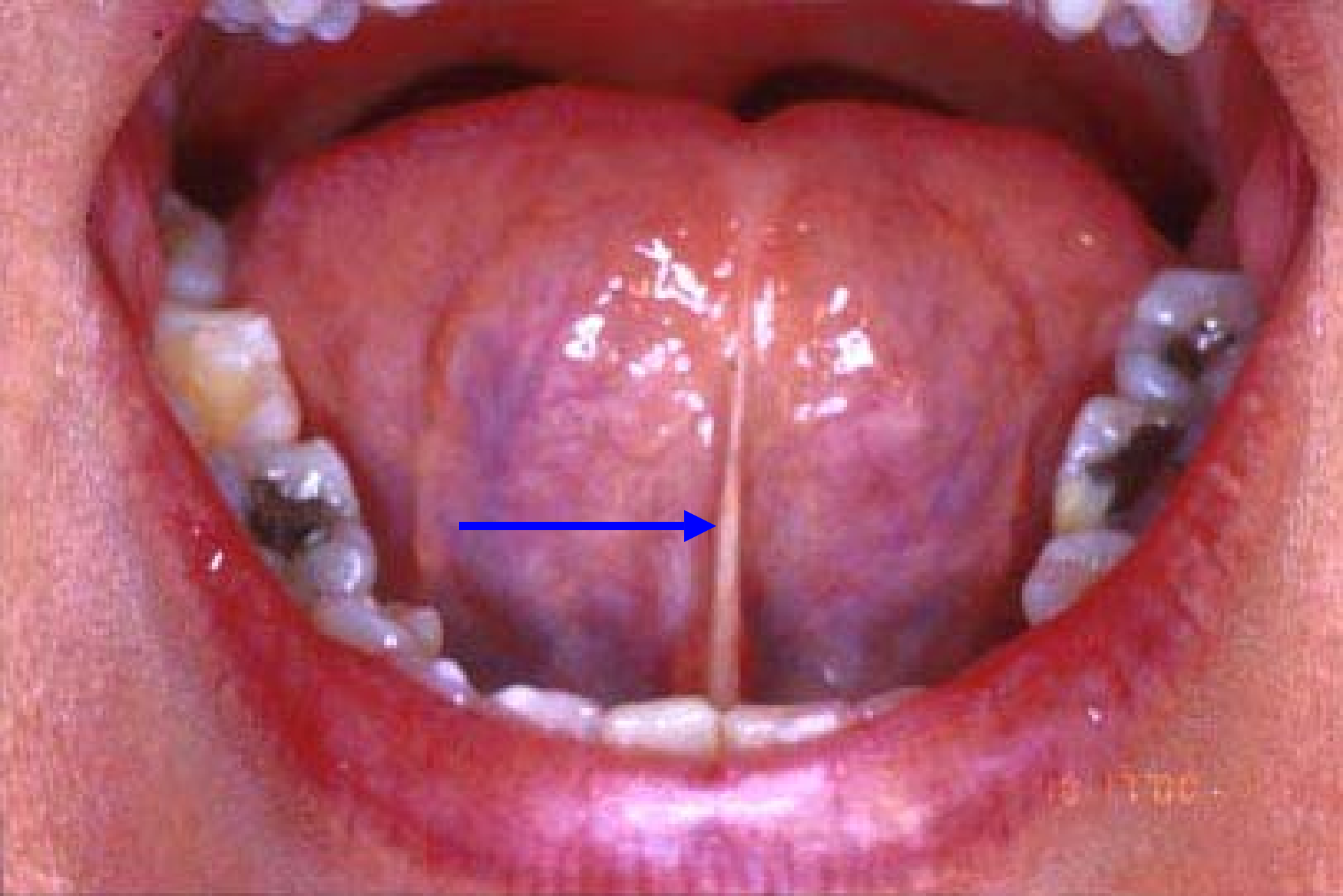


B74

Anterior view of occlusion.

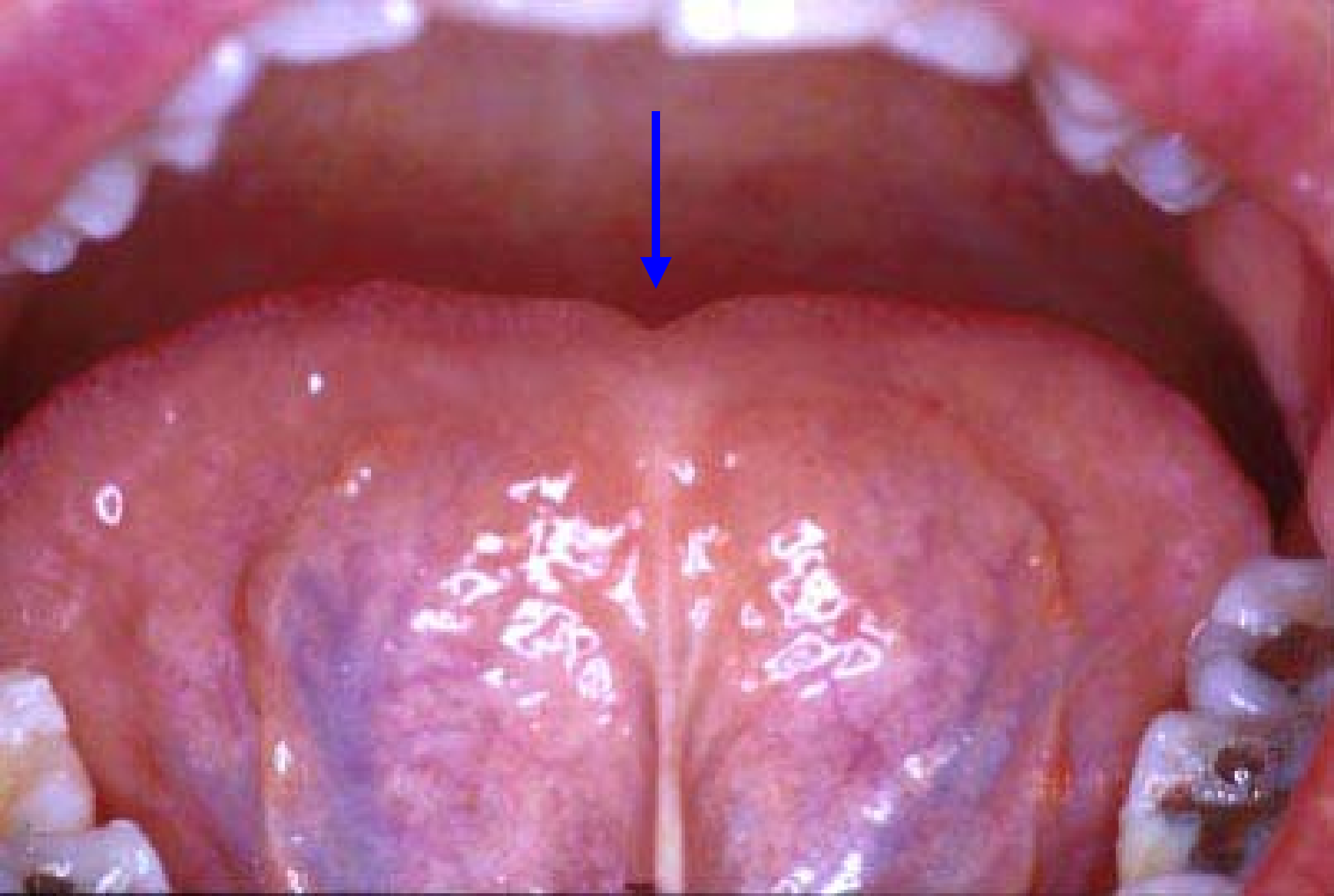


Mandibular anterior recession.



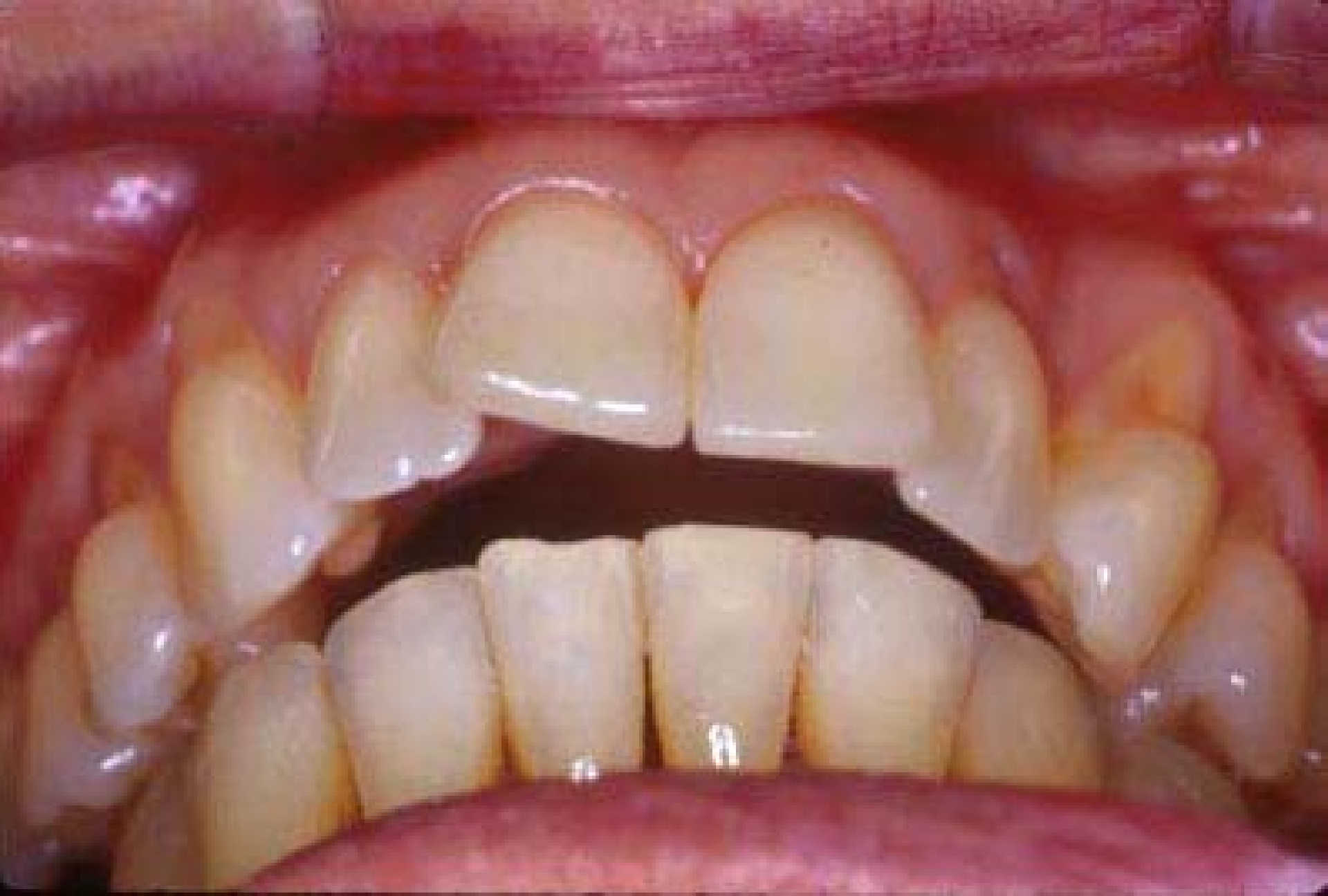B76

Ankyloglossia - tight frenum - tongue tied.



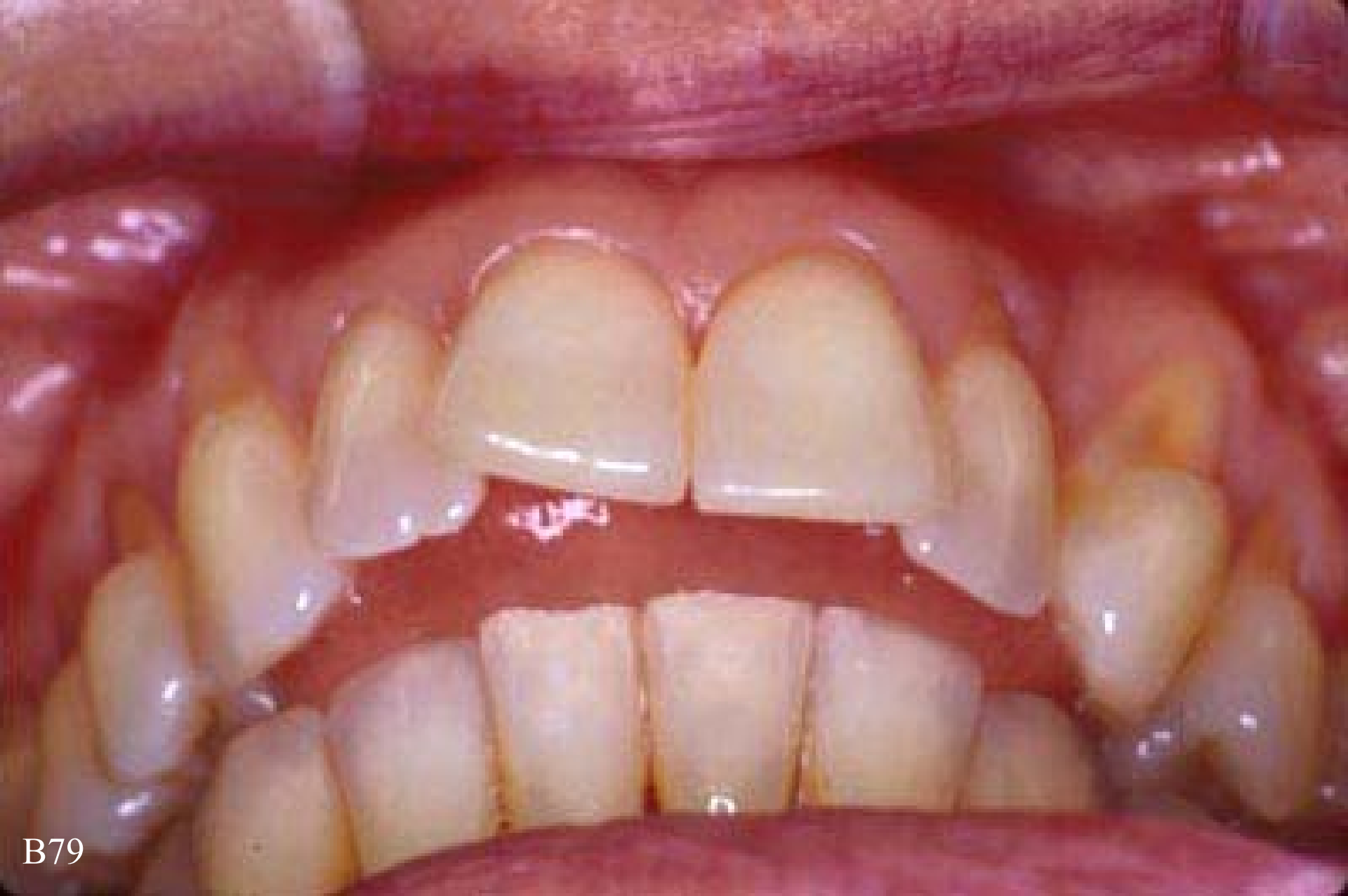B77

Note slight heart-shape of tongue.



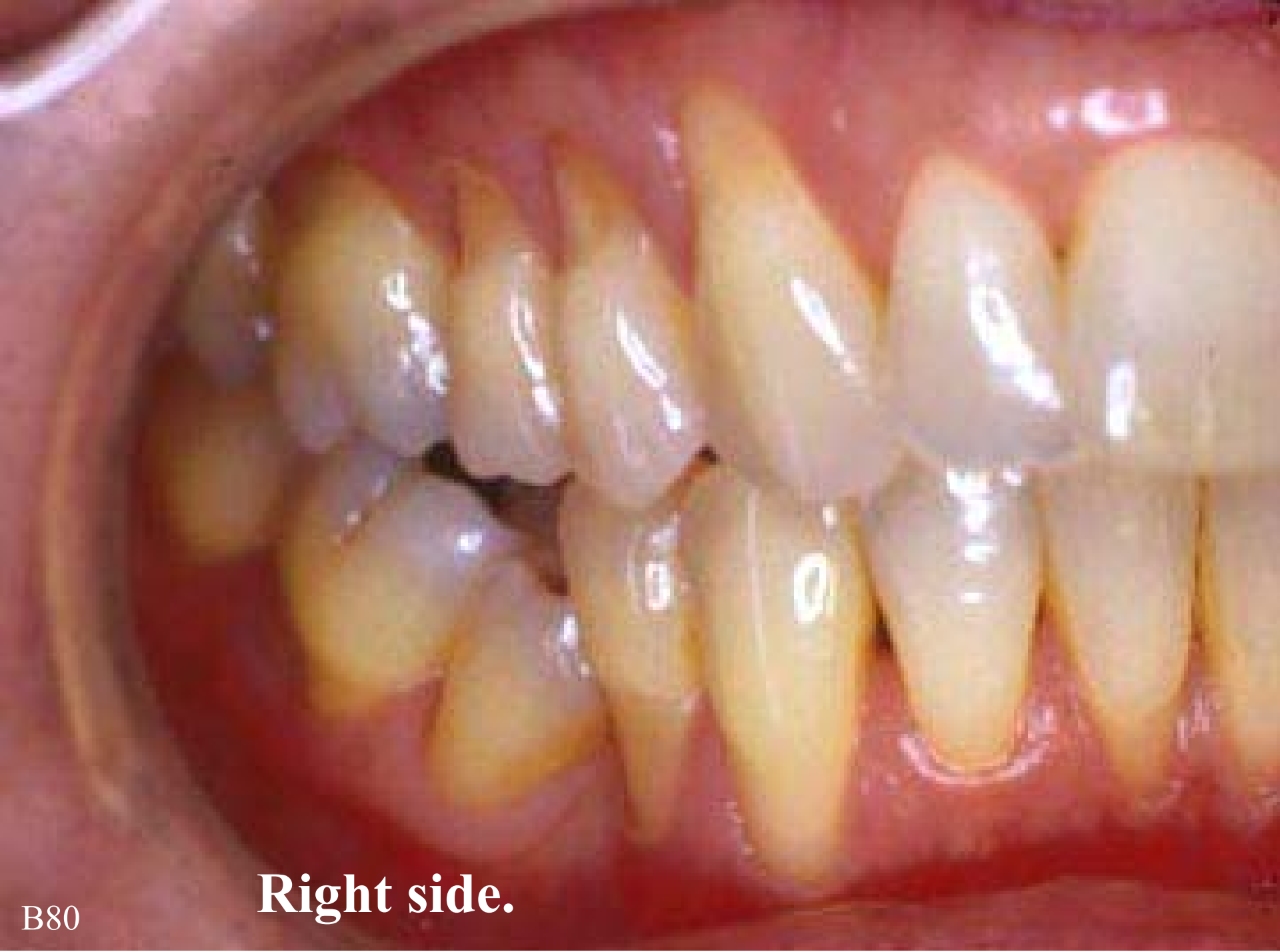
B78

Anterior open bite malocclusion.



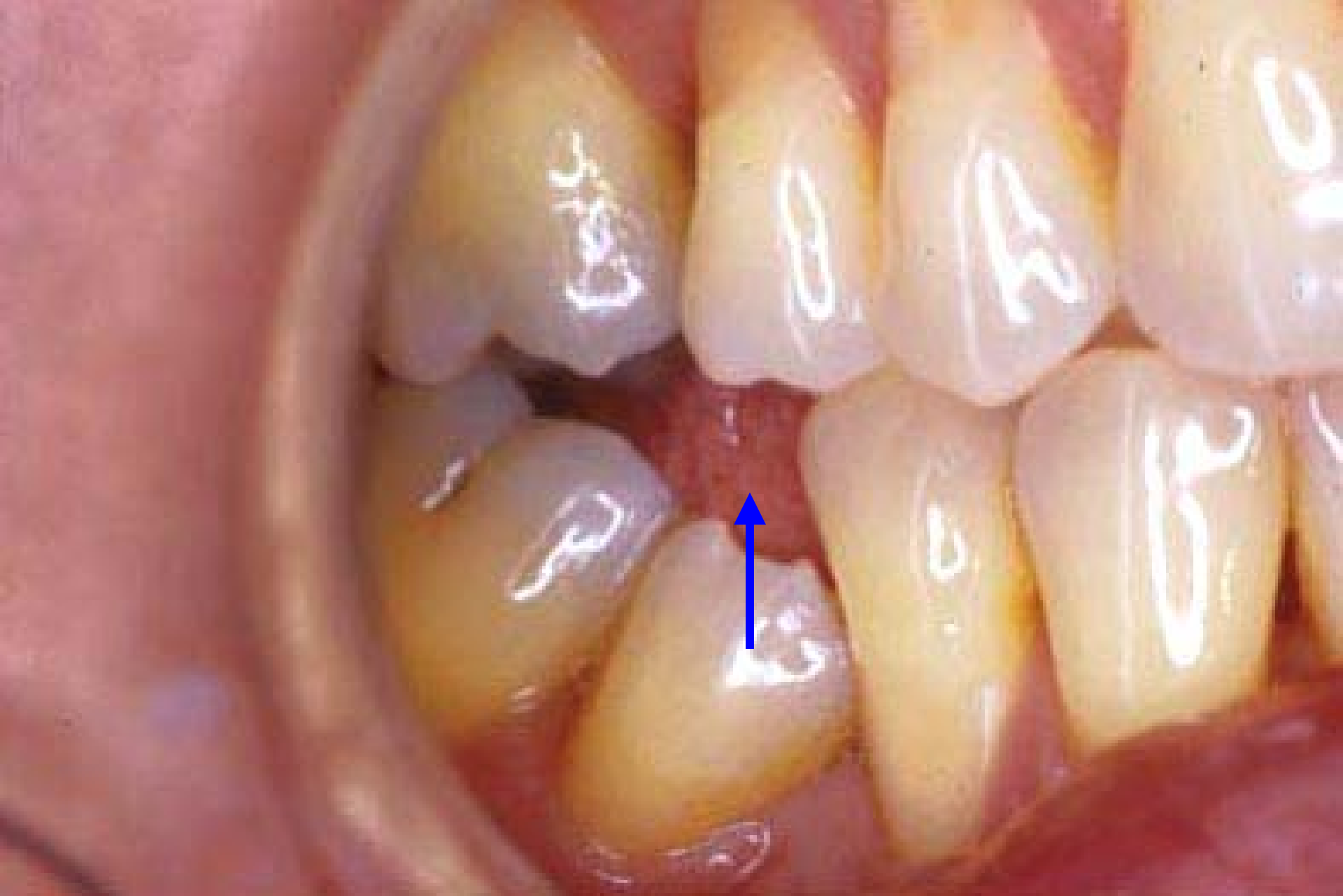B79

This tongue thrust created this open-bite malocclusion.

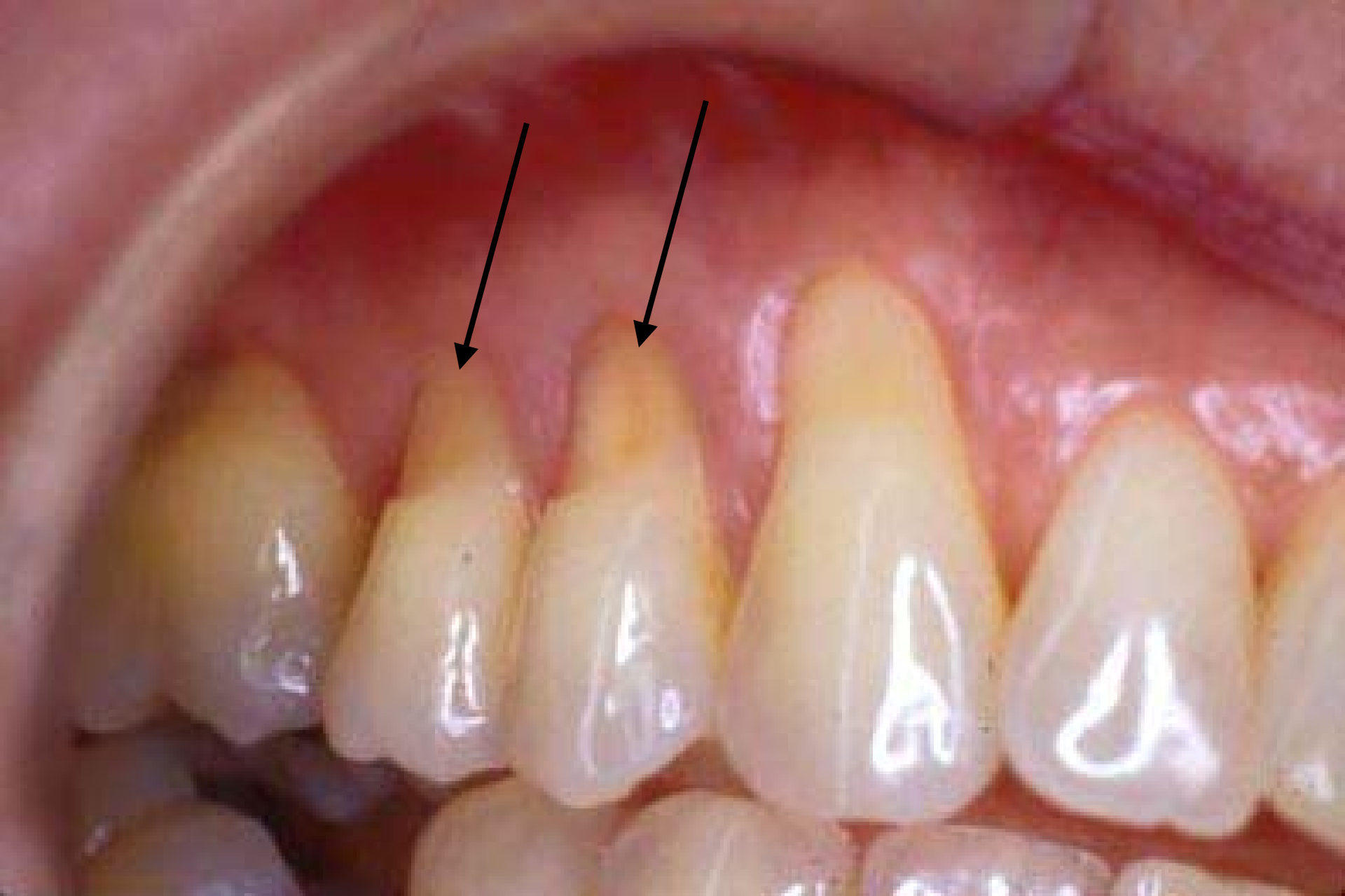


**Right side.**

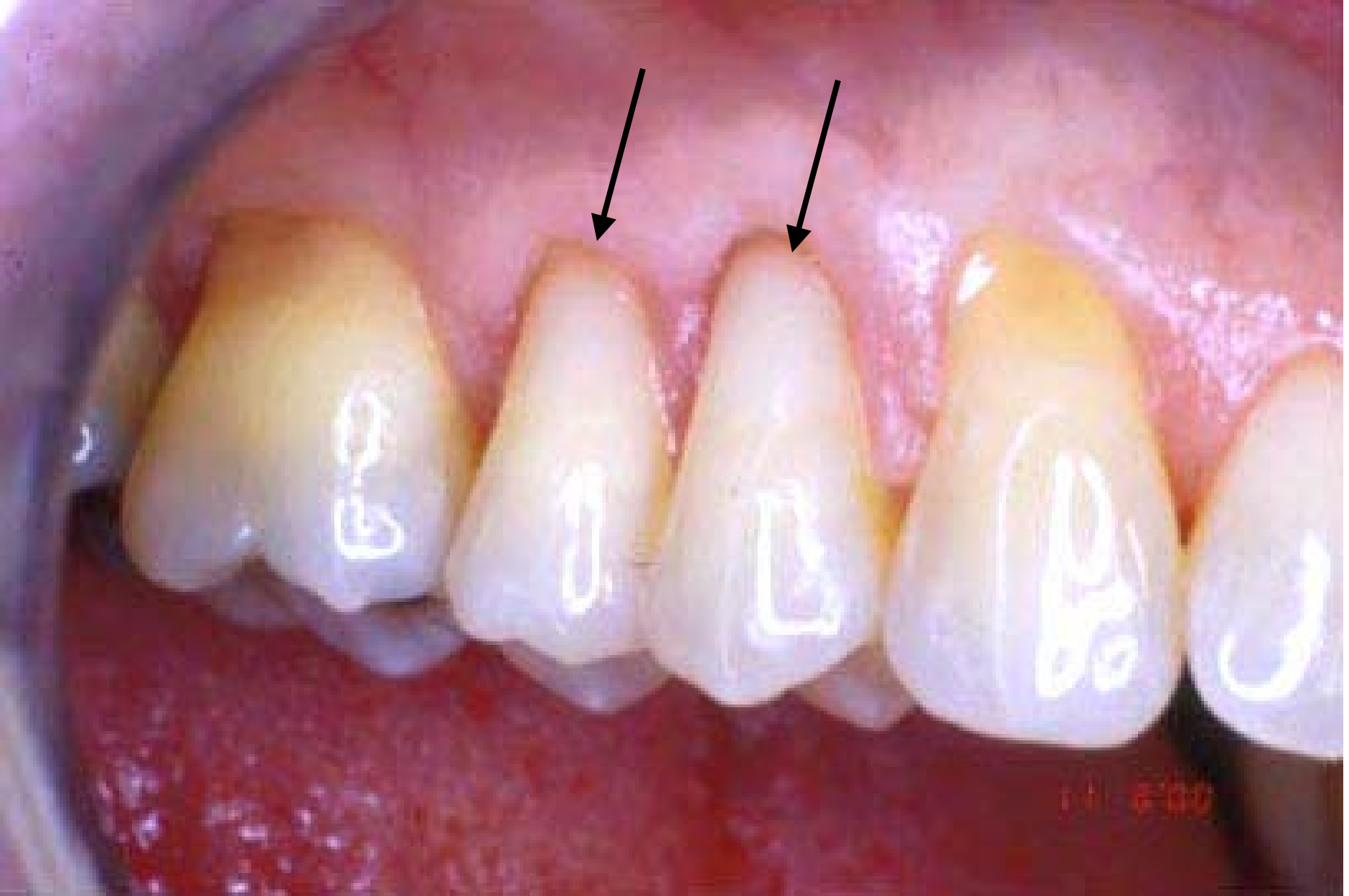B80



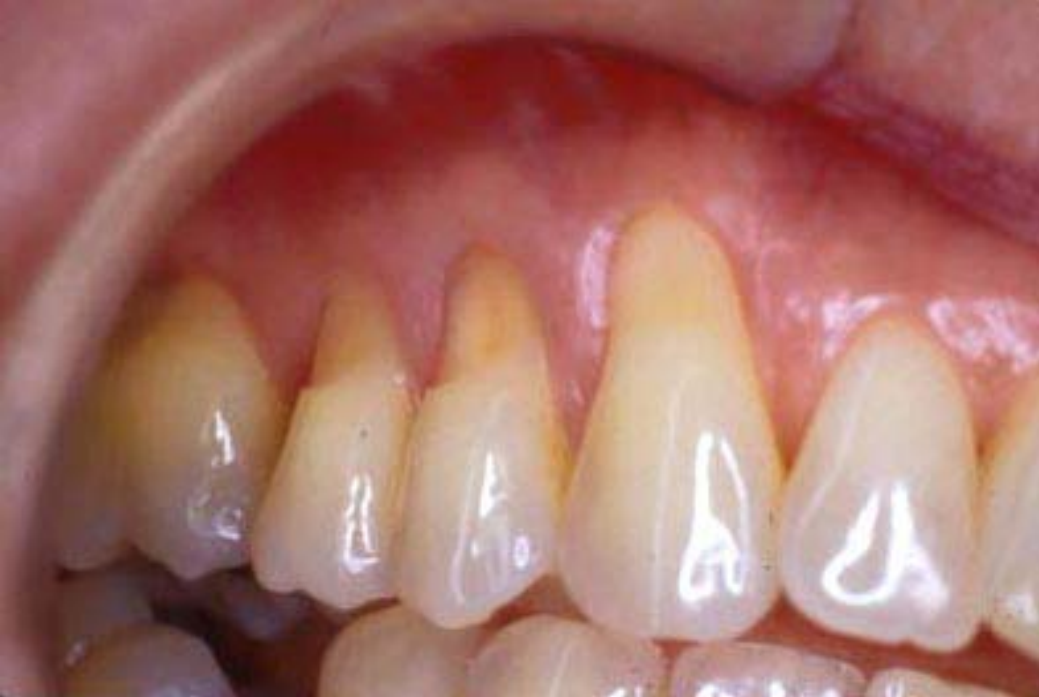Note tongue thrust between teeth (blue arrow).



Abfractions maxillary right side.

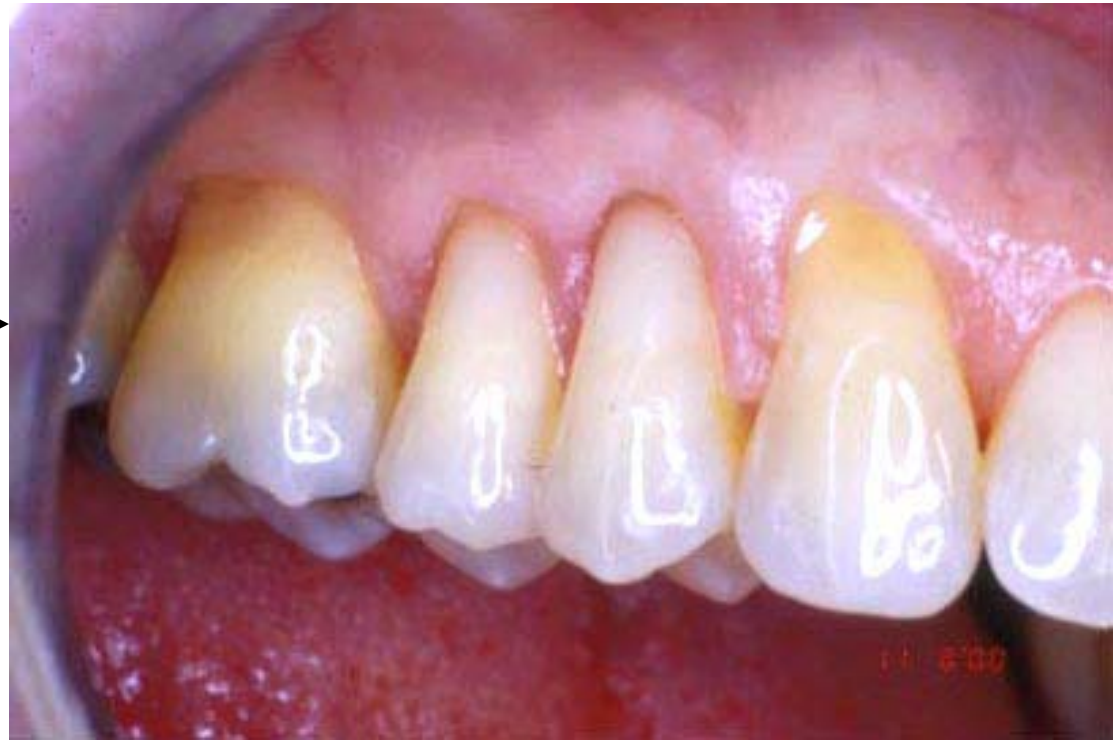

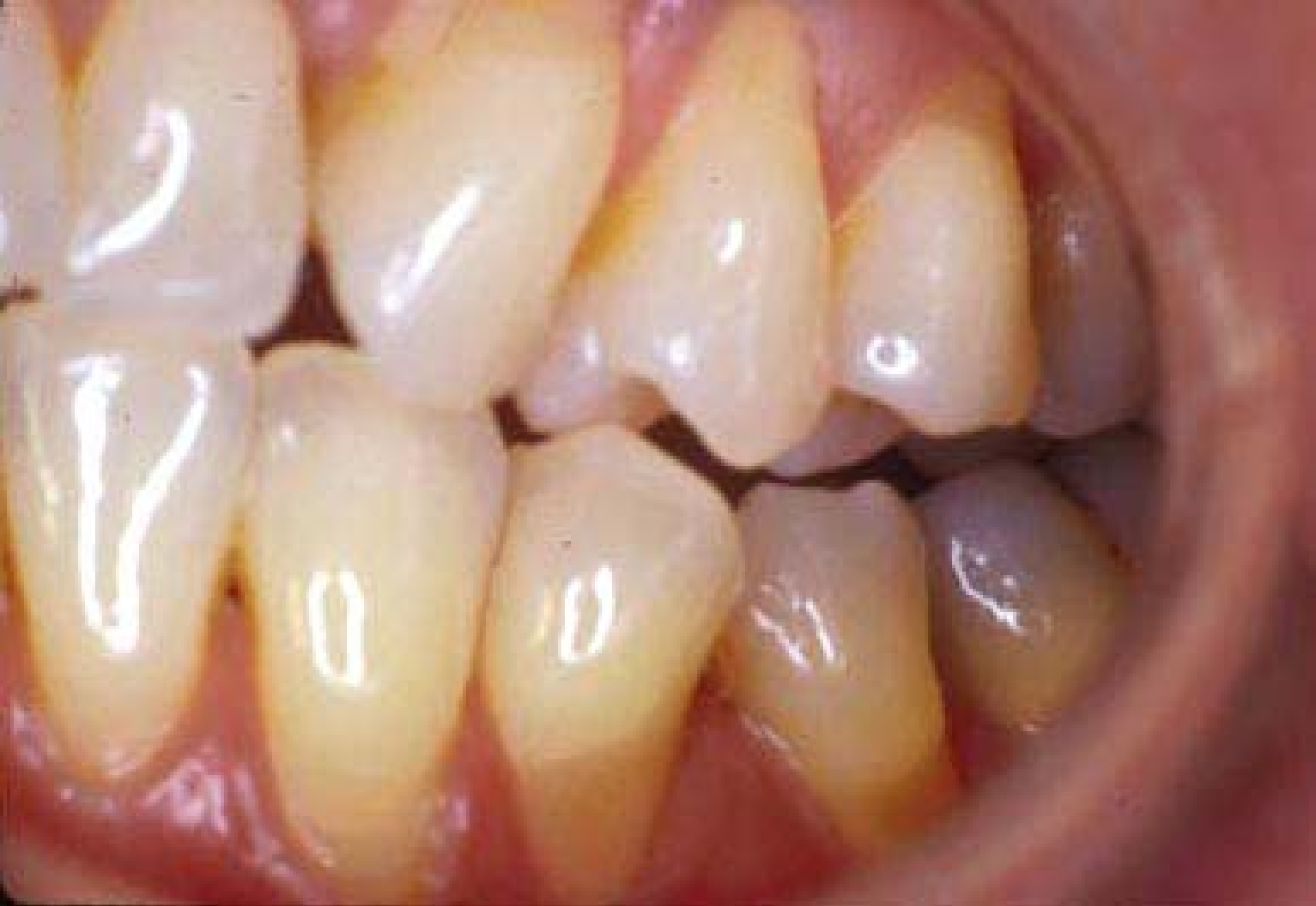Bicuspids restored.



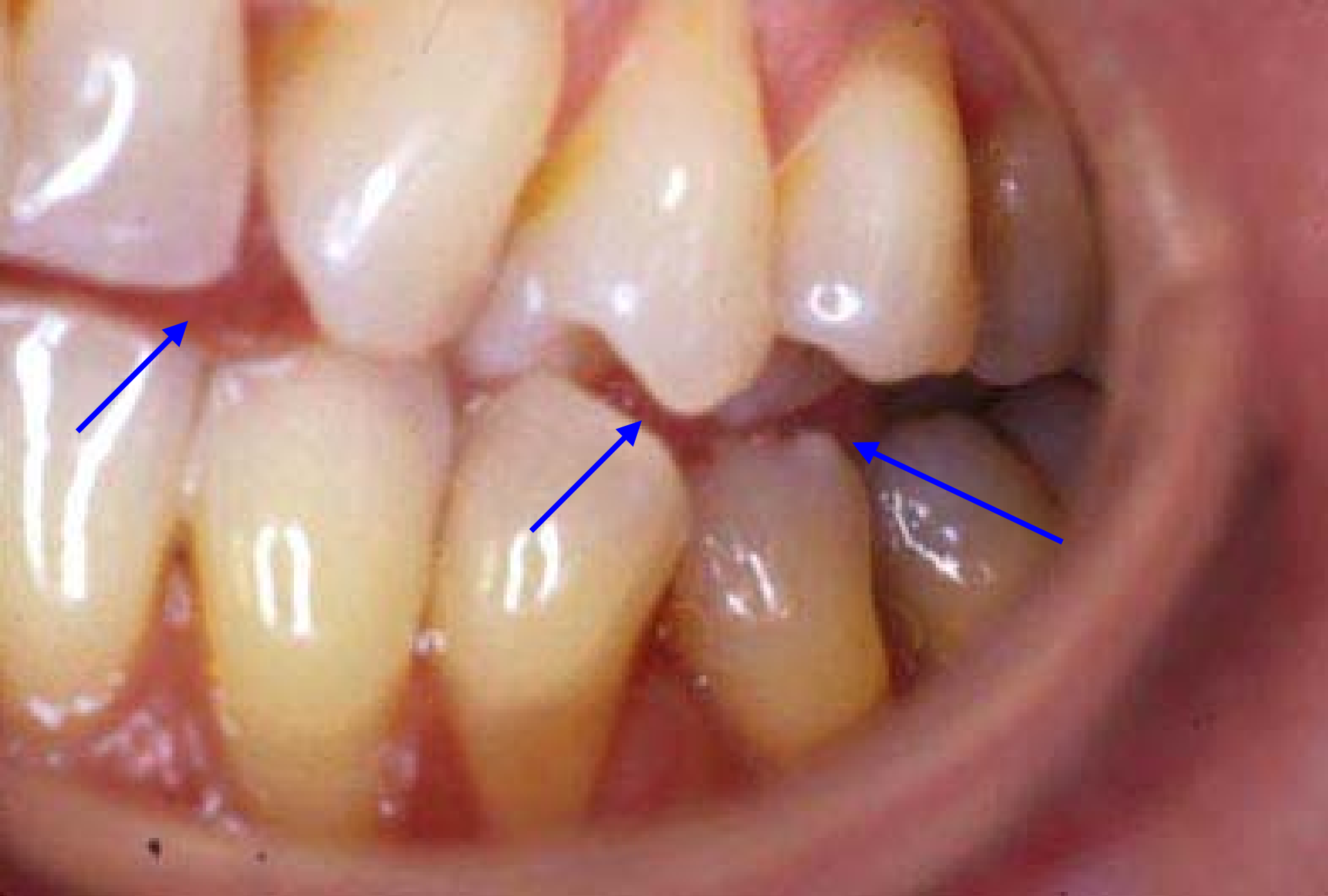← **Before #4 & 5 restored.**

**After #4 & 5 restored.** →

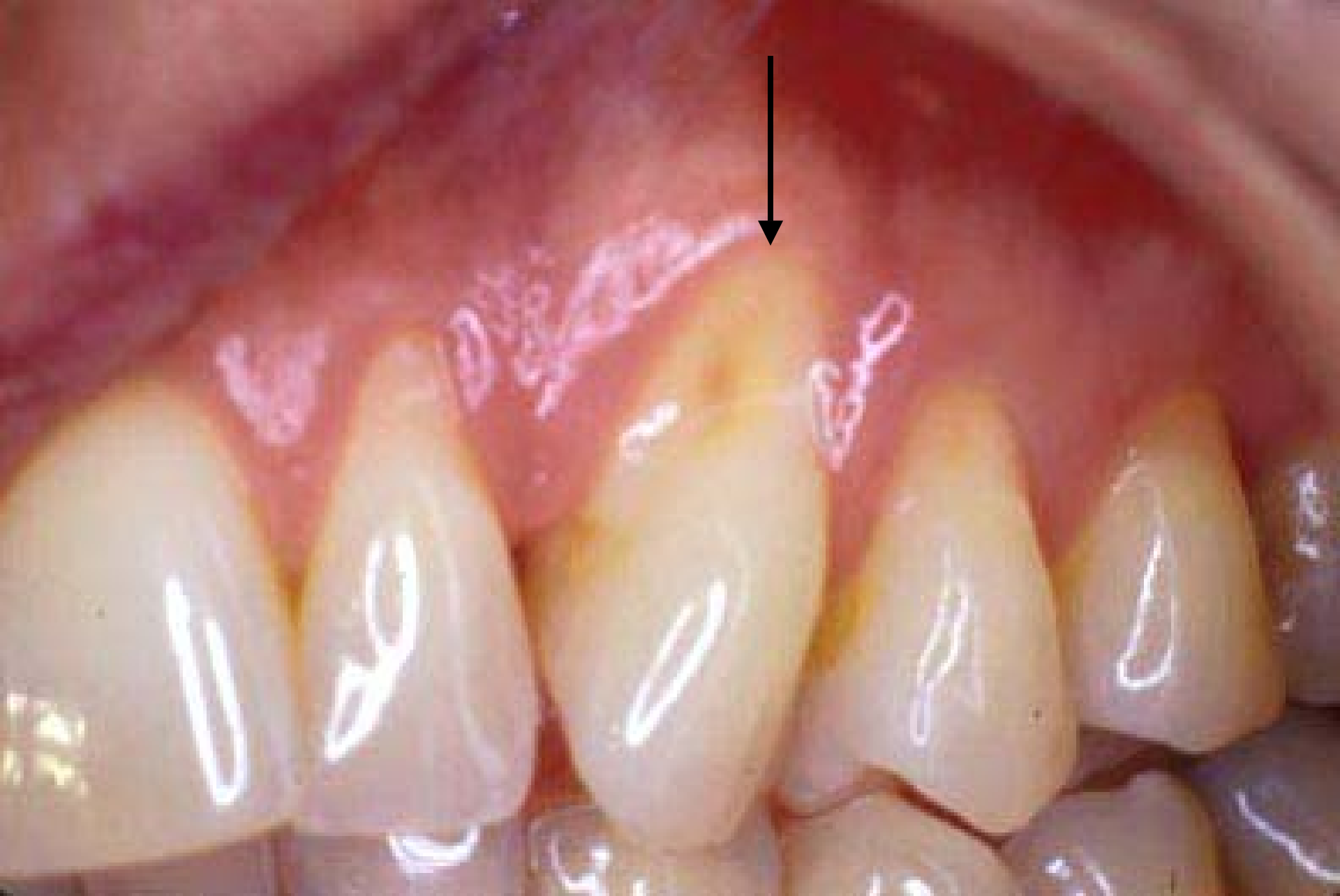



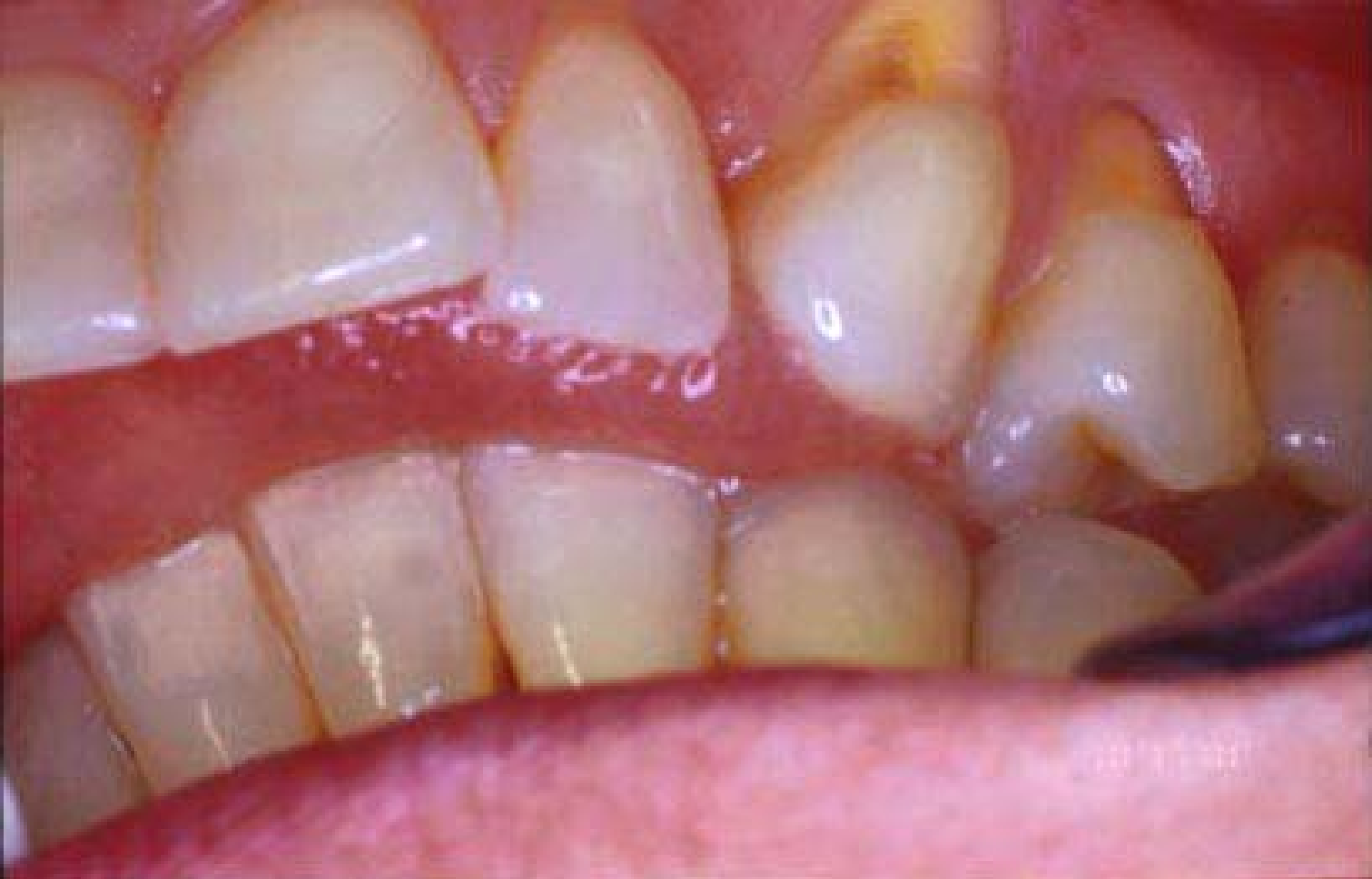B85 Left side abfractions and 'open spaces'.



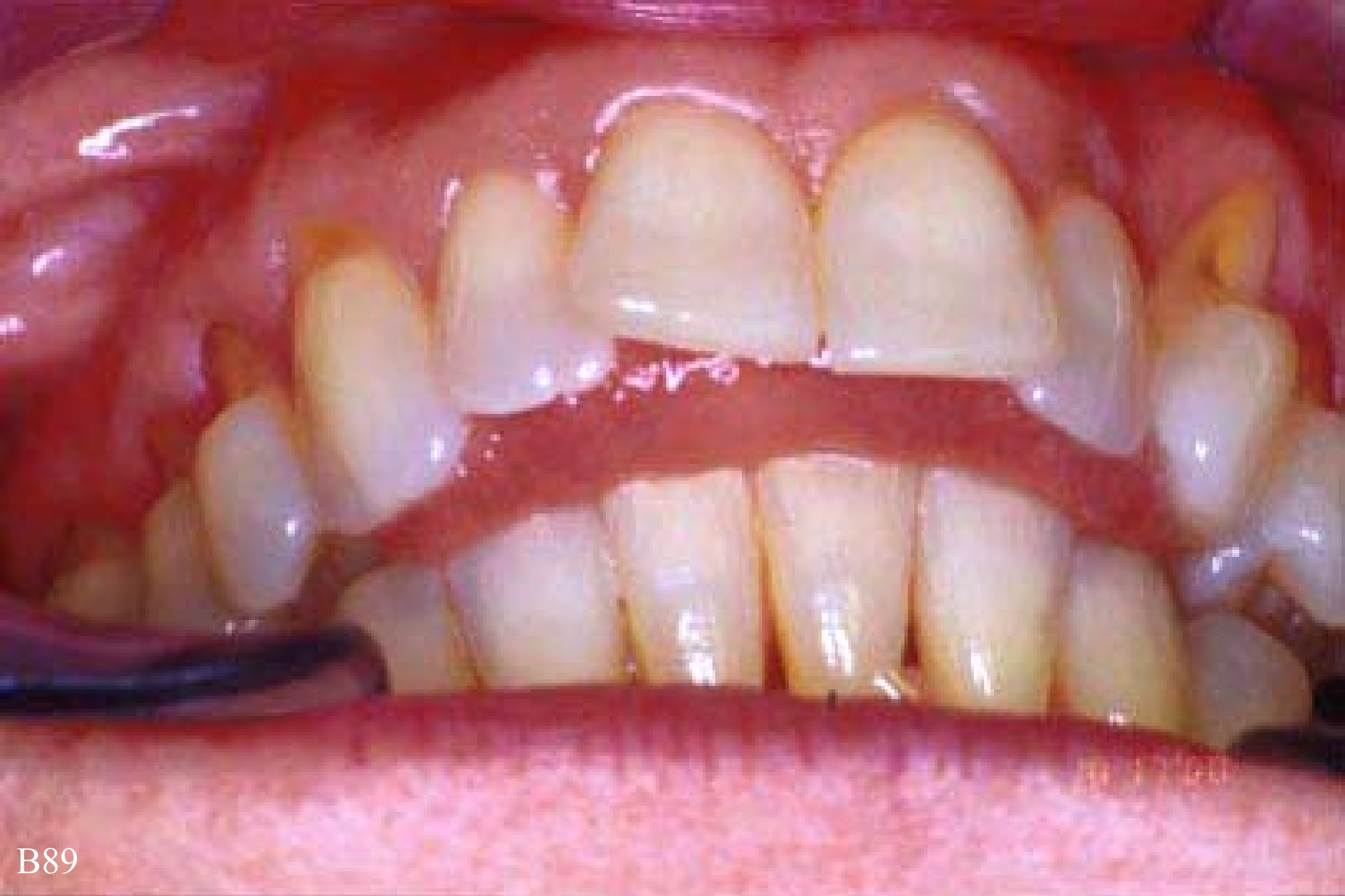B86 Note tongue thrust in 'open spaces' (arrows).



Close-up of abfraction on cuspid.

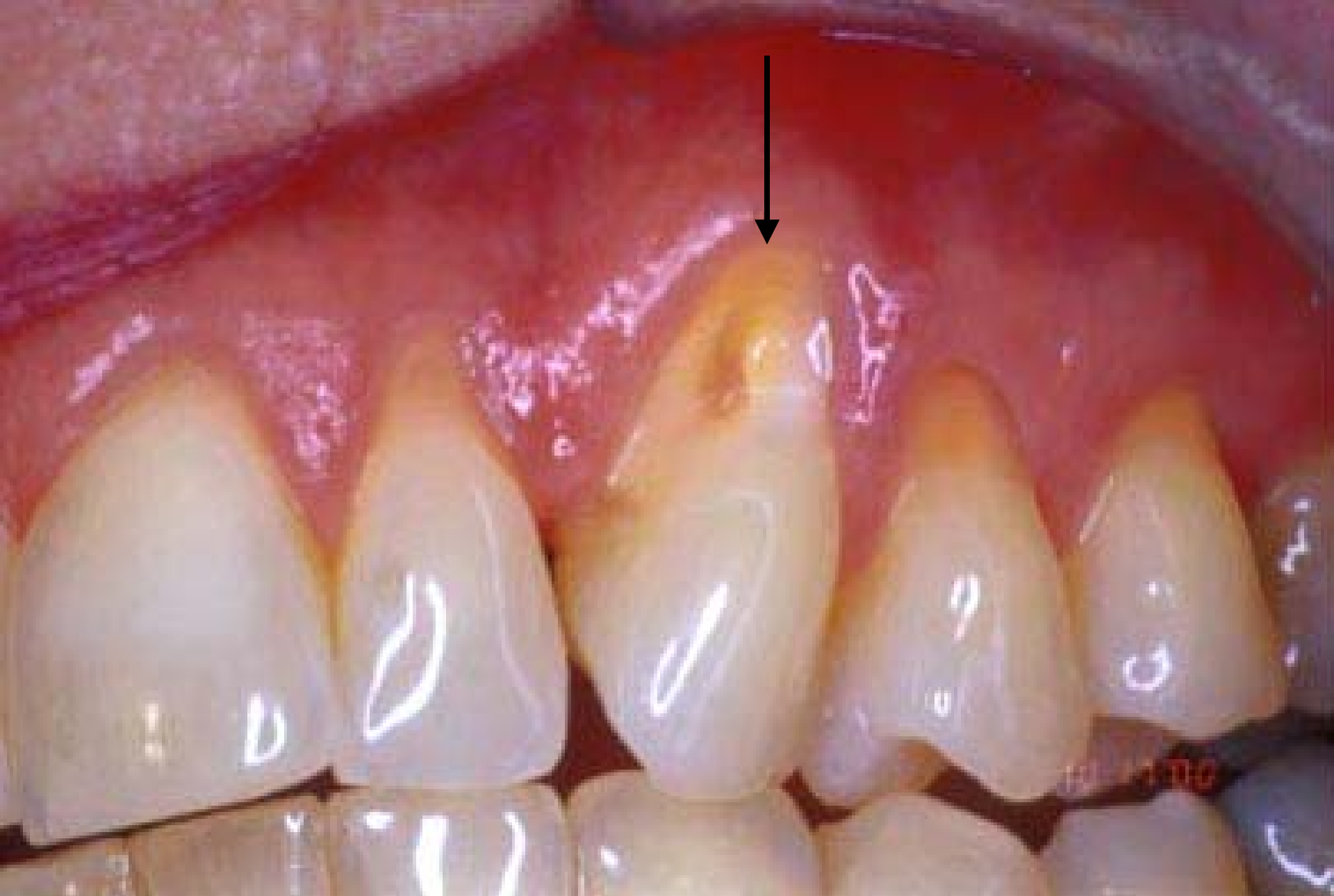

Tongue thrust **HAS CAUSED** abfraction on cuspid.  
B88 It is the **ONLY** lateral traumatic force on the cuspid.

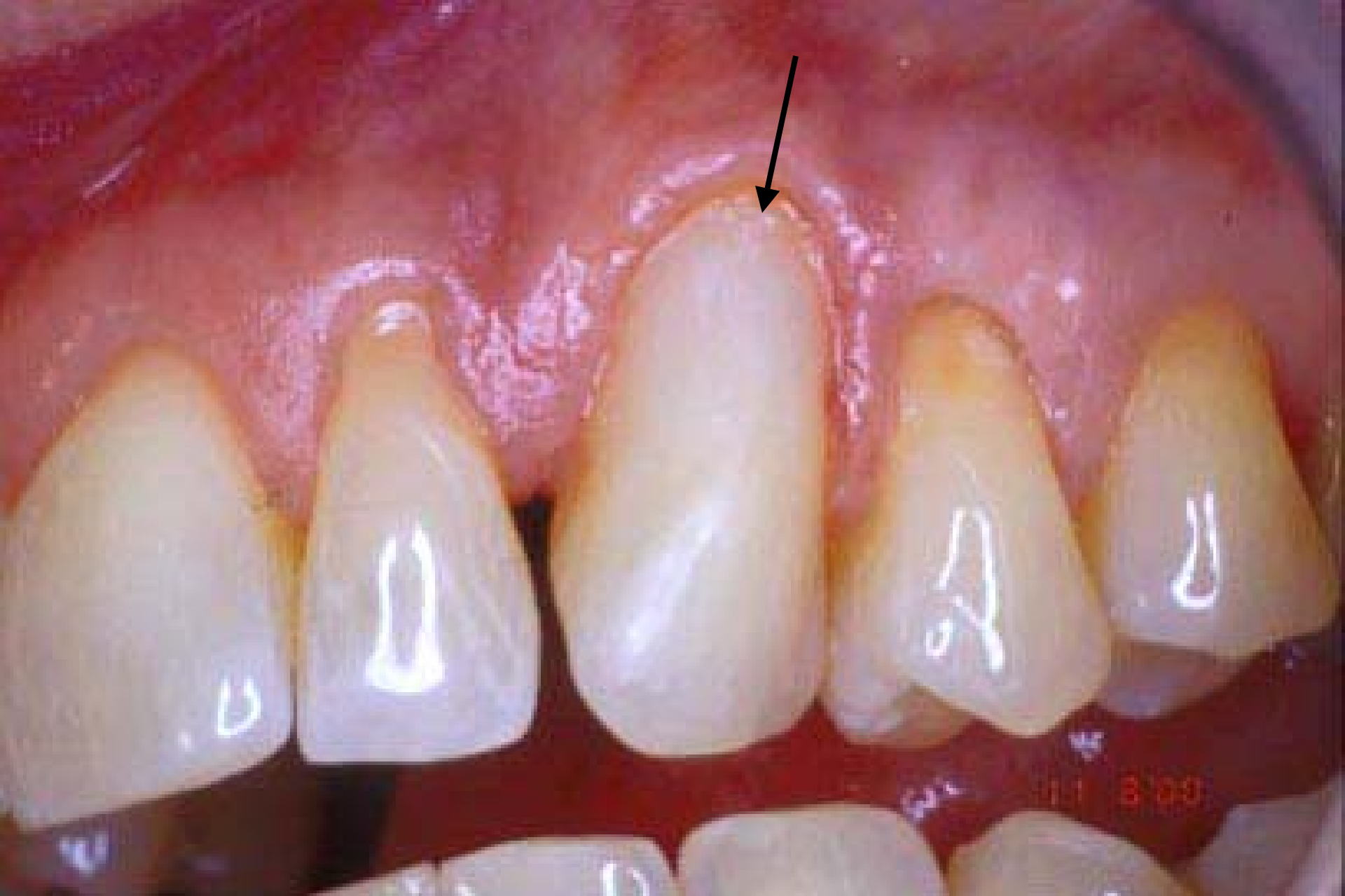

B89

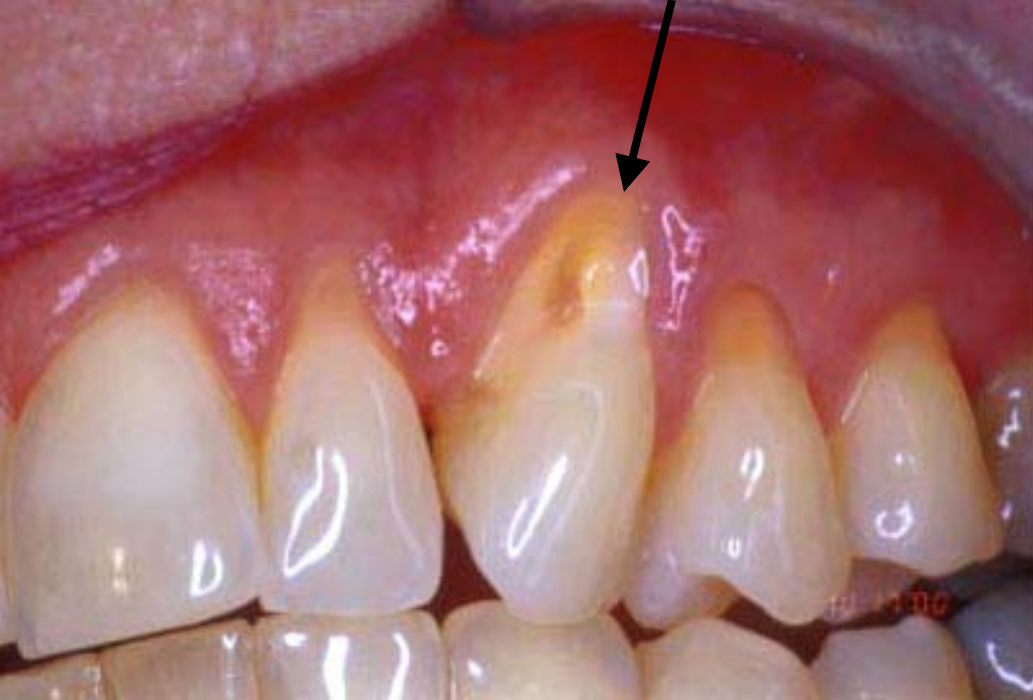This tongue thrust places traumatic forces on these cuspids.



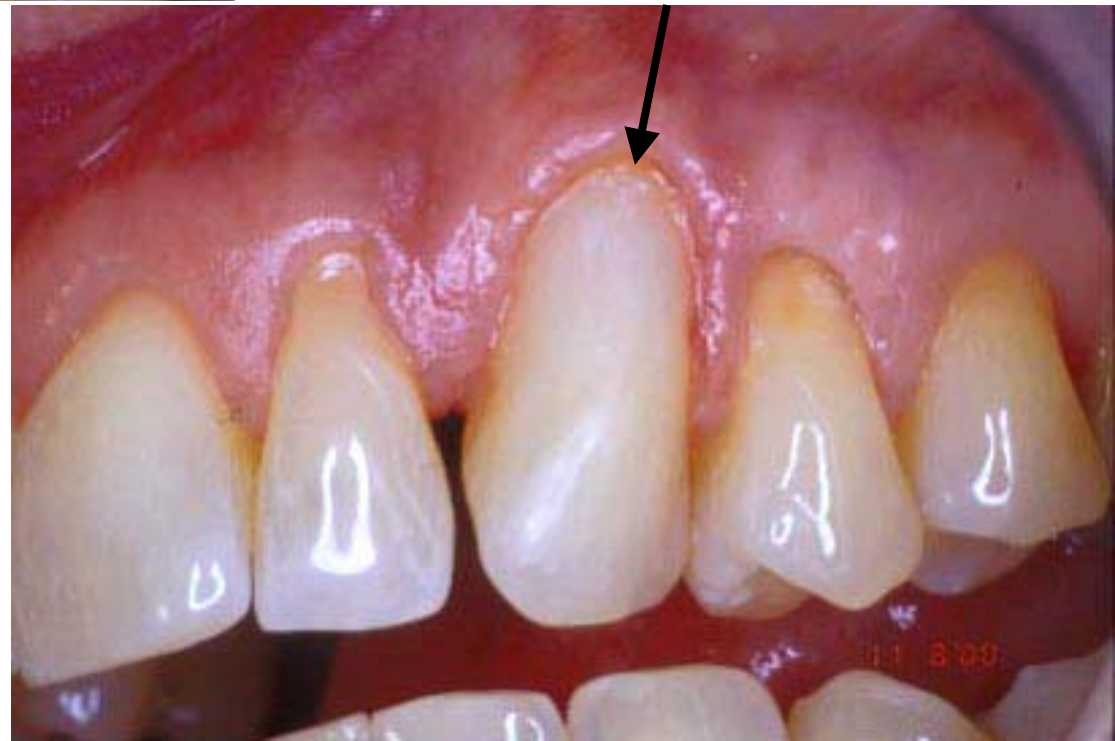Pre-treatment of cuspid.



B91 Cuspid restored with composite restoration.



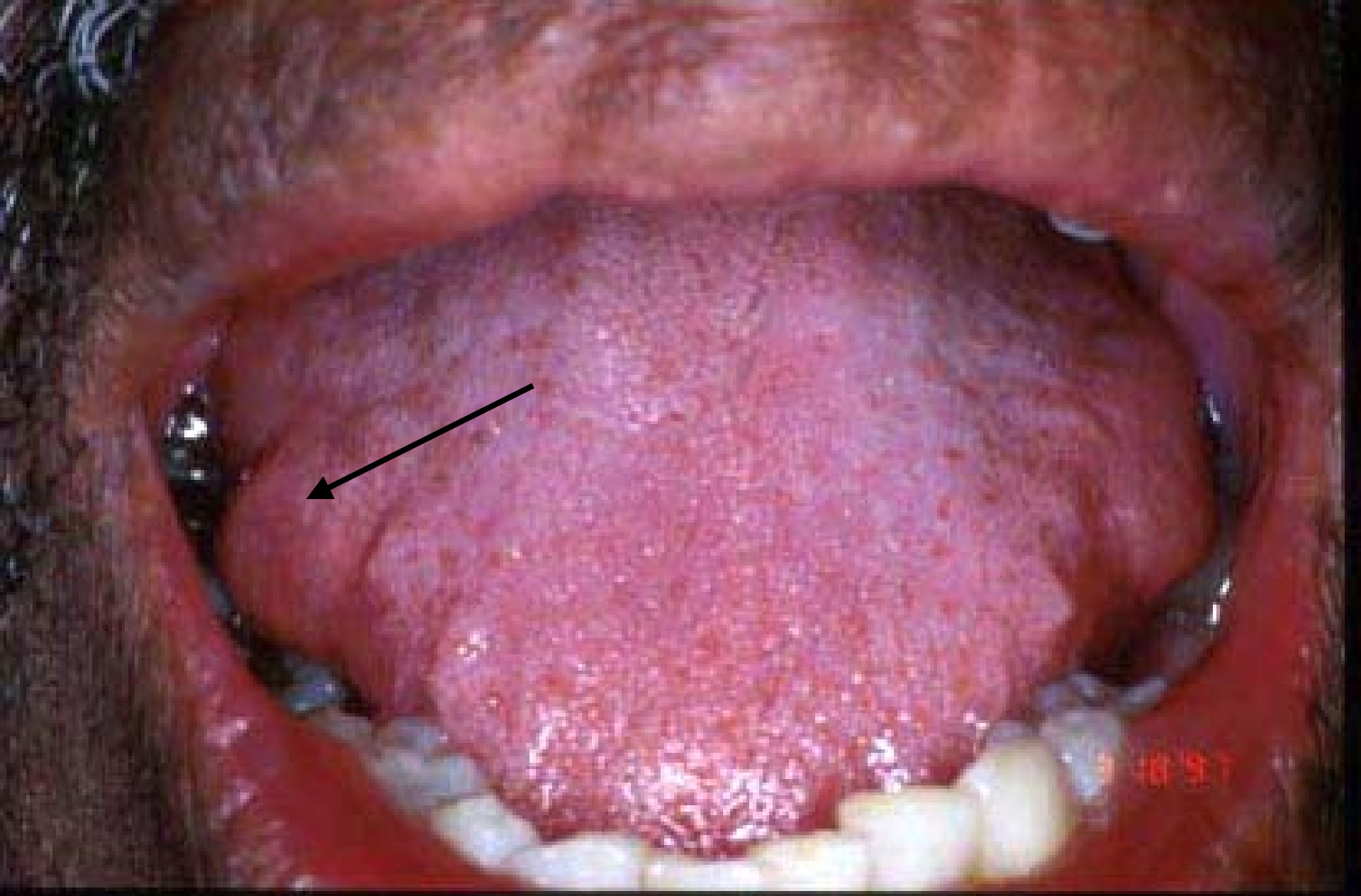
**Cuspid before composite.**



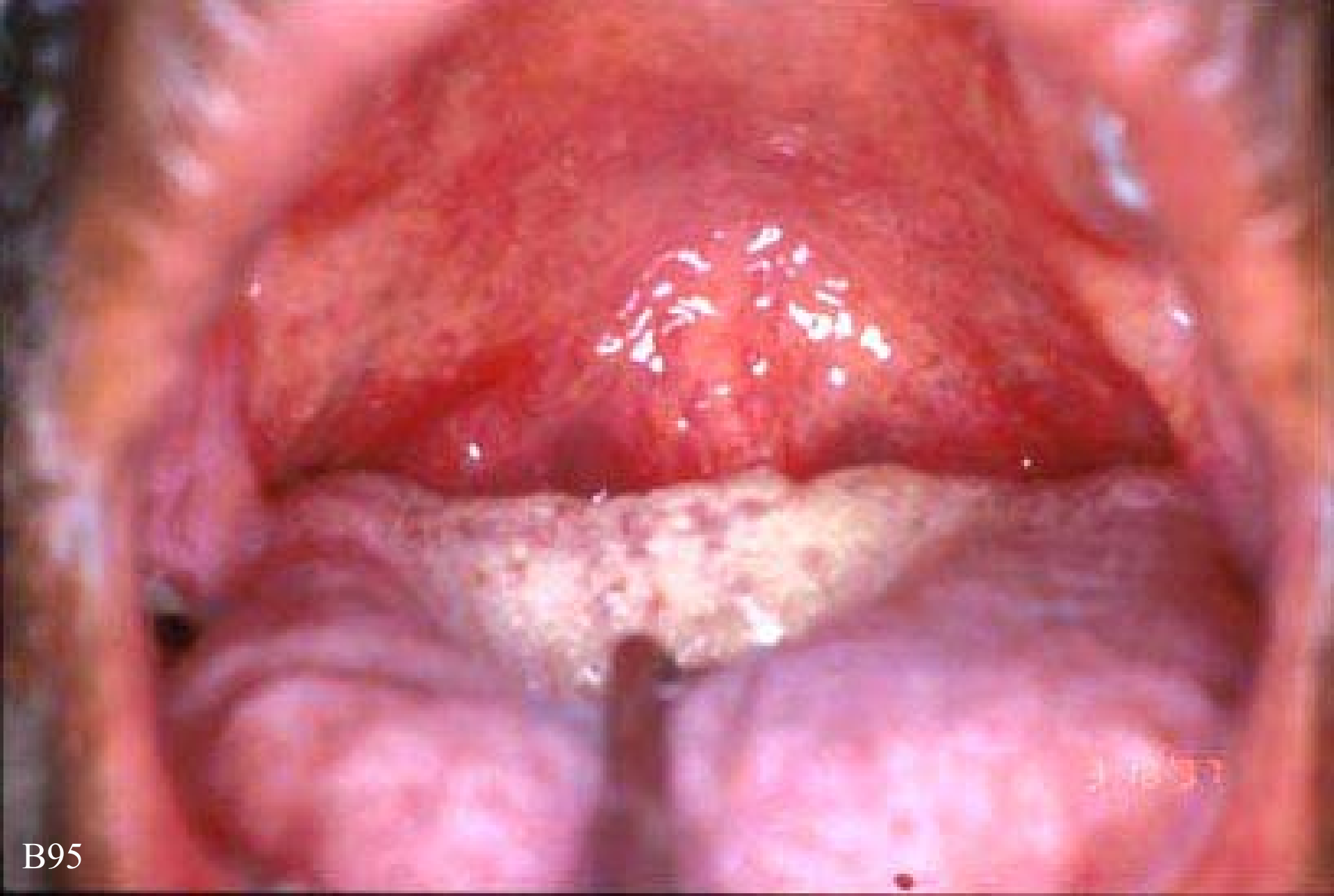**Cuspid after composite.**

The previous case demonstrates the importance of evaluating frenums at birth and also understanding the severe consequences of a tongue thrust. These topics are covered more thoroughly in other presentations on this website.

**End of case.**

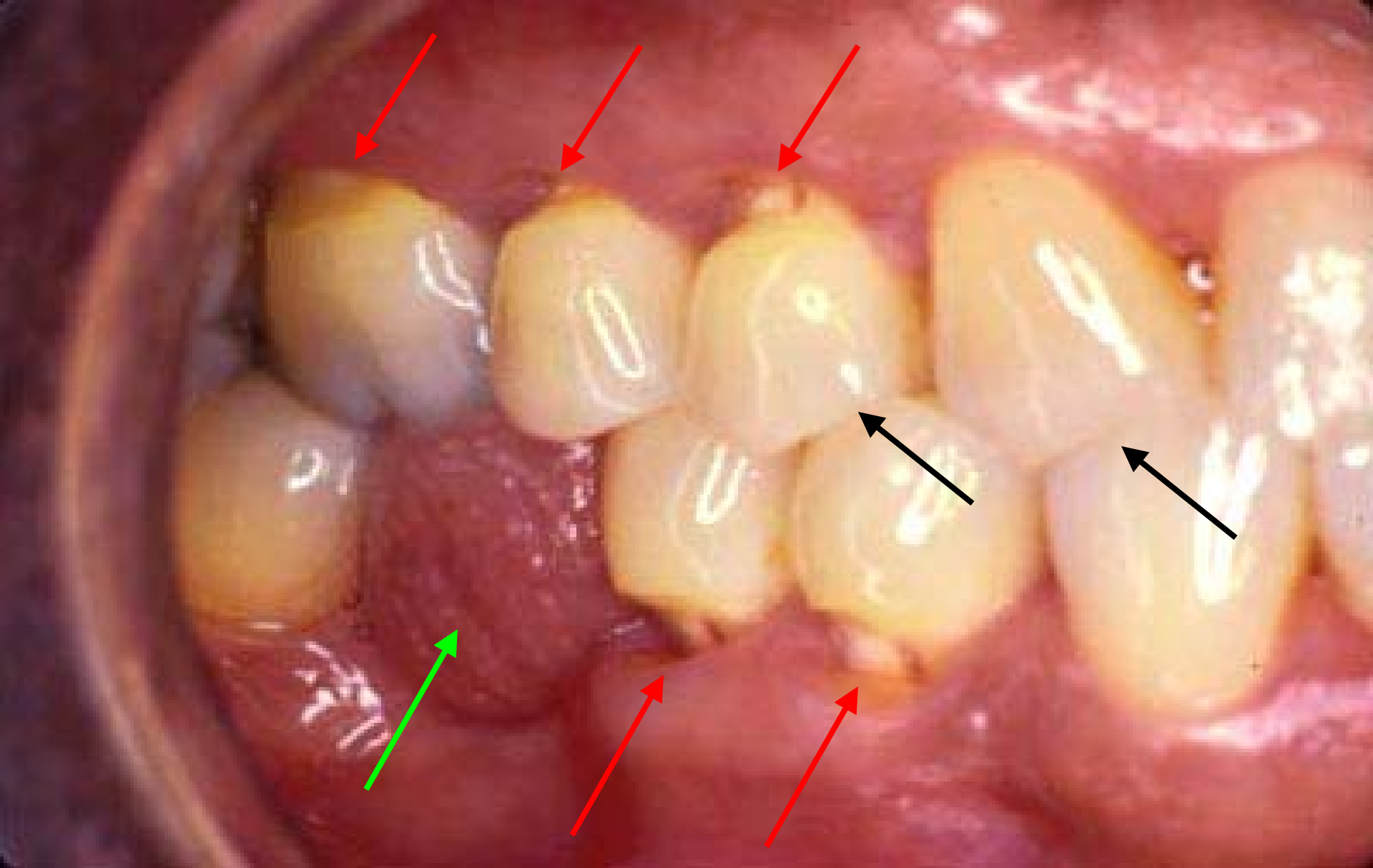


Note large tongue. (Part of 12 slide case).



B95

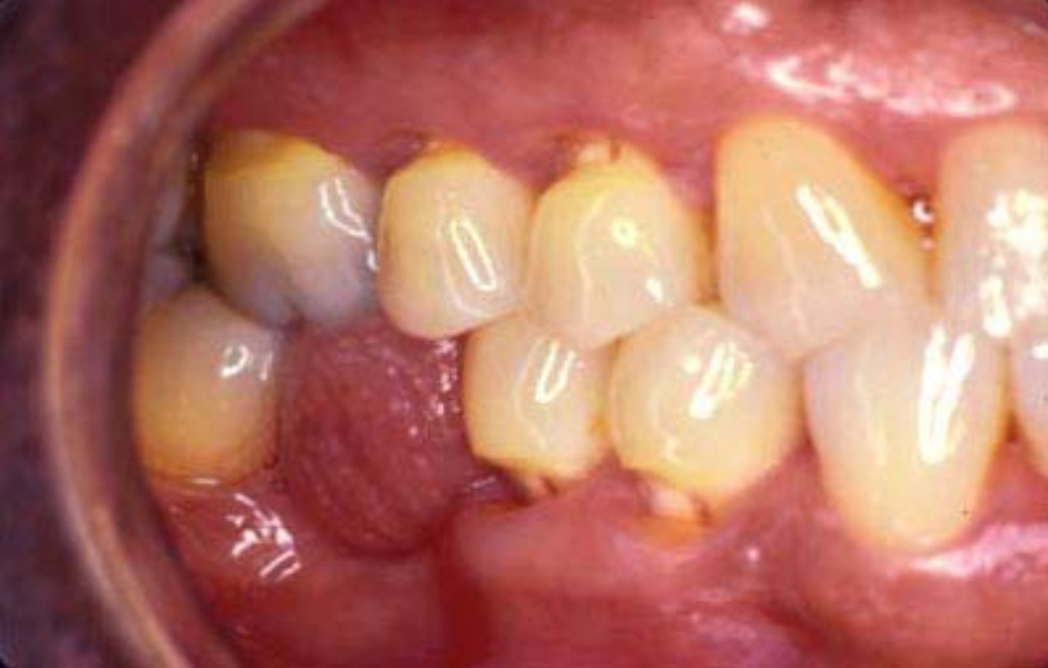Subject has compromised oropharynx. See next slide



Abfractions similar to tooth extracted in 1993.

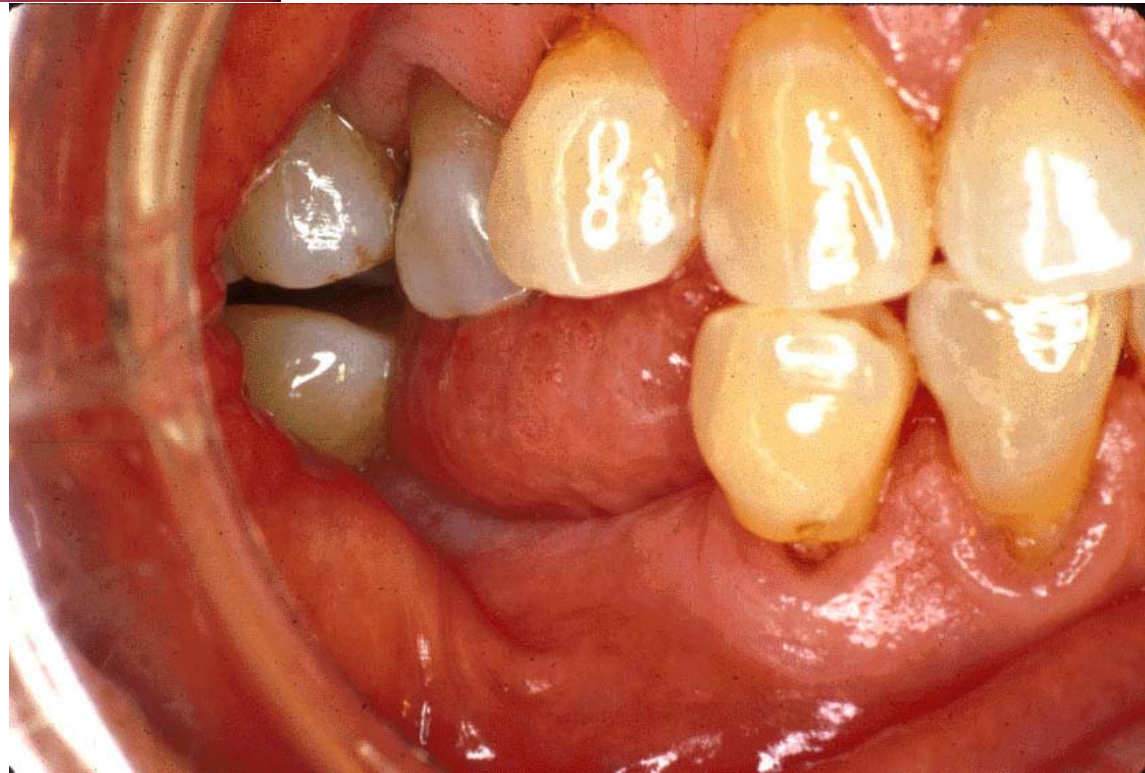
B96

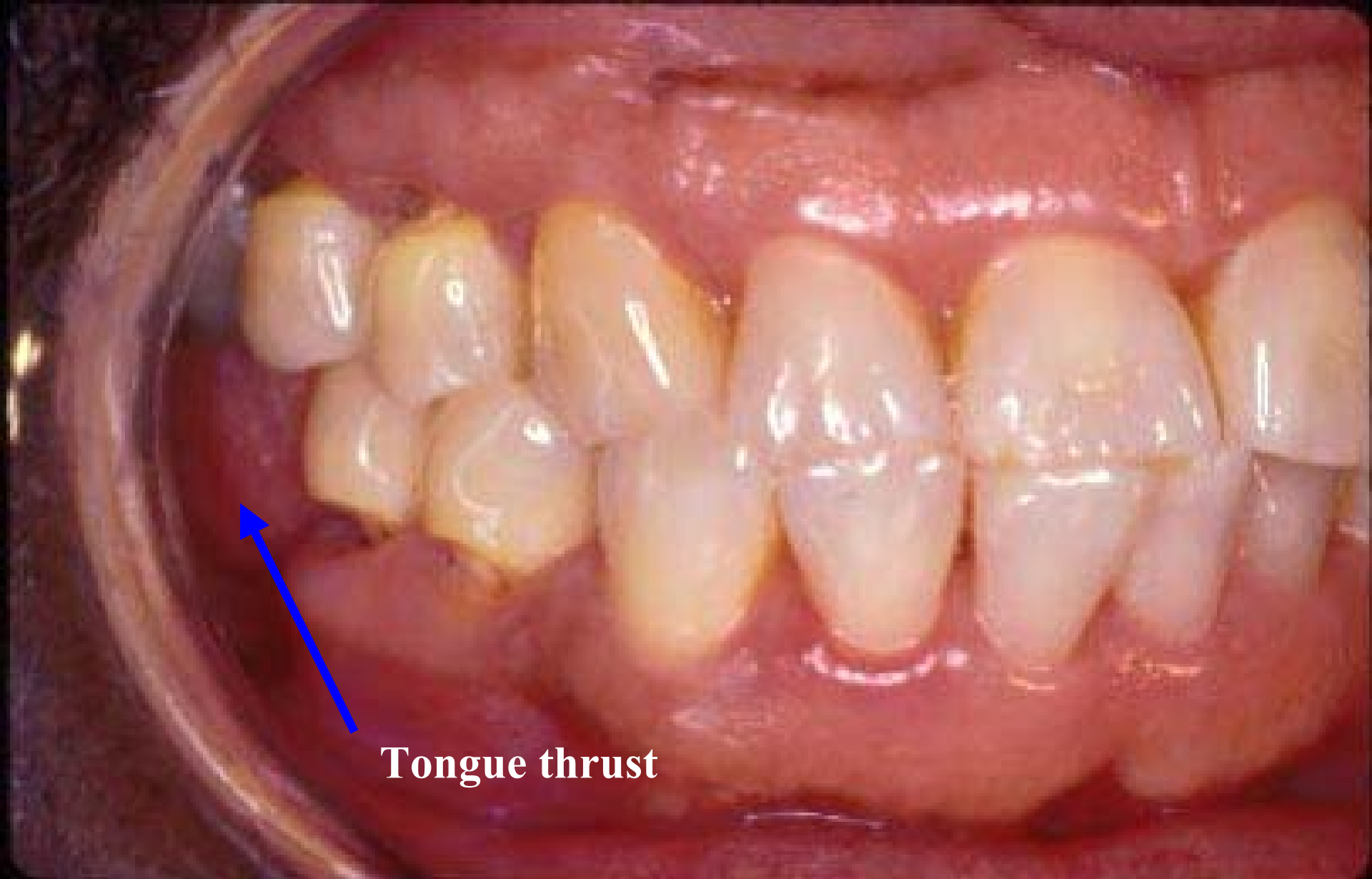
Tight bite and tongue thrust. See next slide.



← 1994 LR case

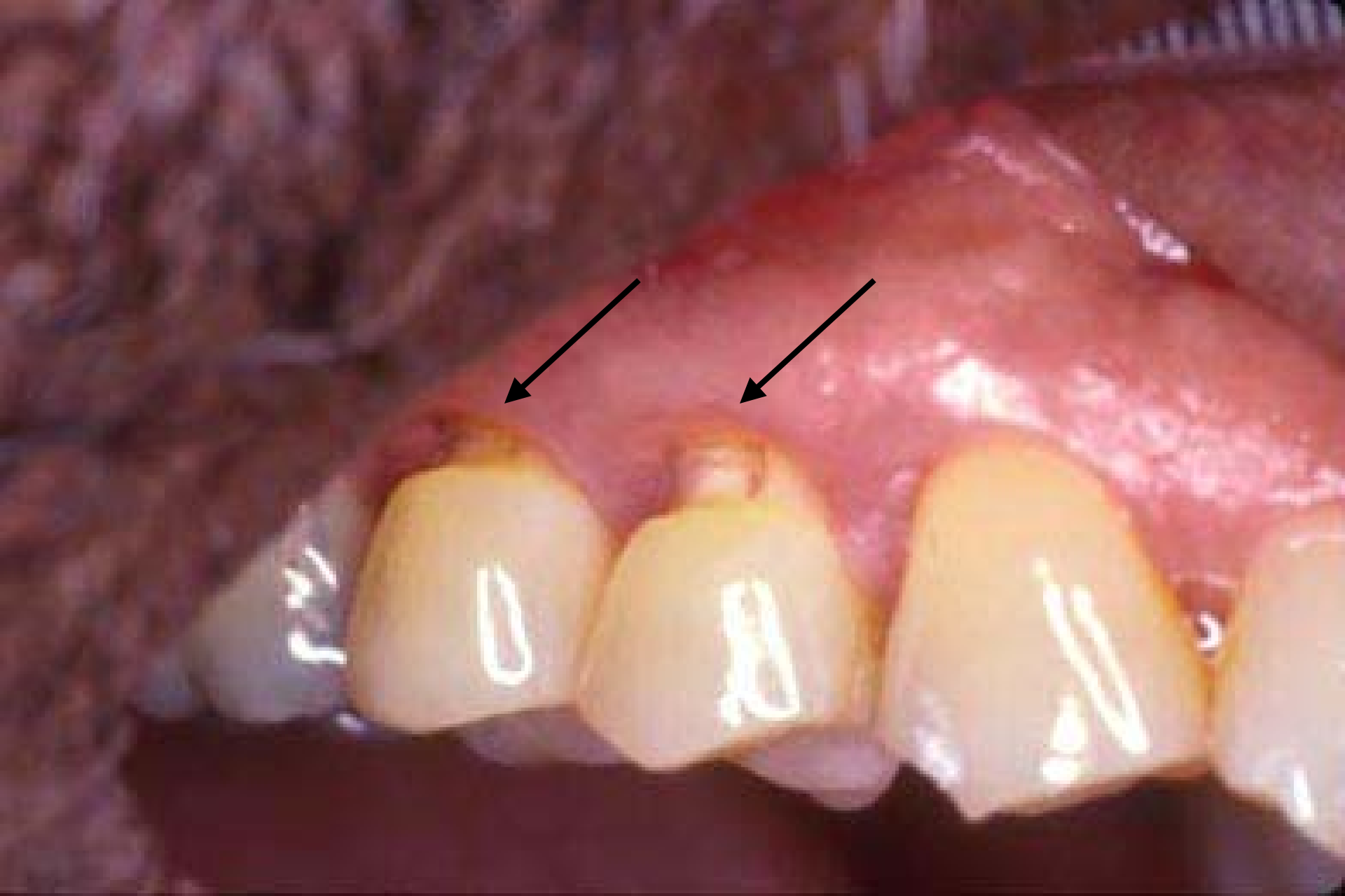
1993 EA case →





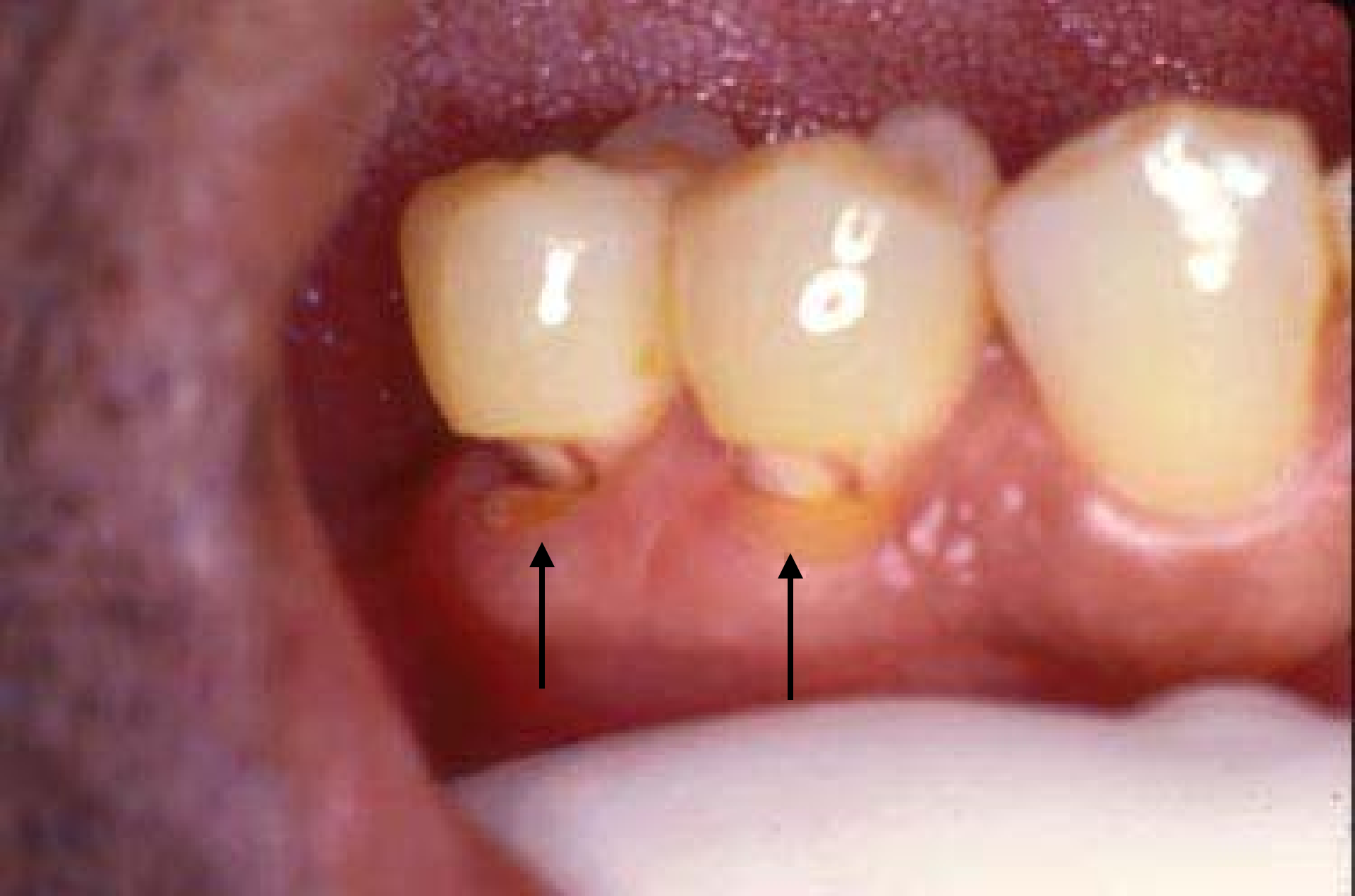
**Tongue thrust**

**Abfractions - tongue thrust (blue arrow) -  
tight bite malocclusion. See next slide.**



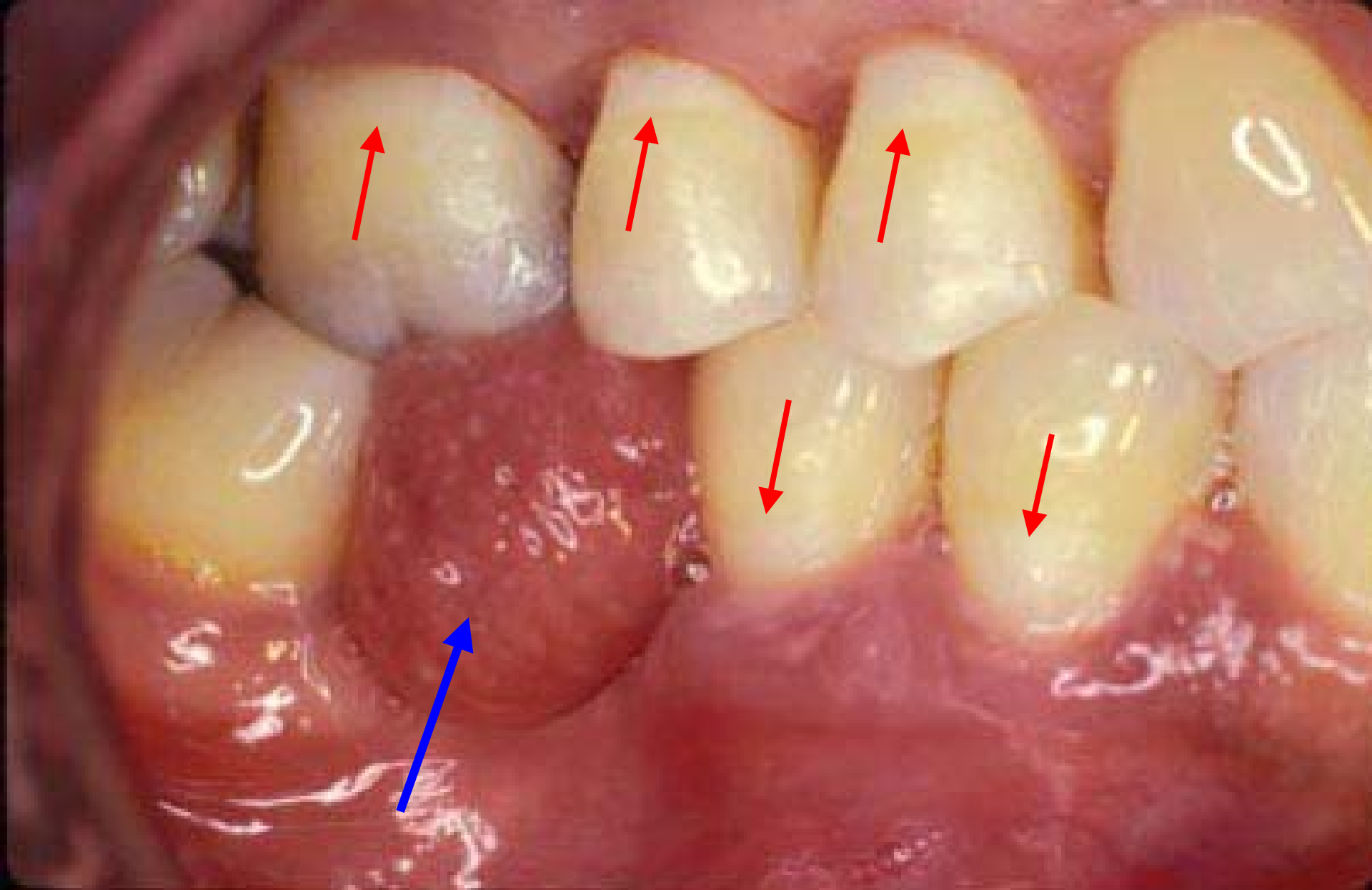
B99

Close up of upper bicuspids. See next slide.

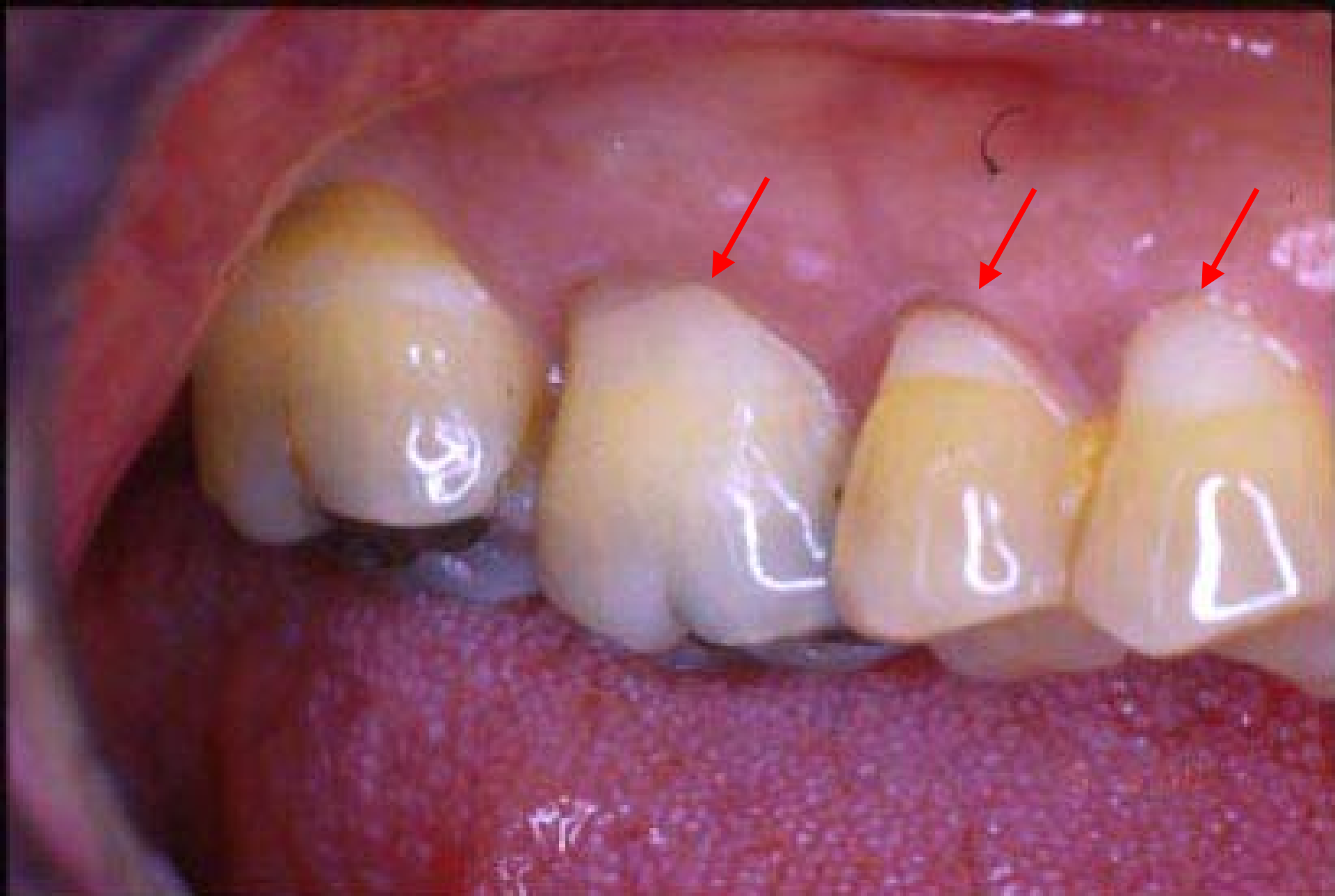

B100

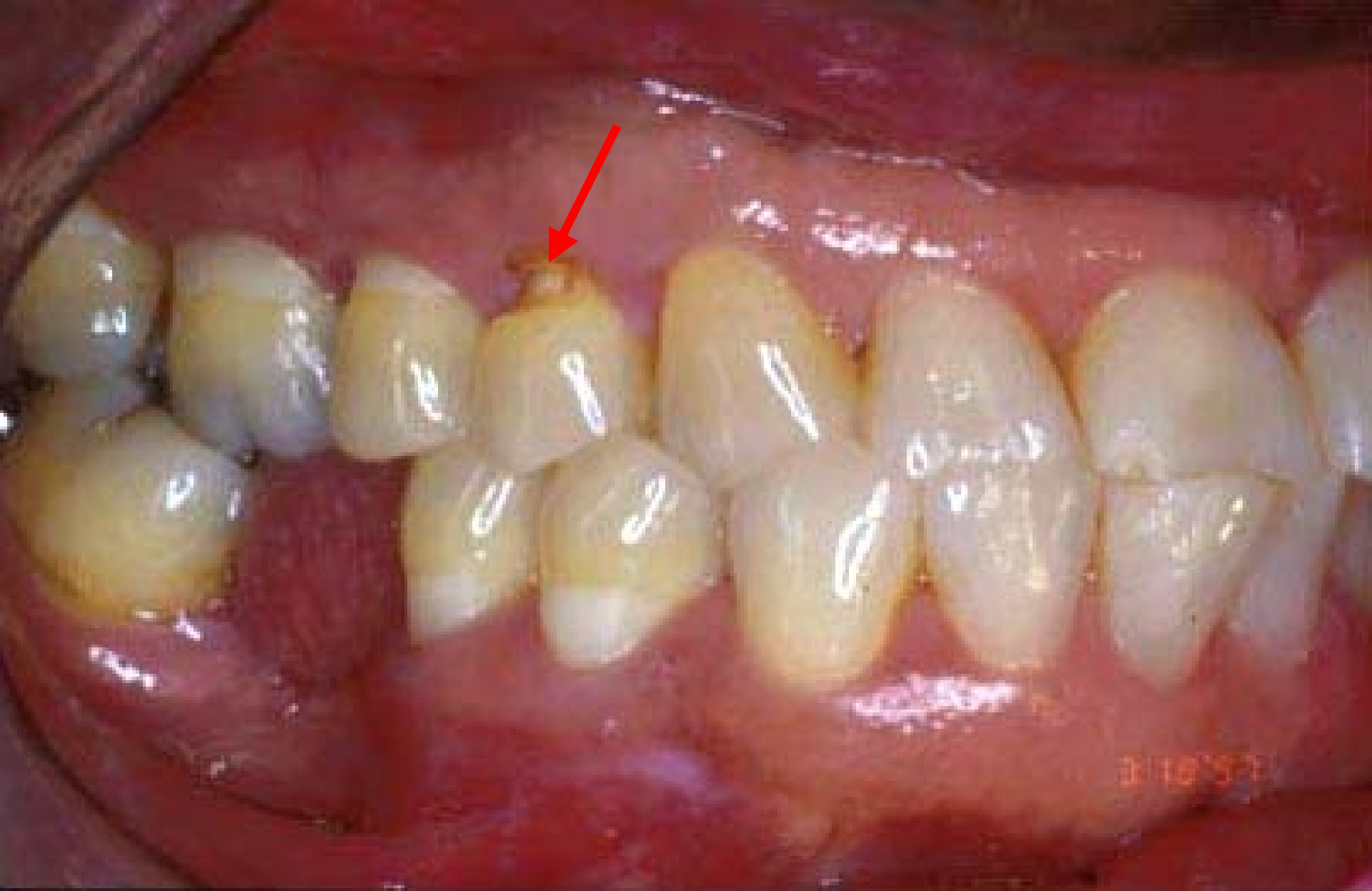Close up of lower bicuspids. See next slide.



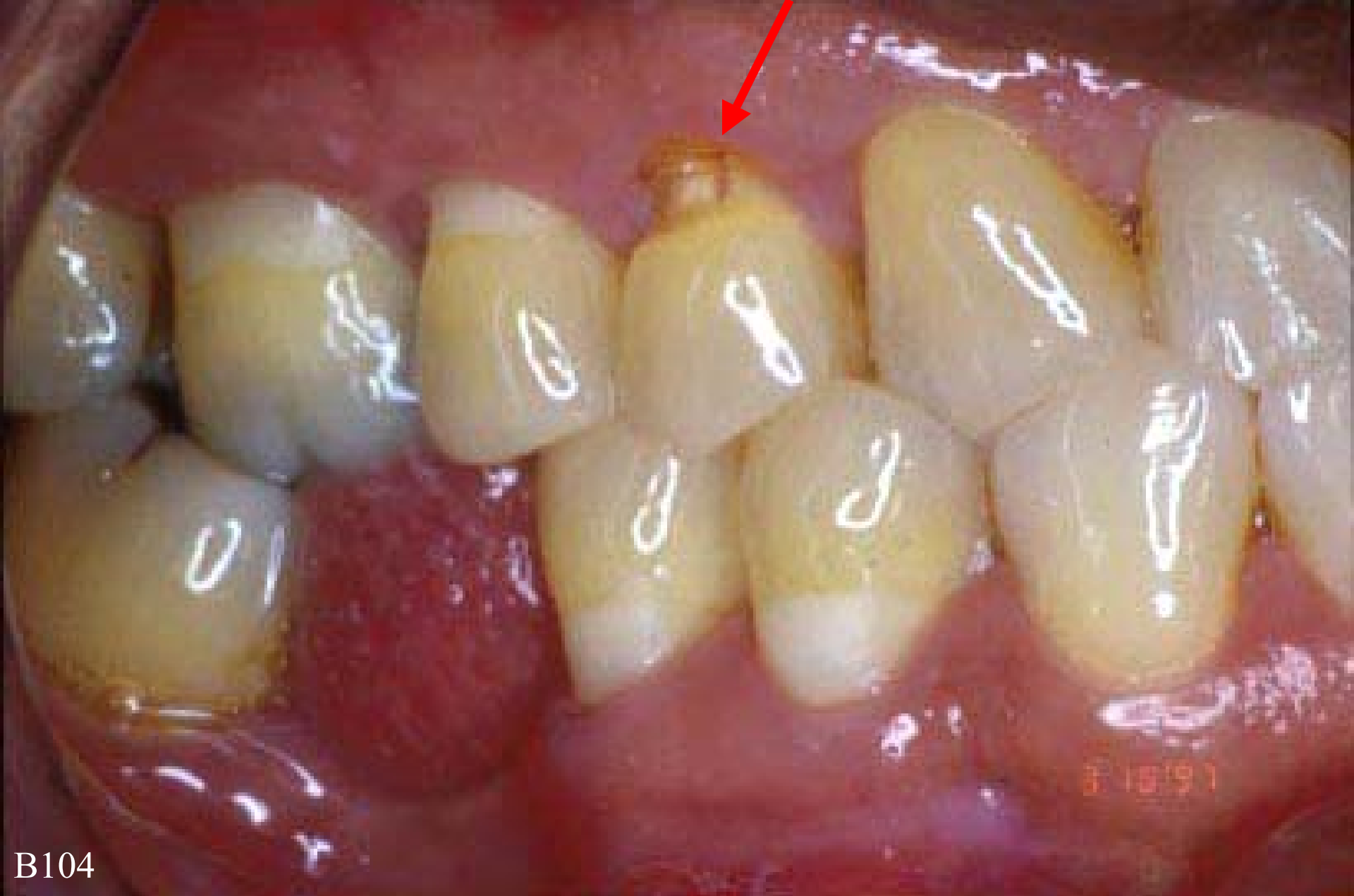
Abfractions (red) restored. Note strength of tongue thrust (blue). See next slide.



B102 Upper abfractions restored. See next slide.

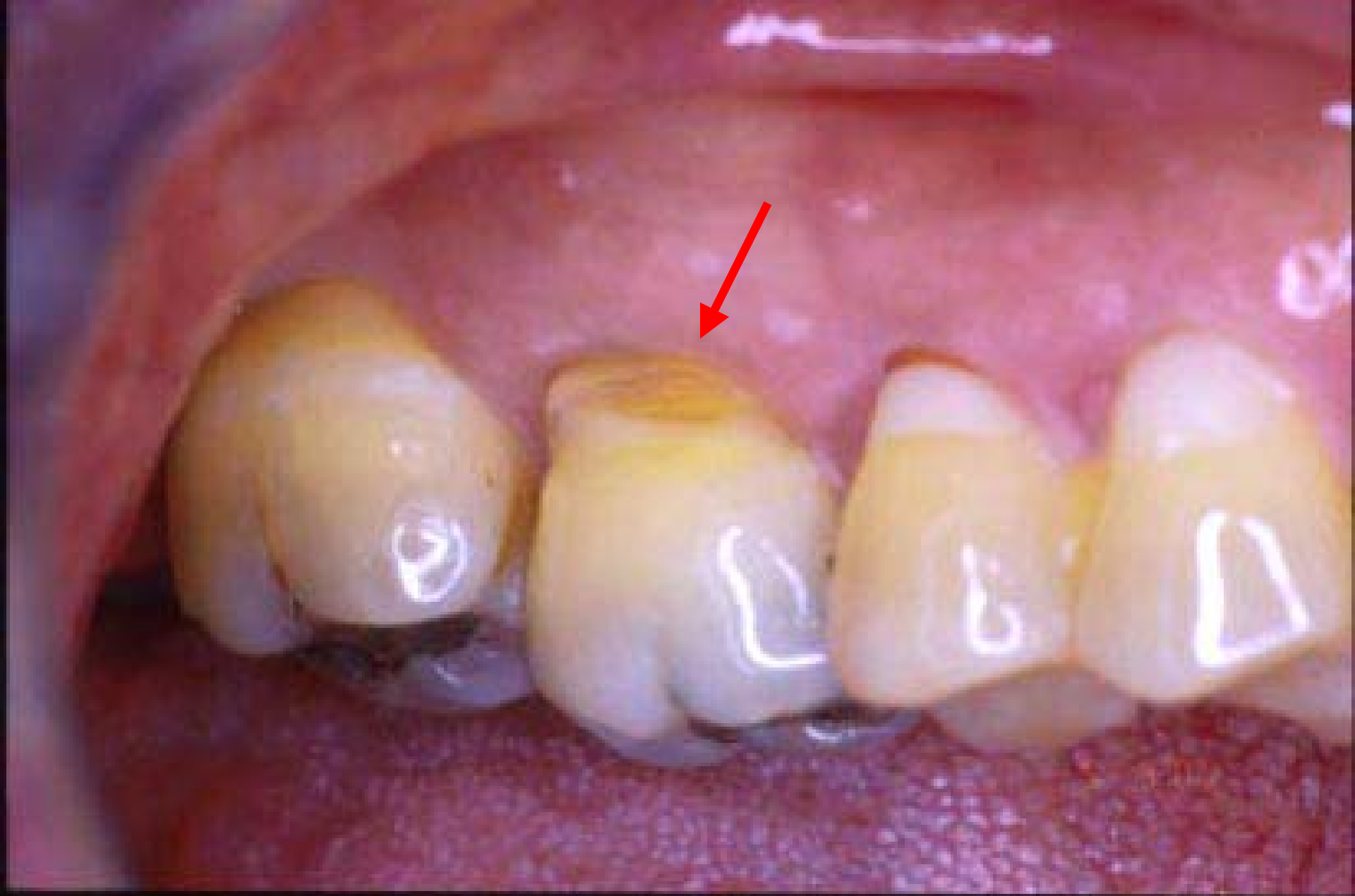

1st bicuspid failed over time and had to be redone. Note how tight the bite is. See next slide.

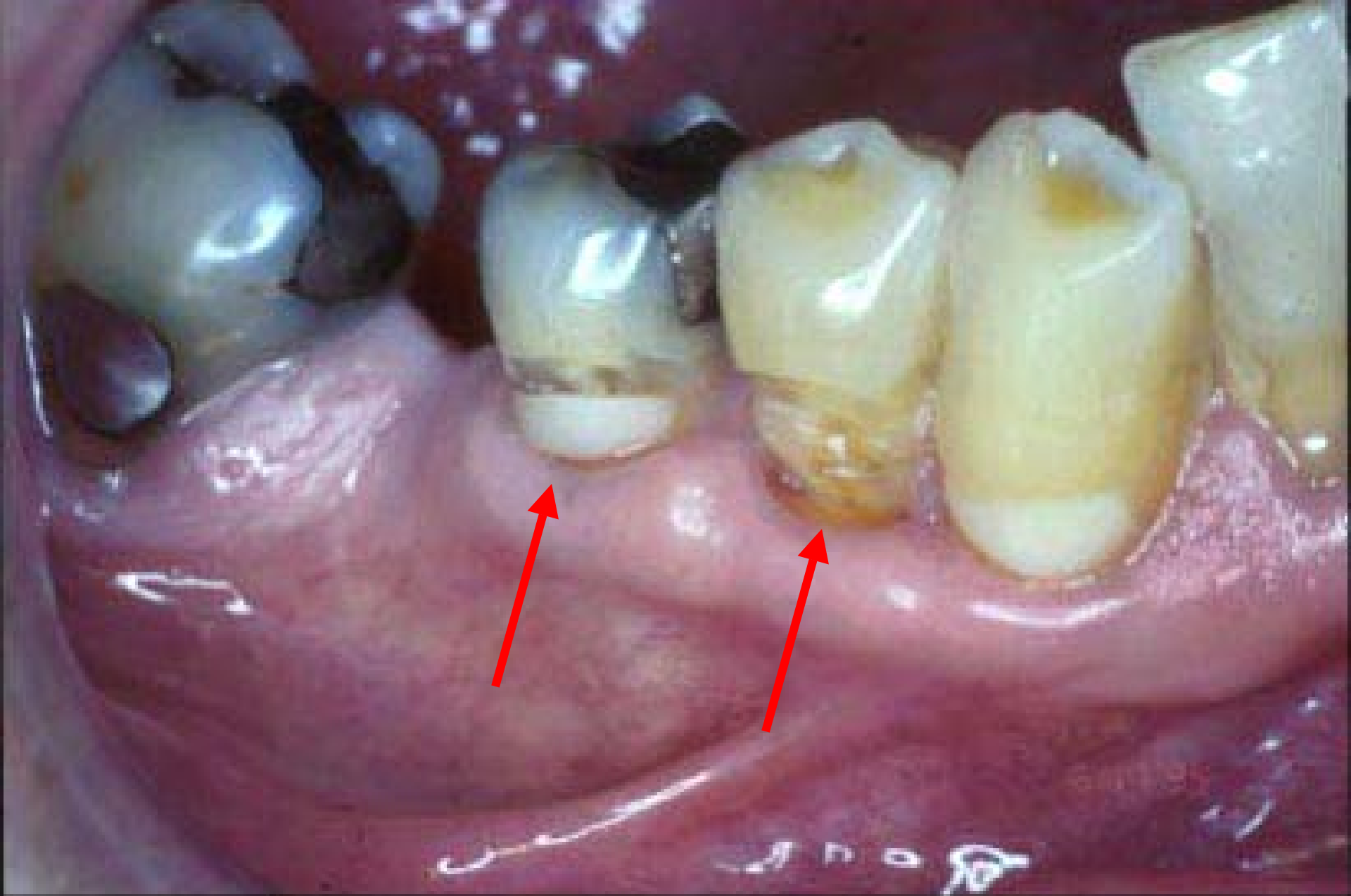


B104

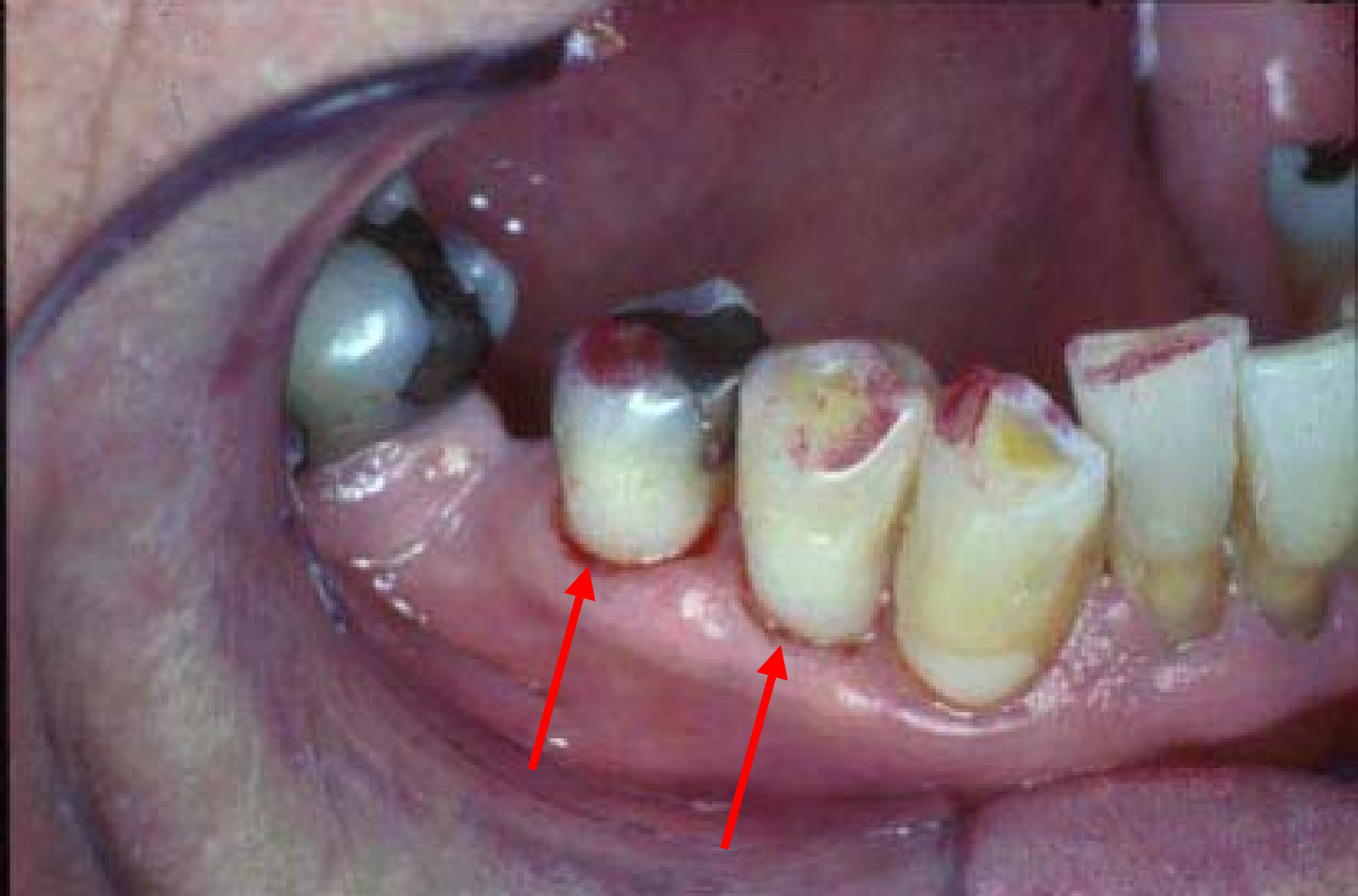Close-up of failed restoration in 1st bicuspid. See next slide.



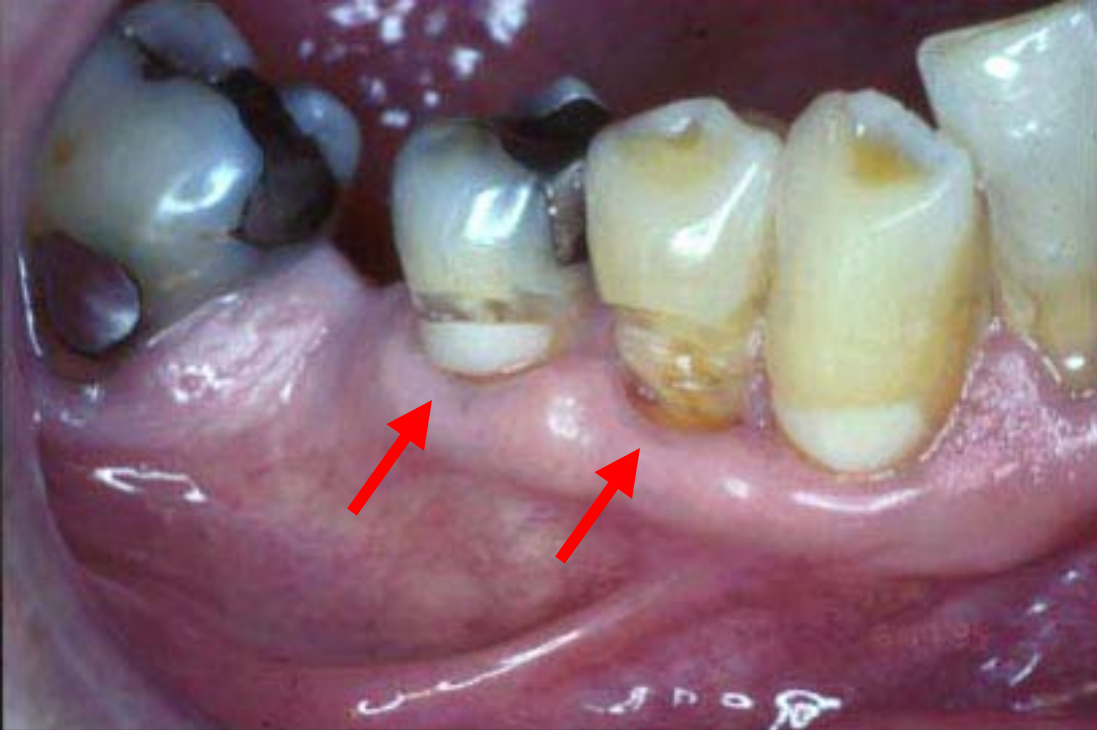B105 Molar restoration also failed over time. End of case.



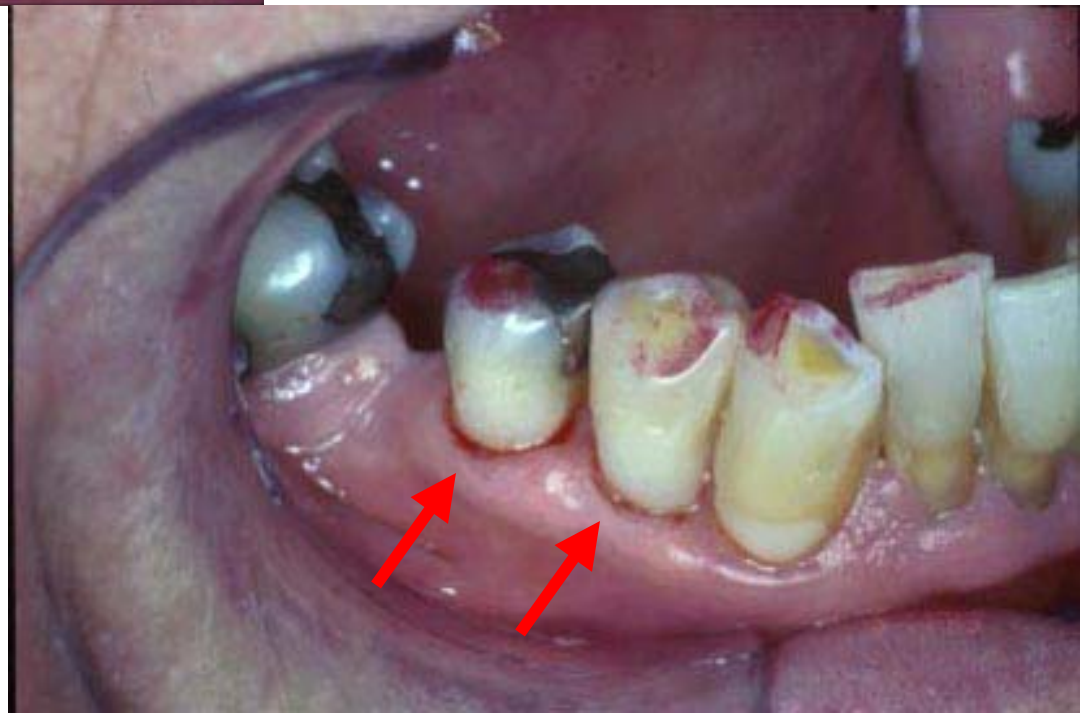B106 Abfractions in lower bicuspids. See next 2 slides.



Abfractions restored. See next slide.



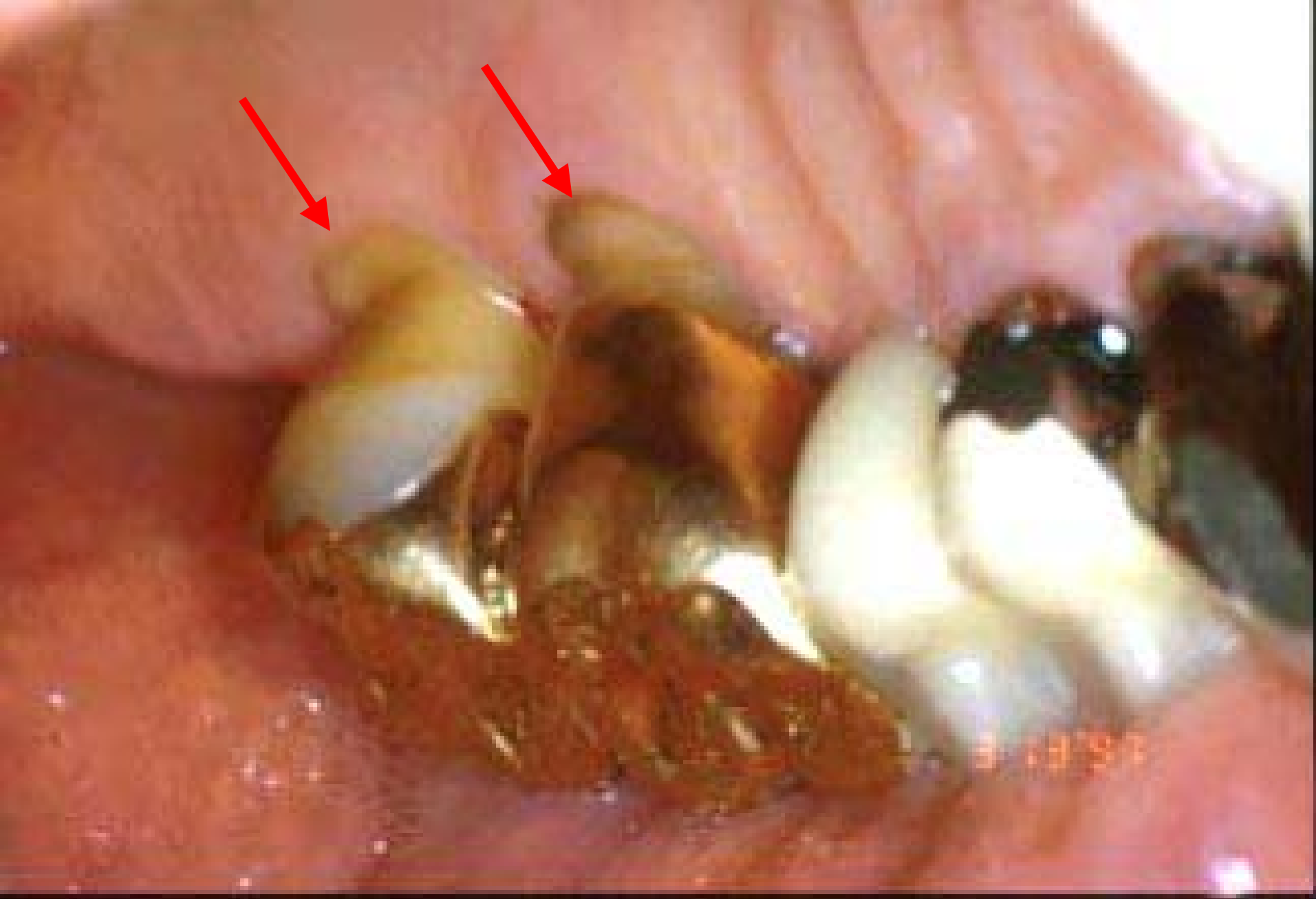← **Before**



**After** →

B108

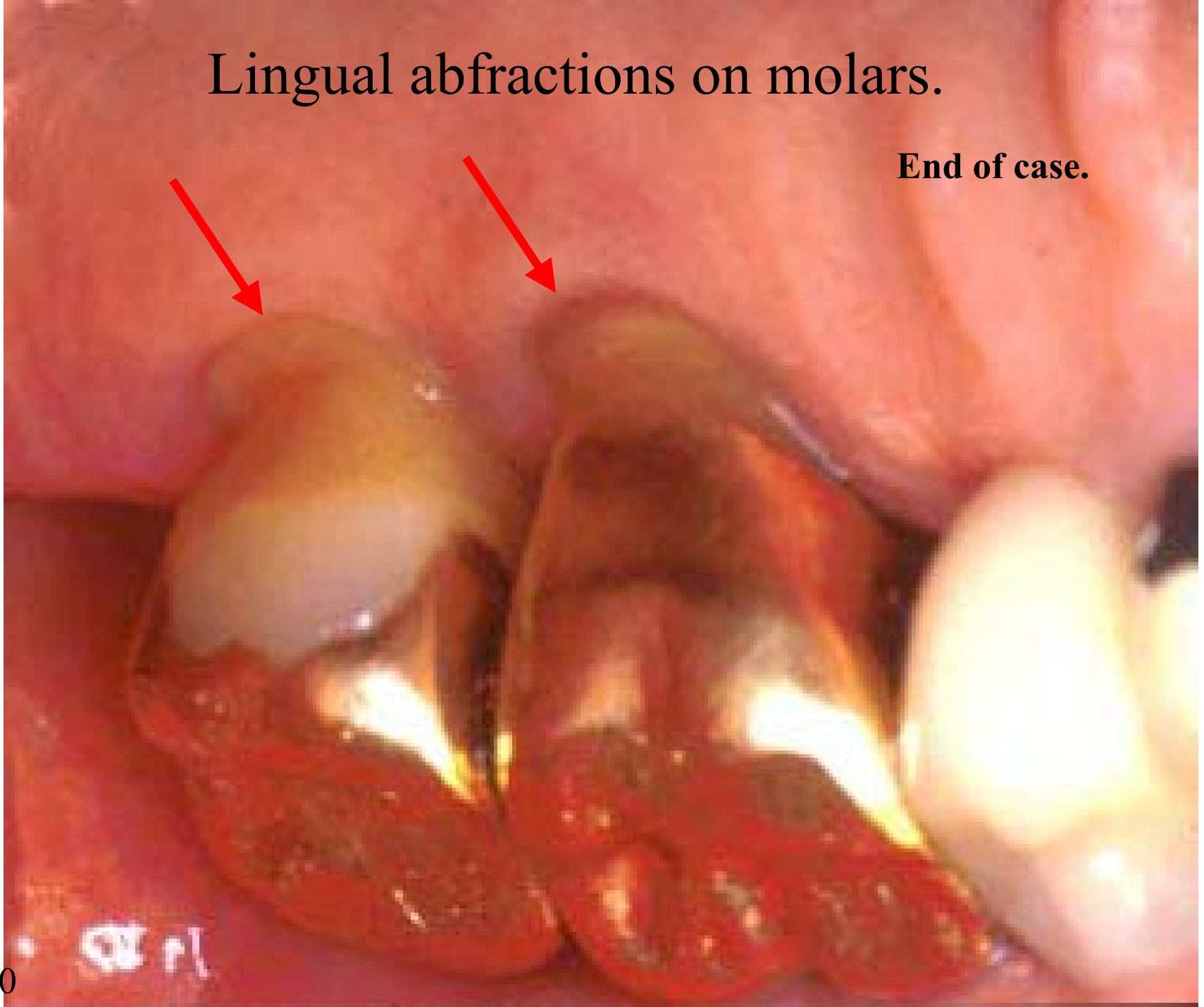
**End of case.**

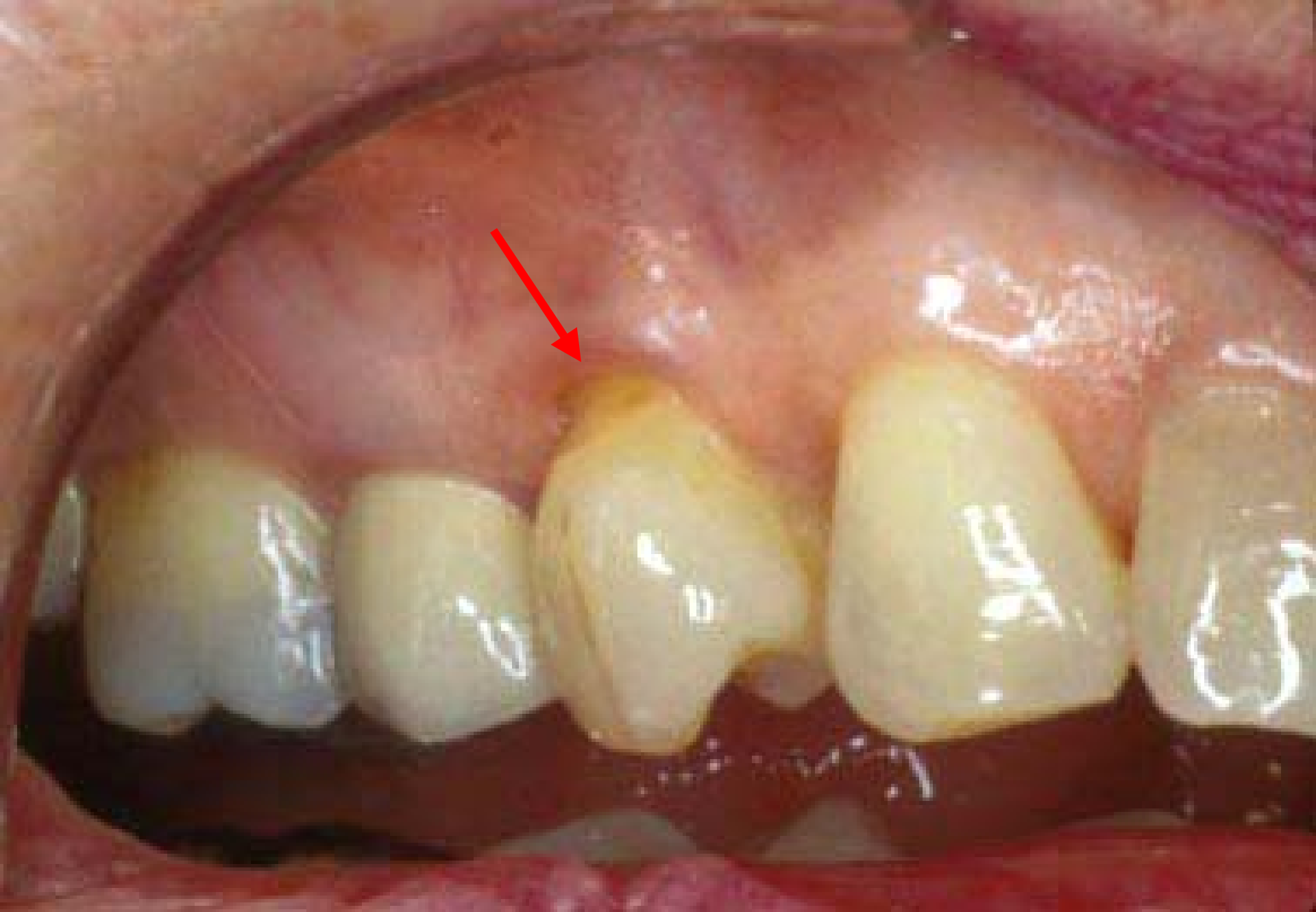

B109      Lingual abfractions on molars. See next slide.

Lingual abfractions on molars.

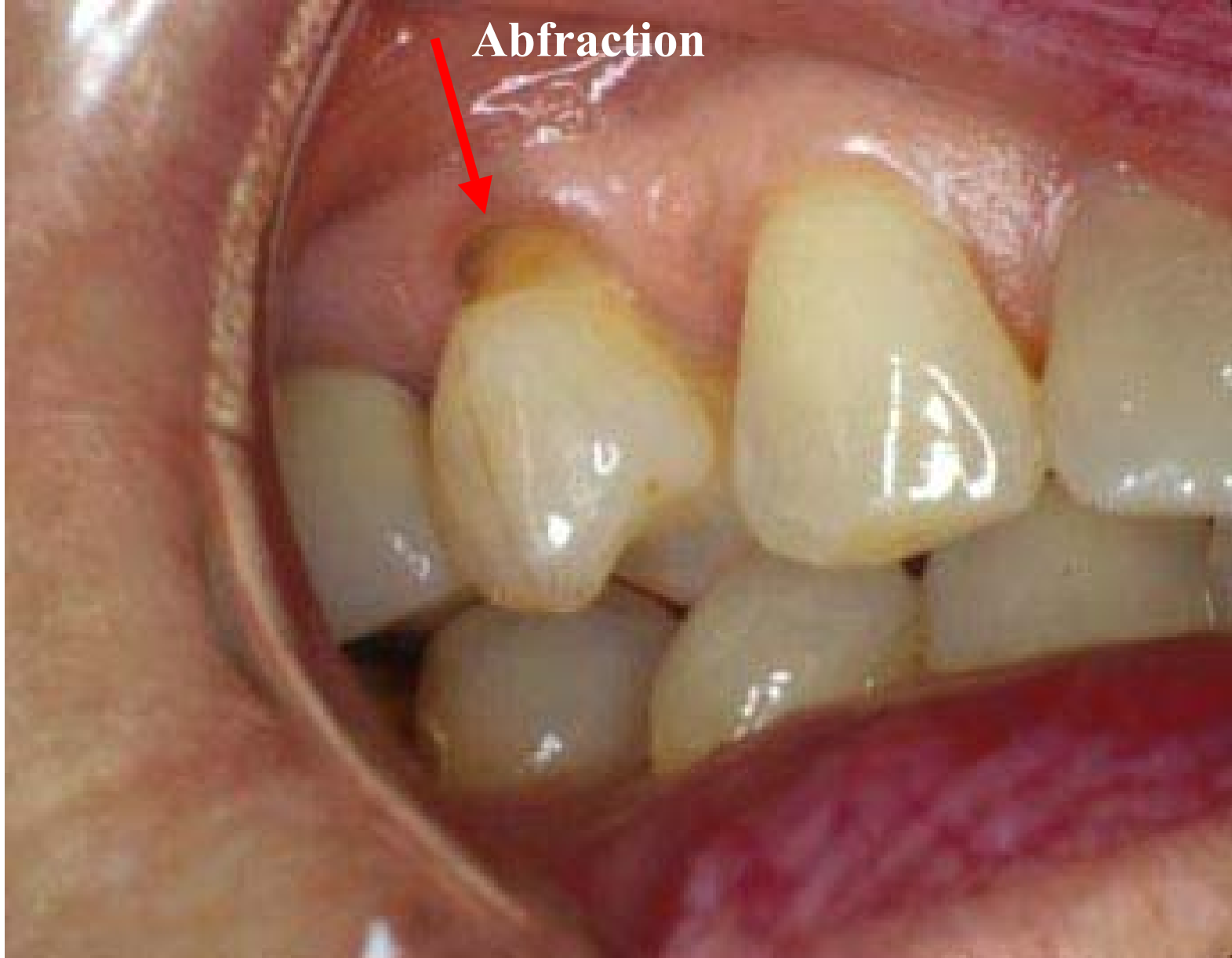**End of case.**



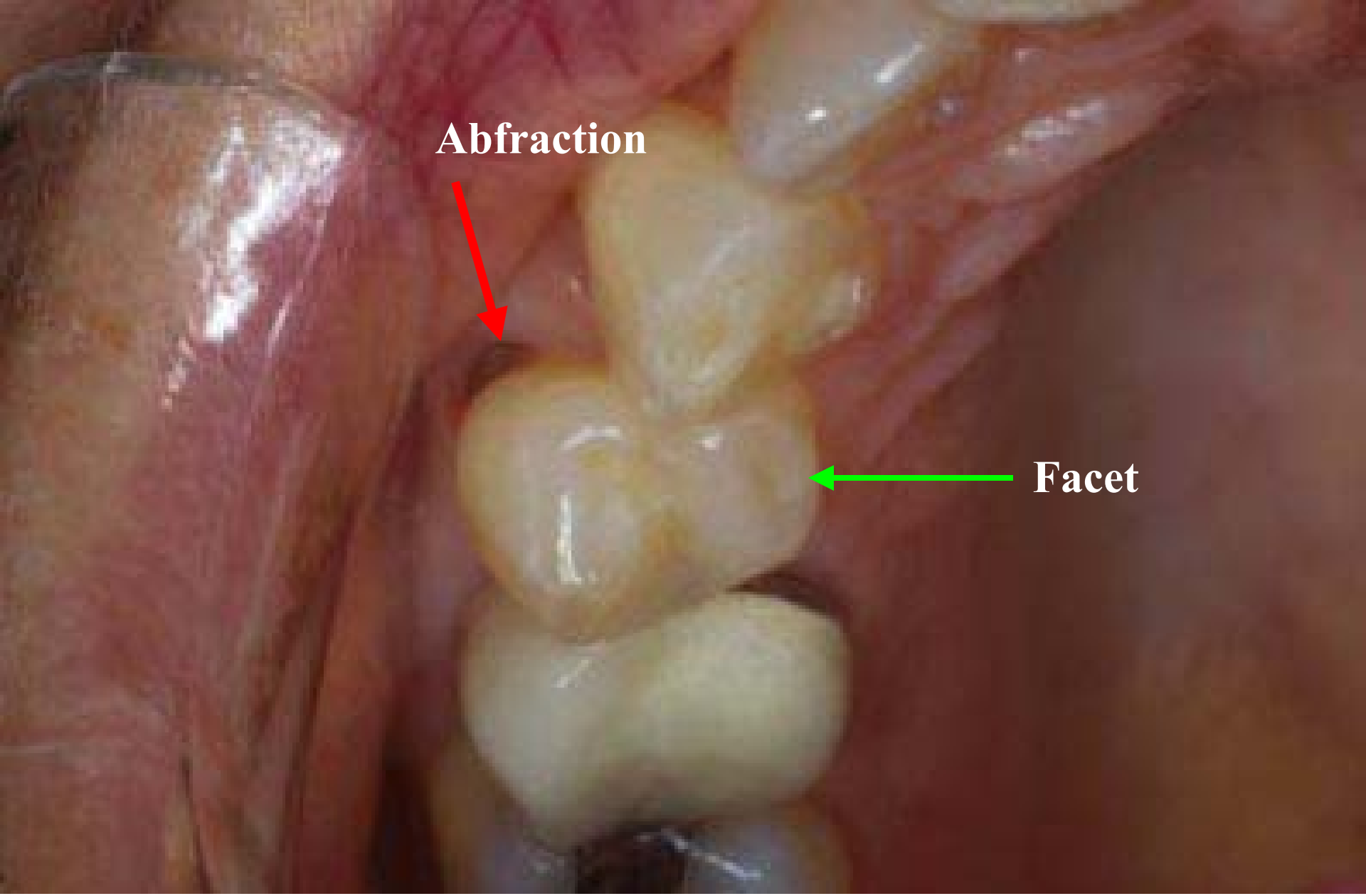


B111

Isolated abfraction on #5. See next 2 slides.



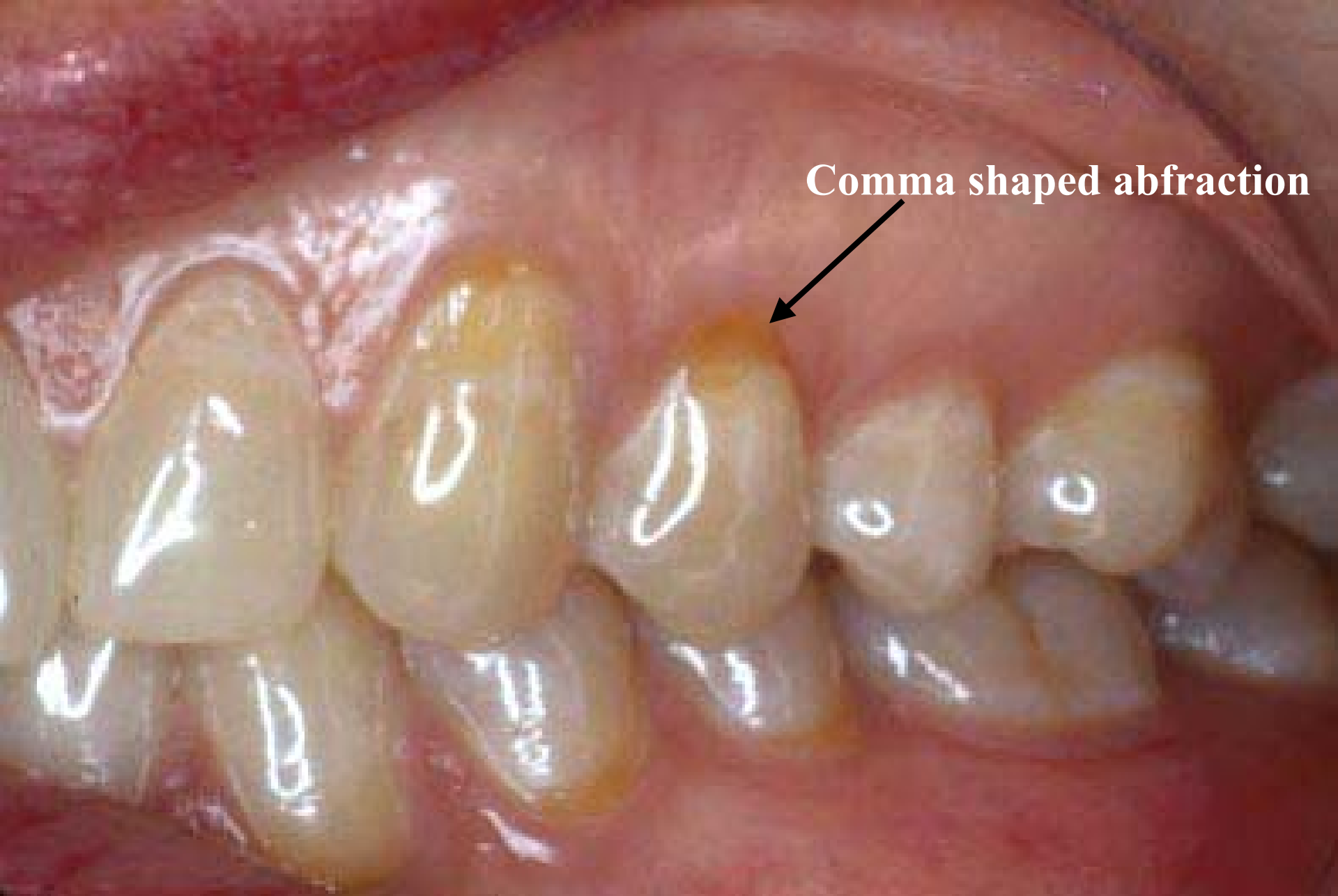
#5 in near cross-bite. See next slide.



**Abfraction**

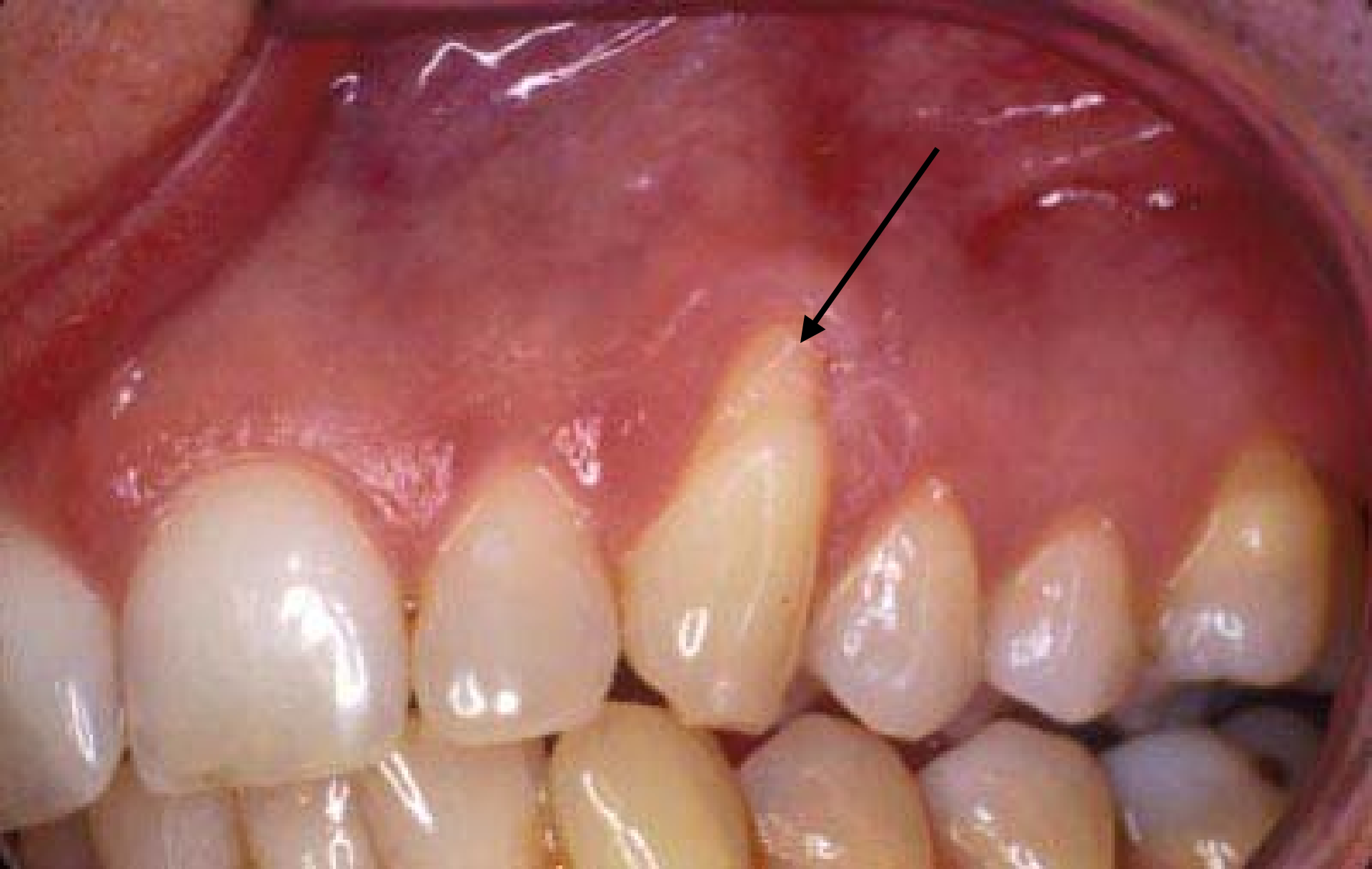**Facet**

**Flat facet on lingual cusp #5. End of case.**

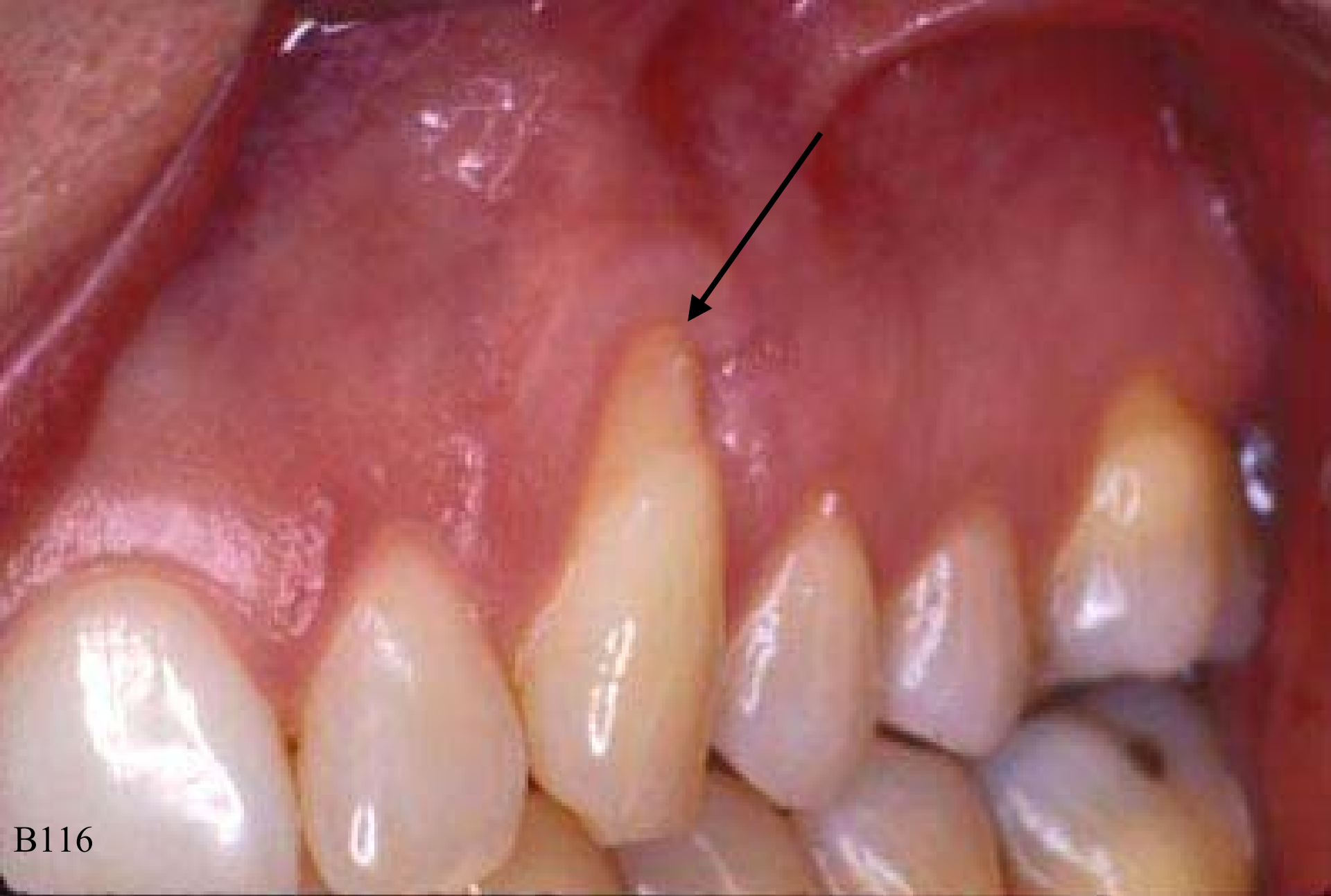

**Comma shaped abfraction**

B114 Isolated comma shaped abfraction.

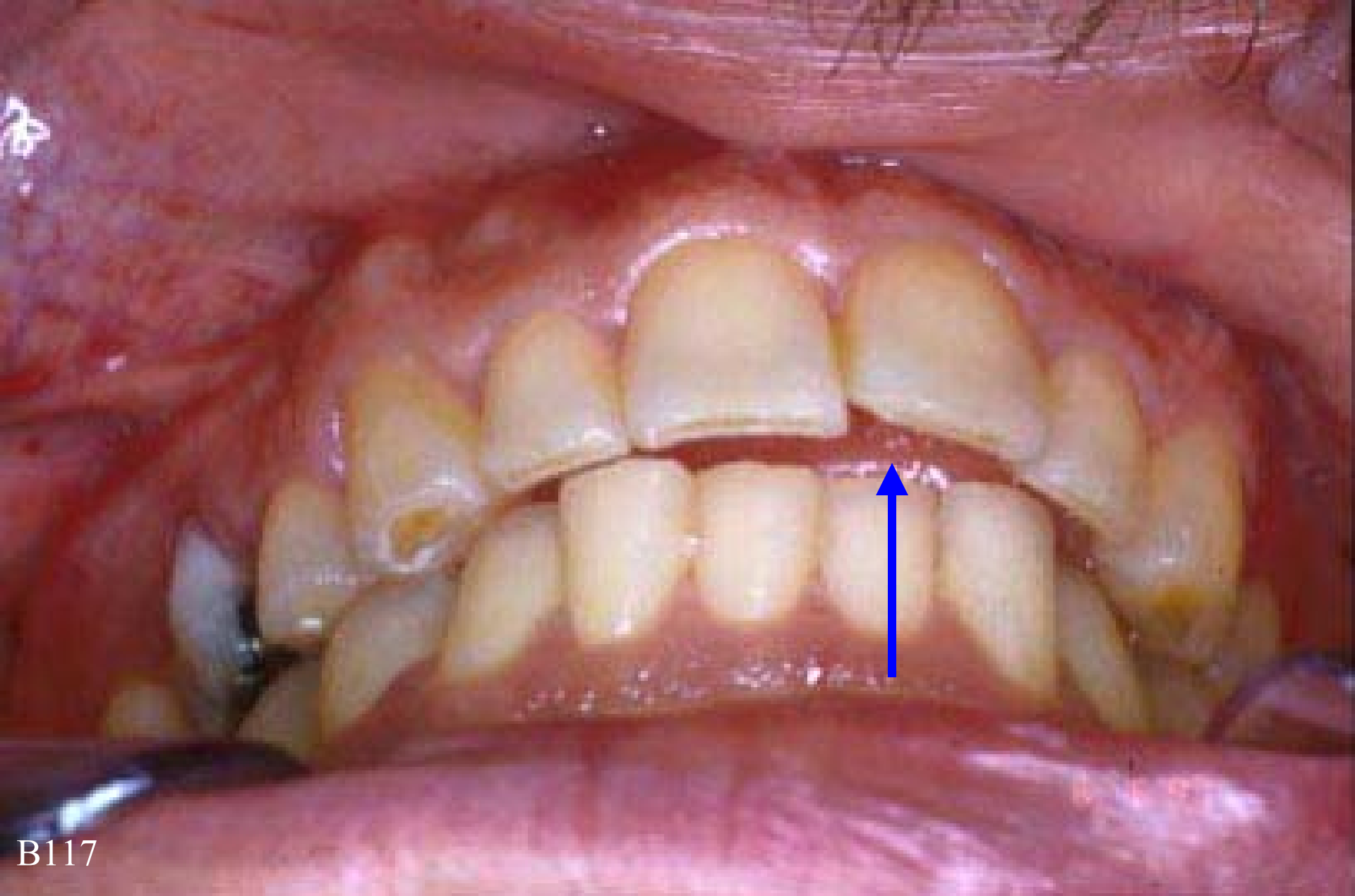


Mal-alignment angulation of cuspid was reason for this abfraction. See next slide.



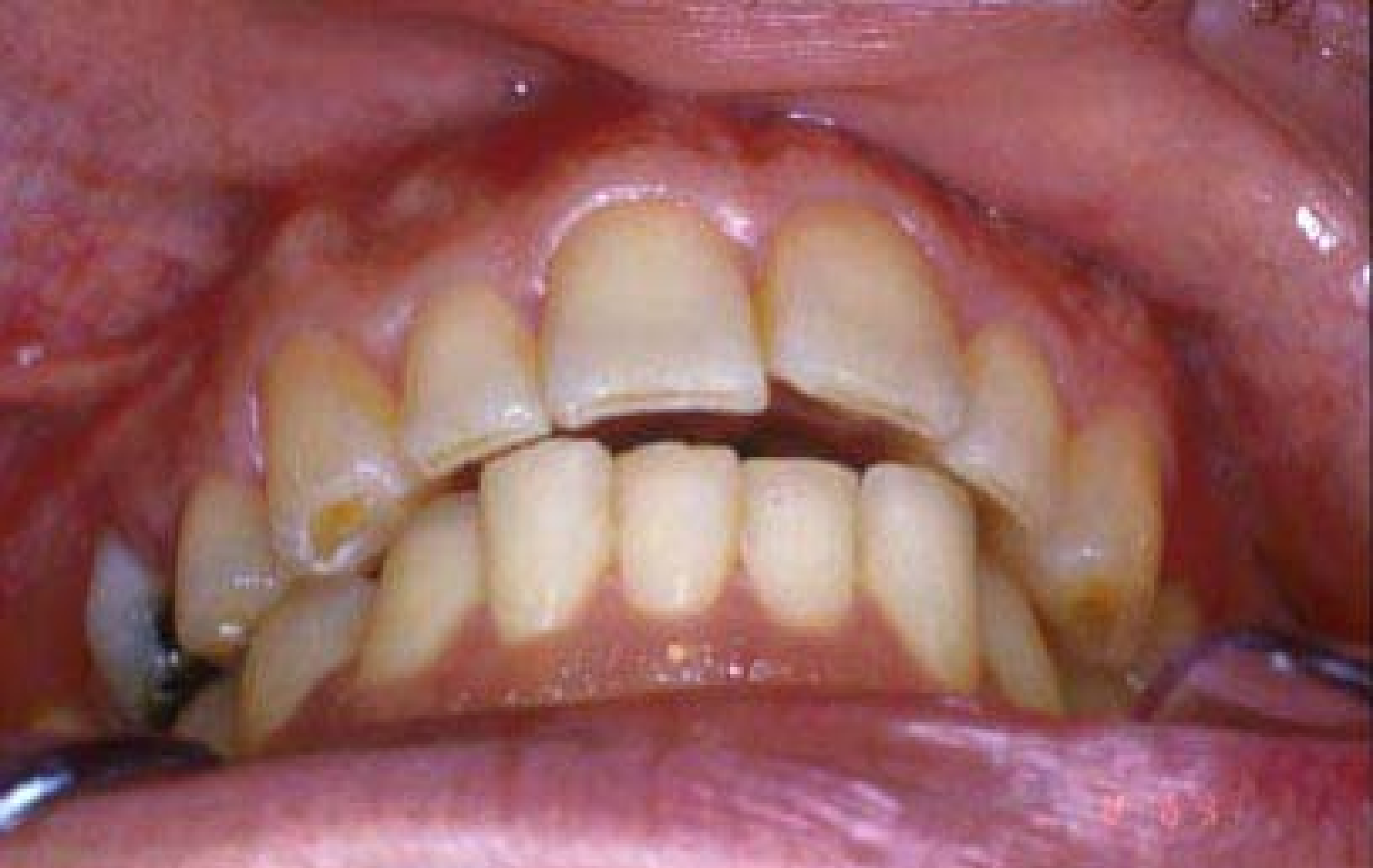B116

Closer view of lesion. Used splint to treat. End of case.

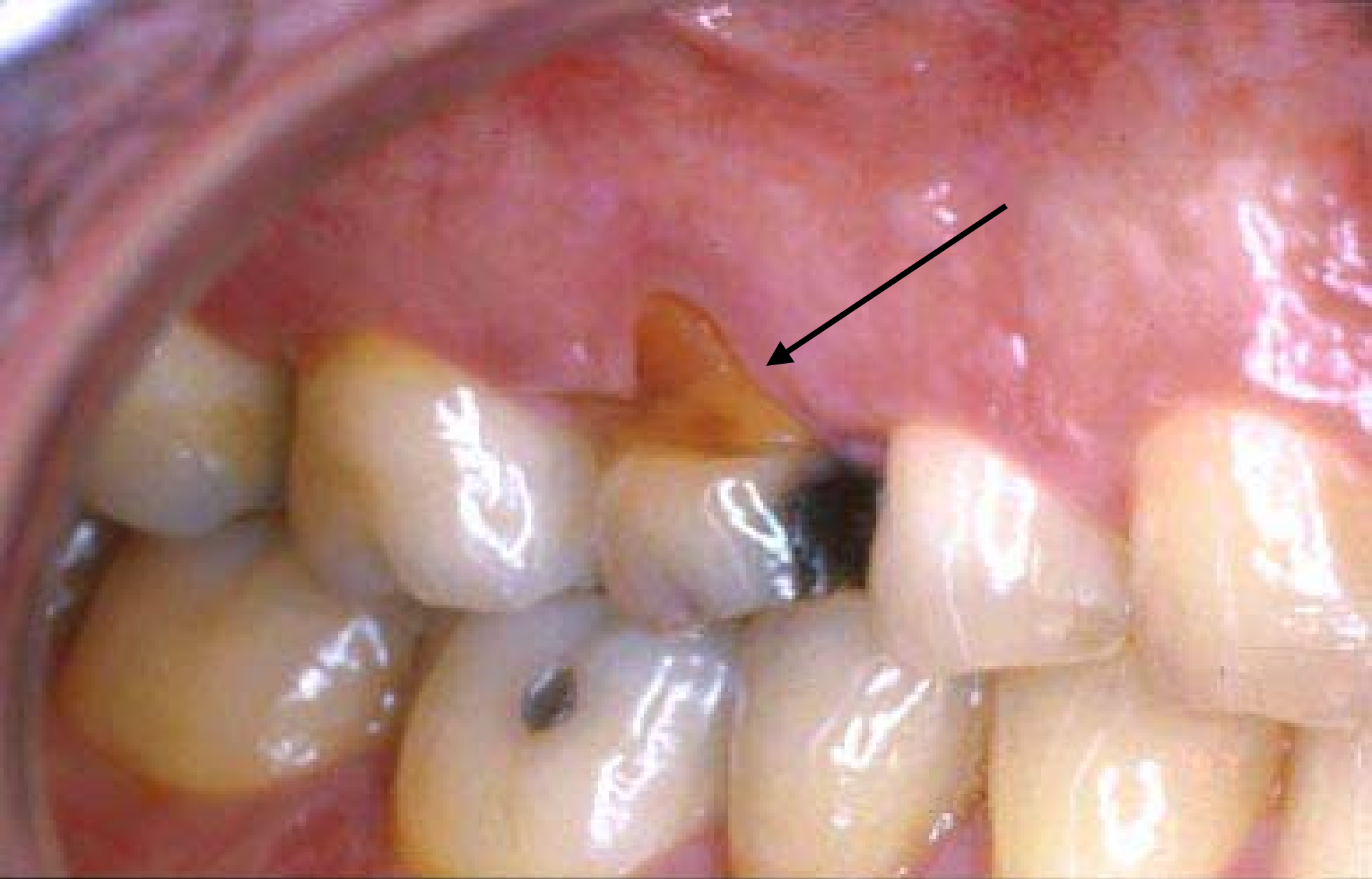


B117

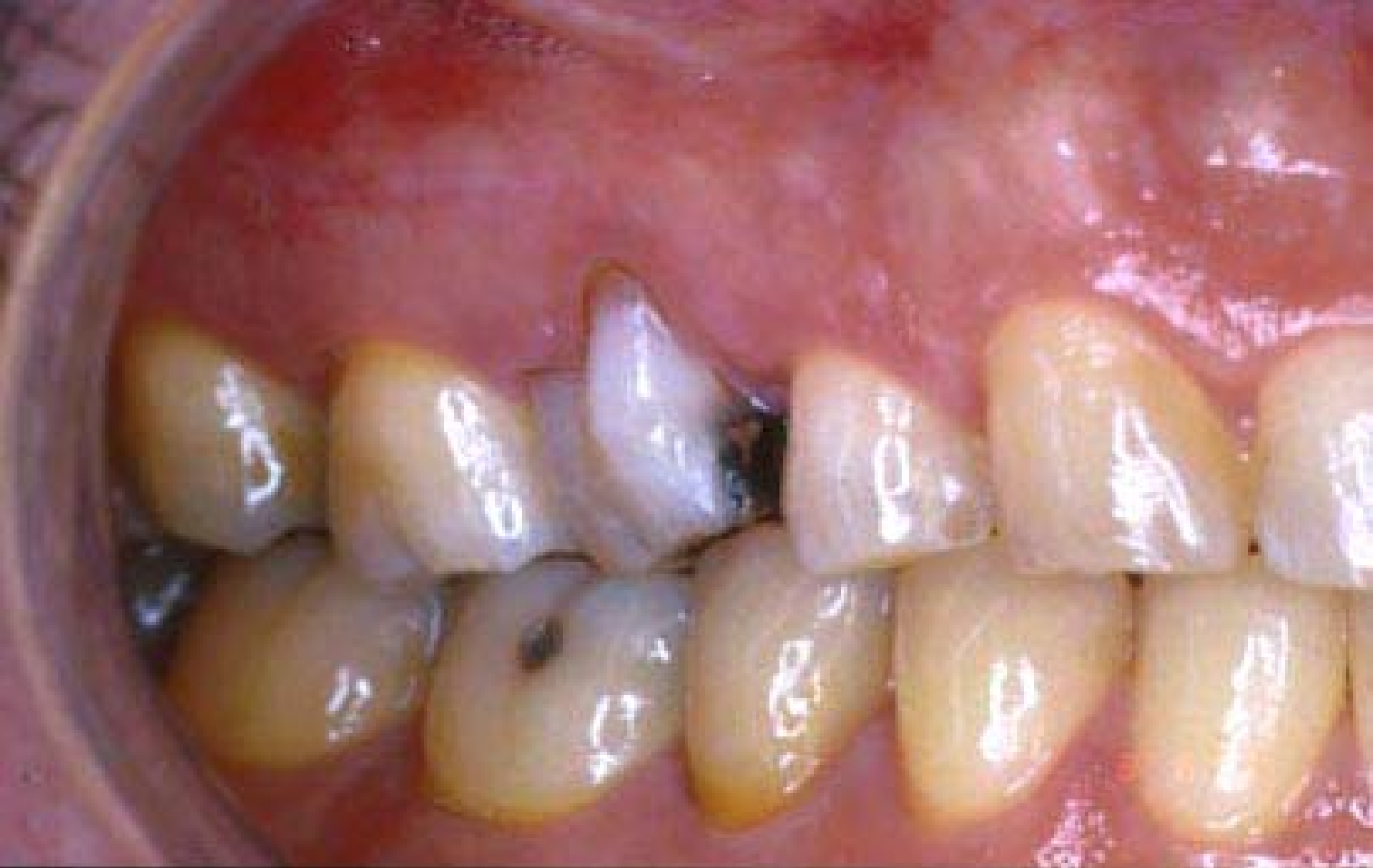Adult, age 46, with a tongue thrust. See next 3 slides.



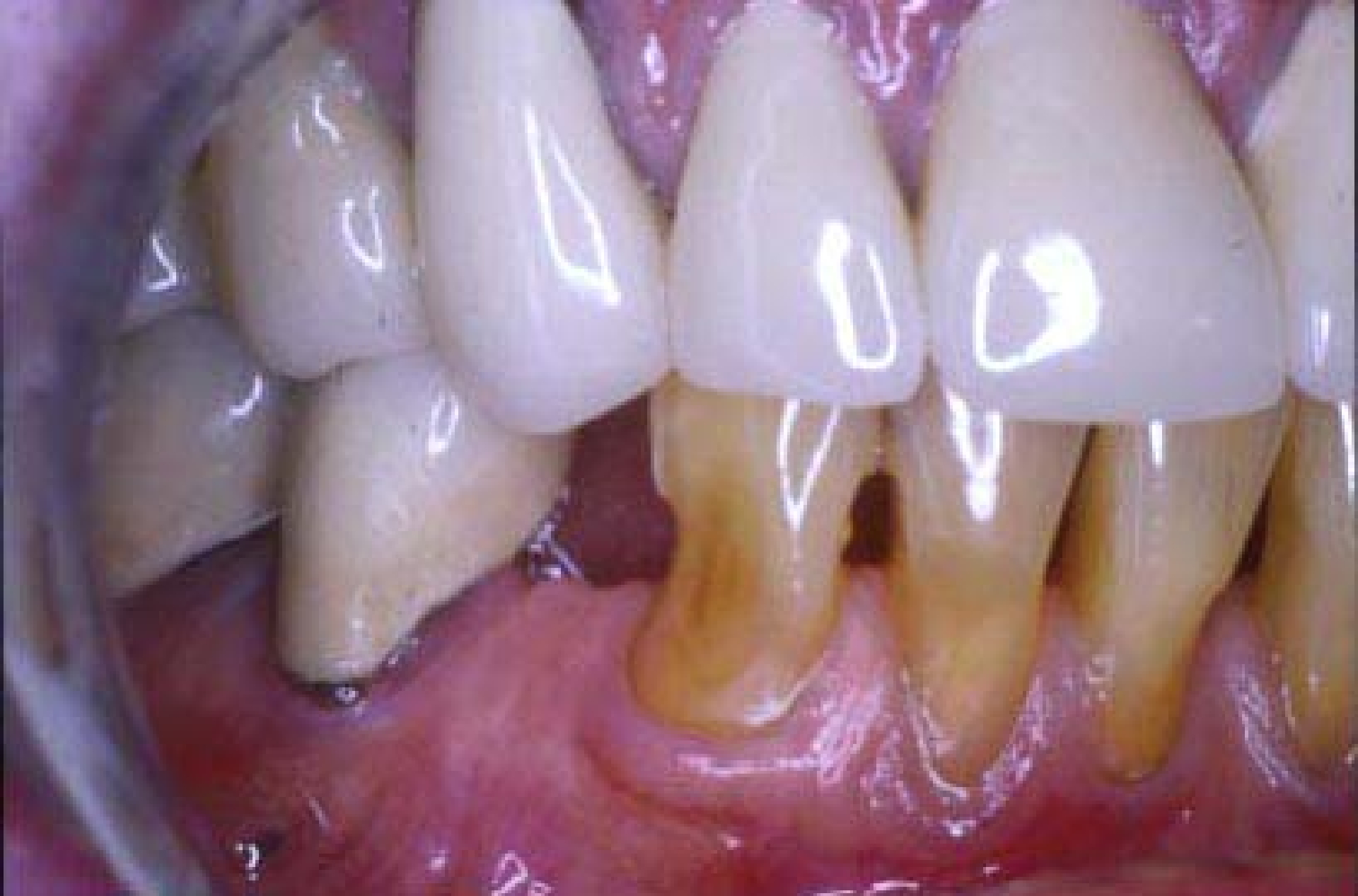He has an anterior open bite as a result of his tongue thrust. See next 2 slides.



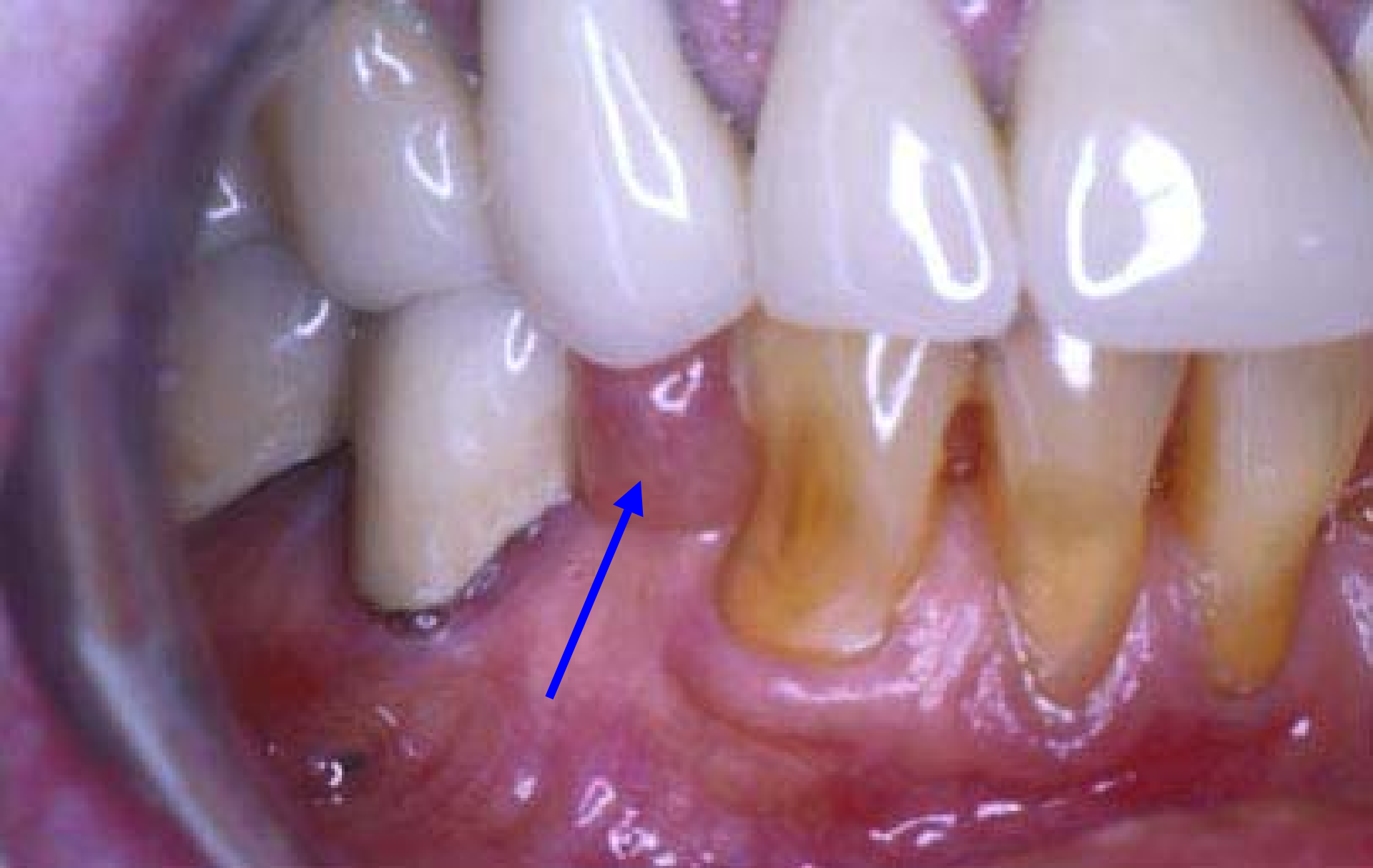Deciduous (baby) tooth with an abfraction  
in a 46-year-old adult. See next slide.



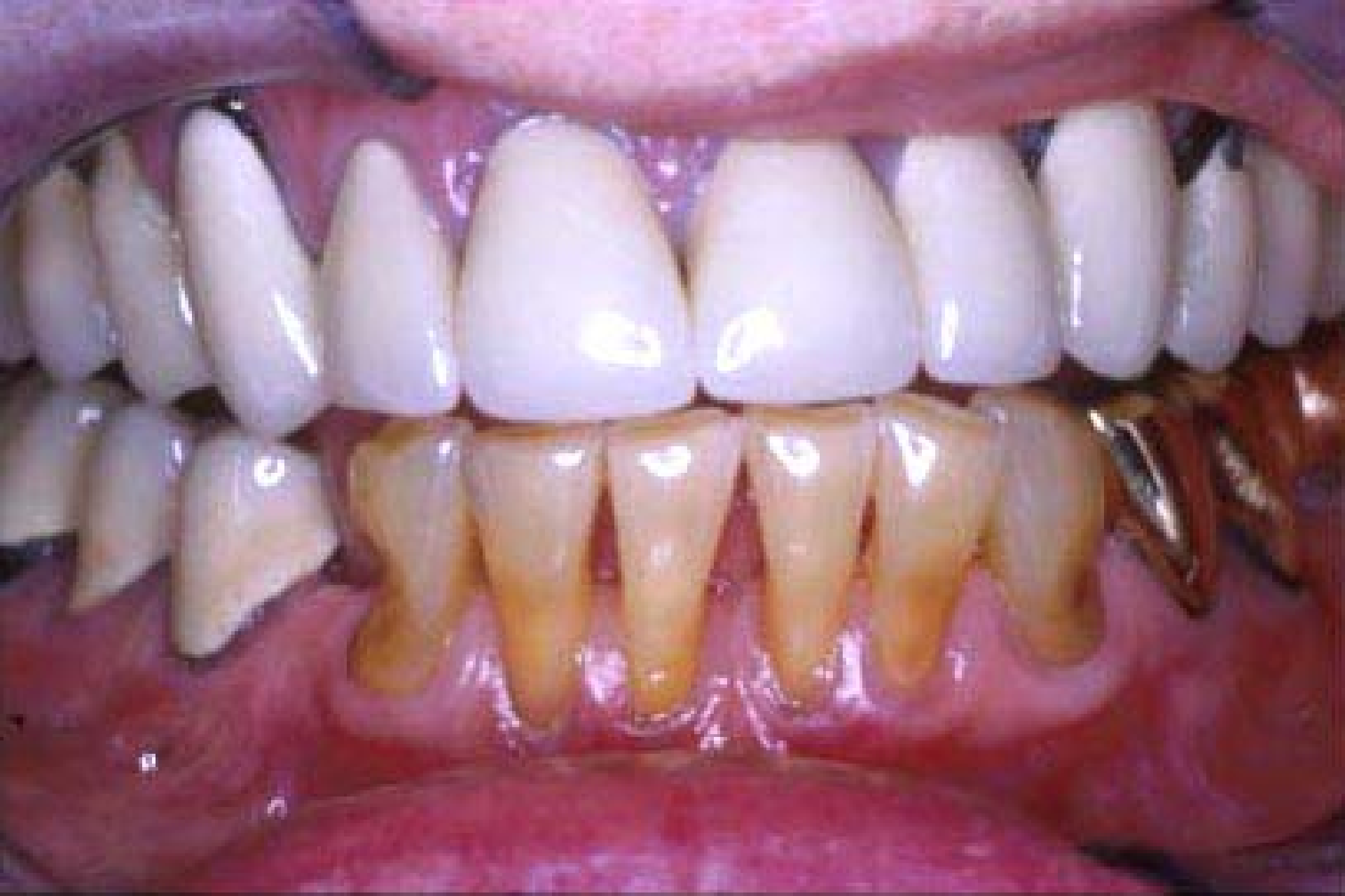Deciduous (baby) tooth restored. End of case.



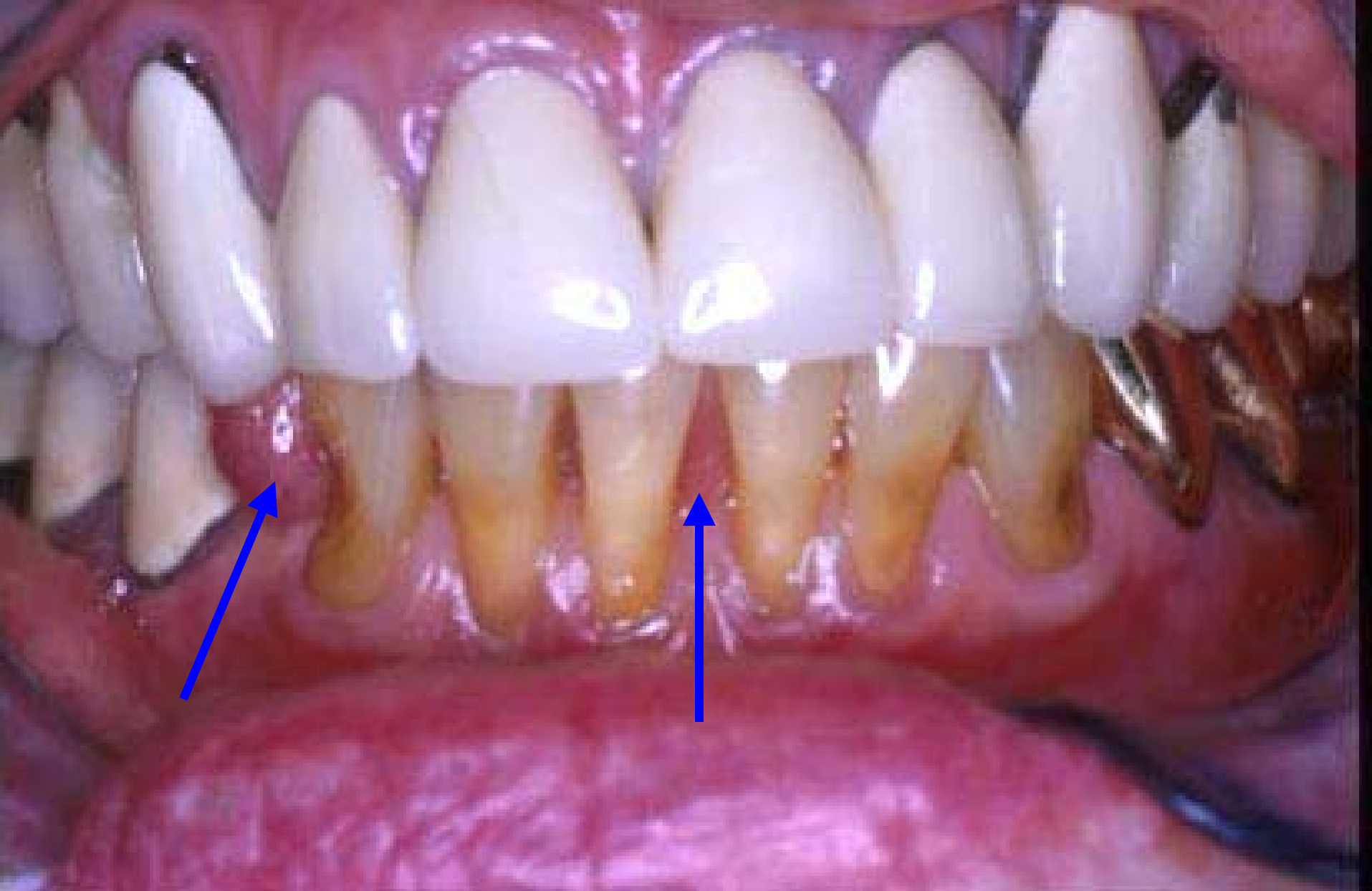B121 Abfractions and 'open spaces'. See next 3 slides.



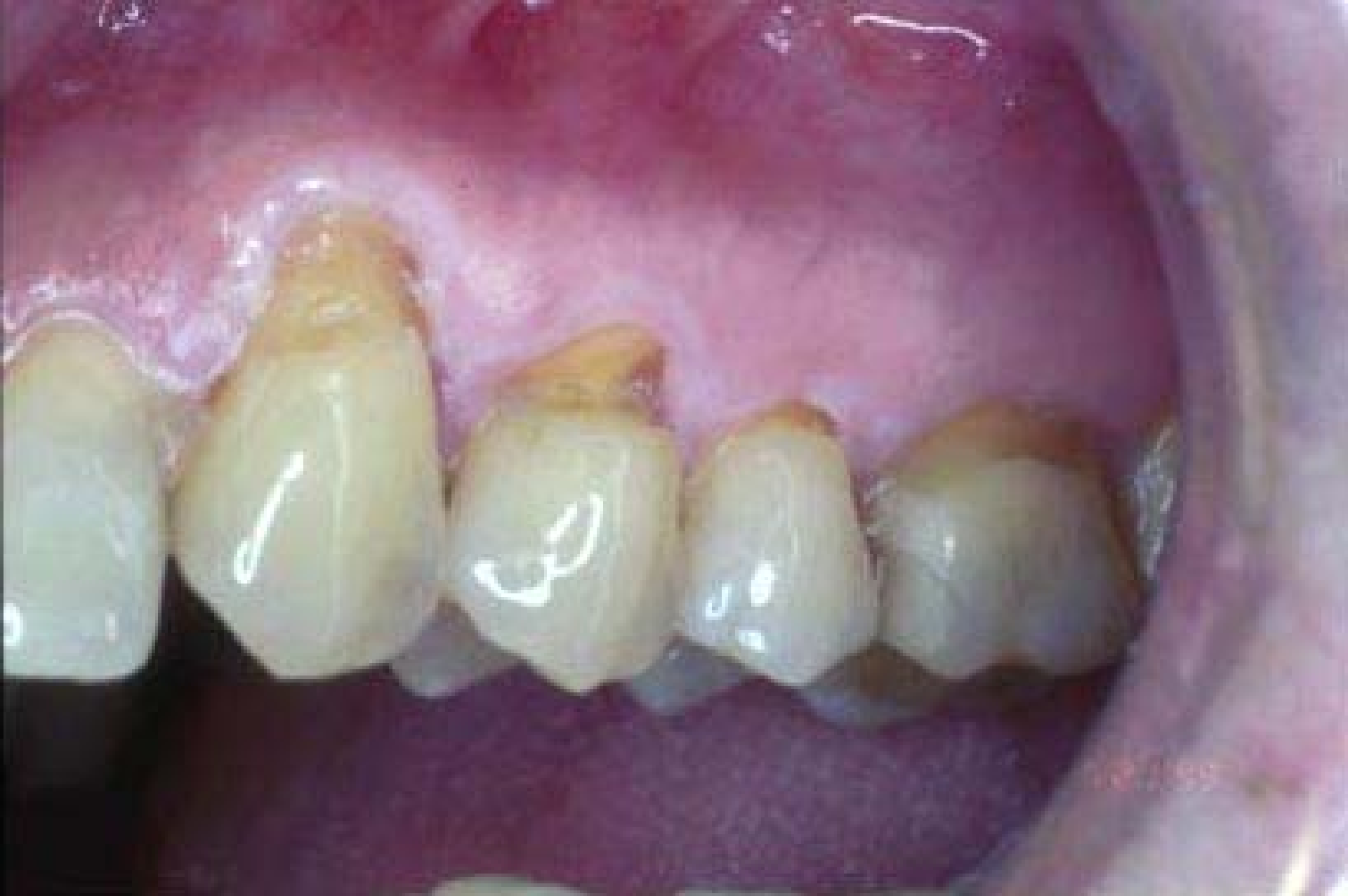Abfractions and 'open spaces' are a result of her tongue thrust. See next 2 slides.



B123 Abfractions and 'open spaces'. See next slide.

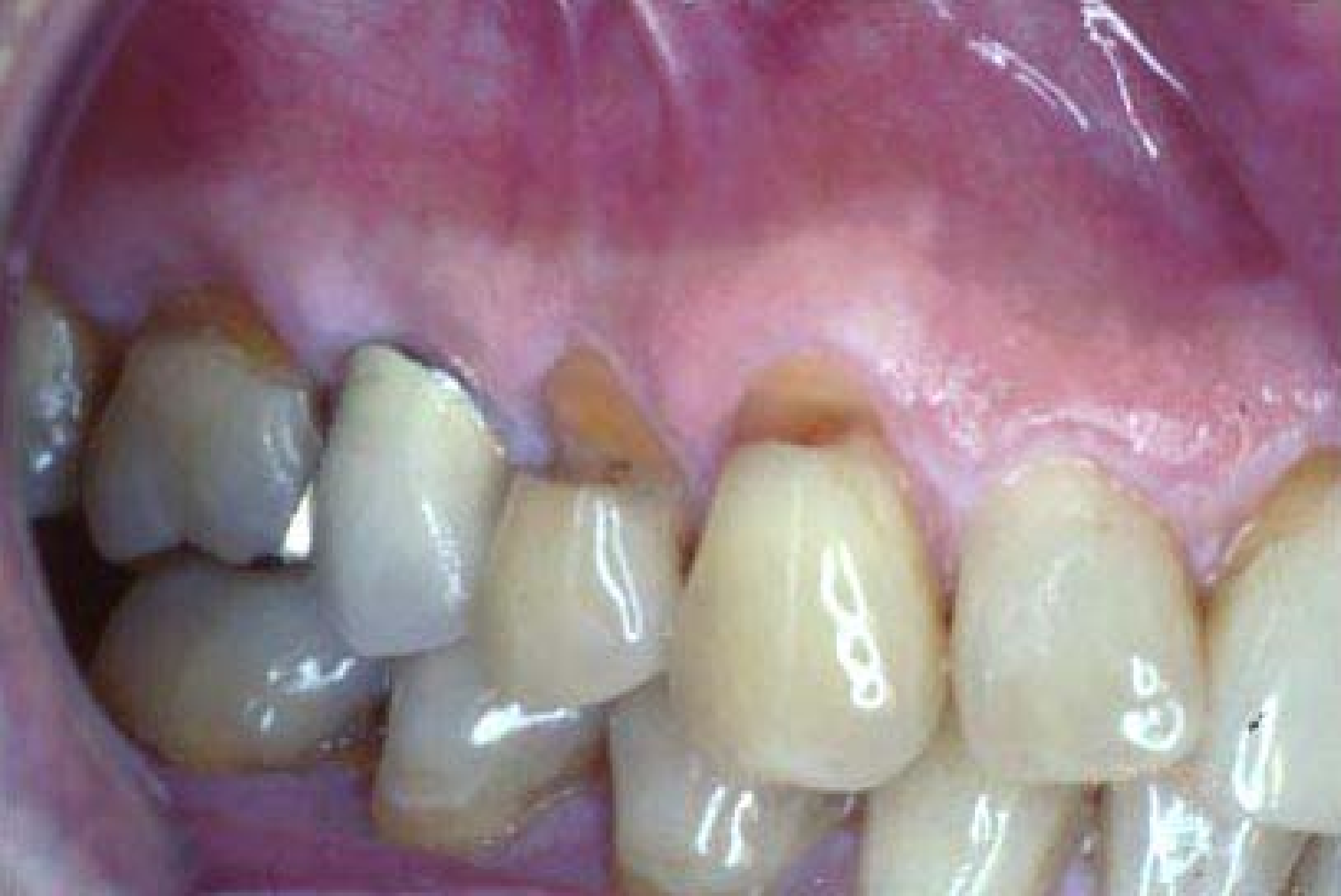

Abfractions and 'open spaces' are a result of her tongue thrust. End of case.



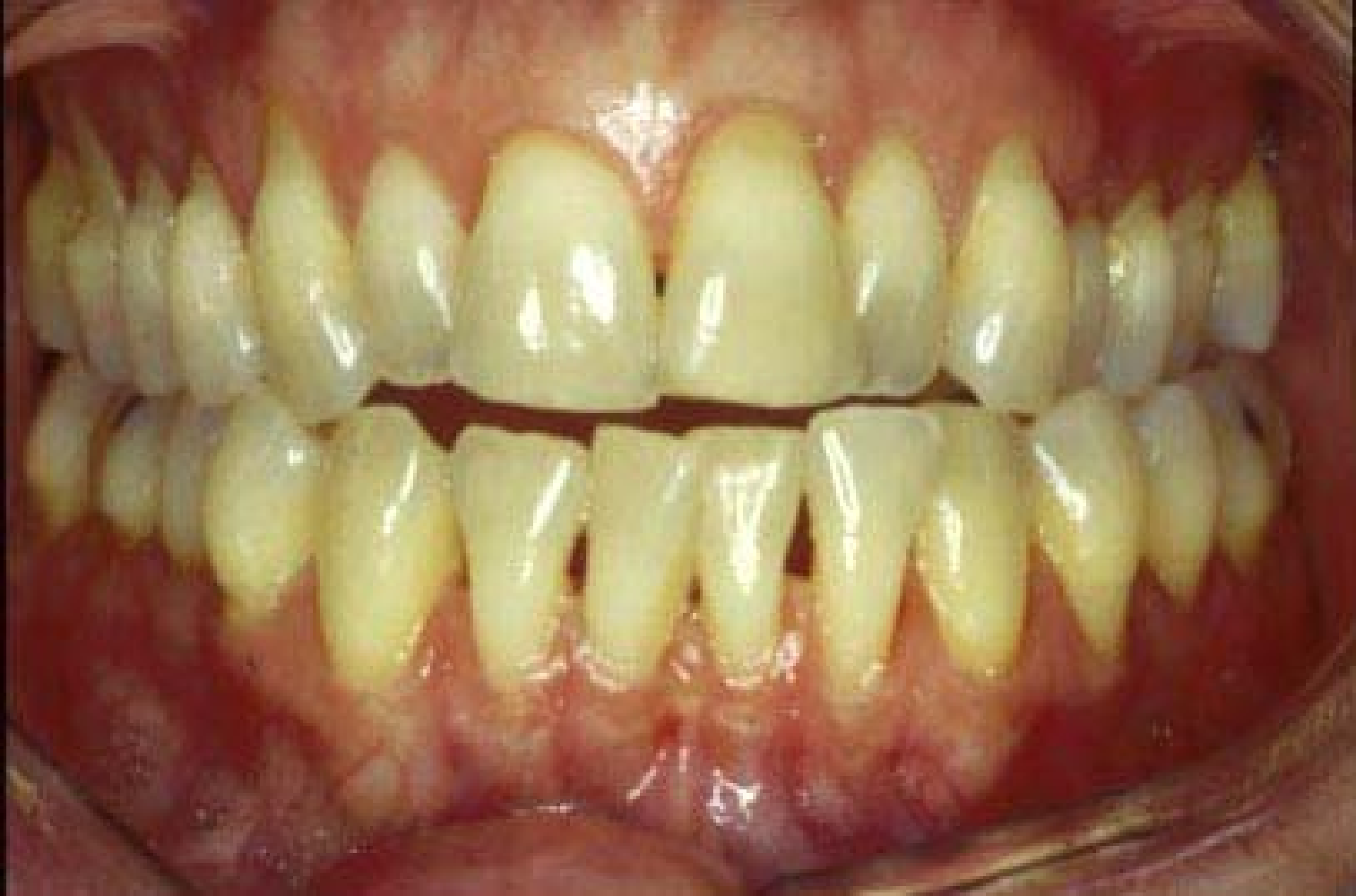B125

Abfractions - maxillary left. See next slide.

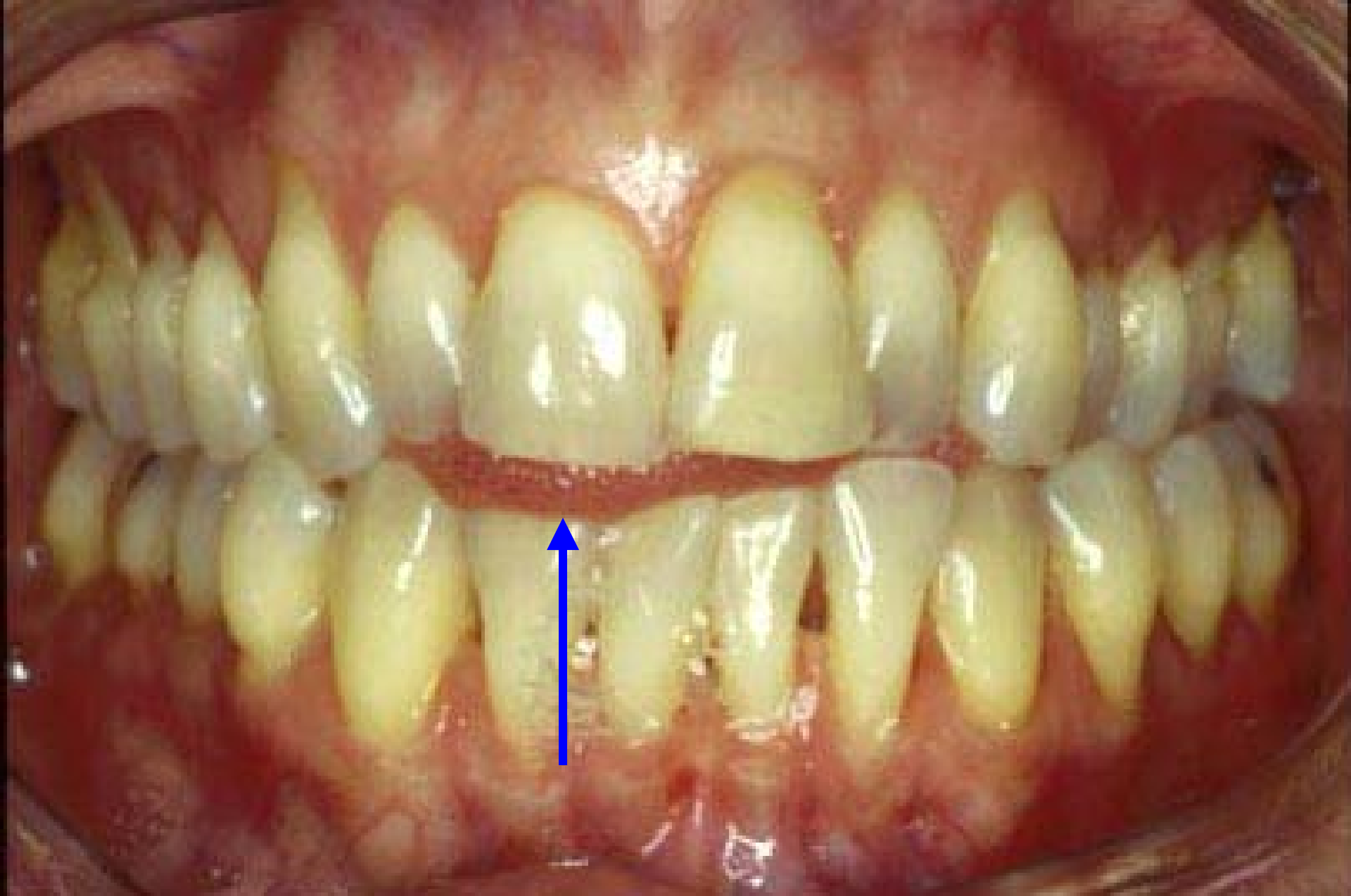

B126

Abfractions - maxillary right. End of case.

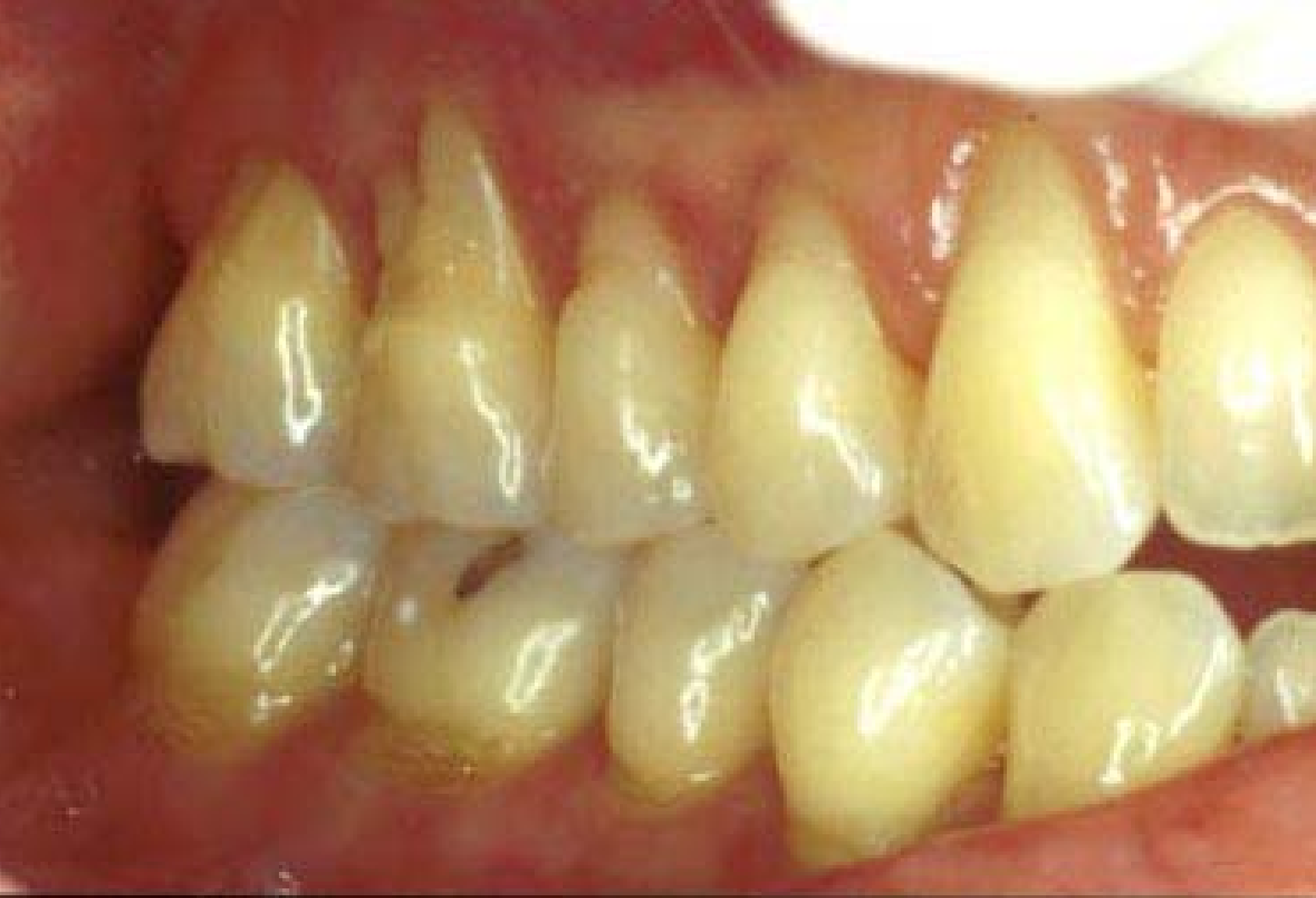

Open bite - Tight bite - Cross-bite. See next 3 slides.



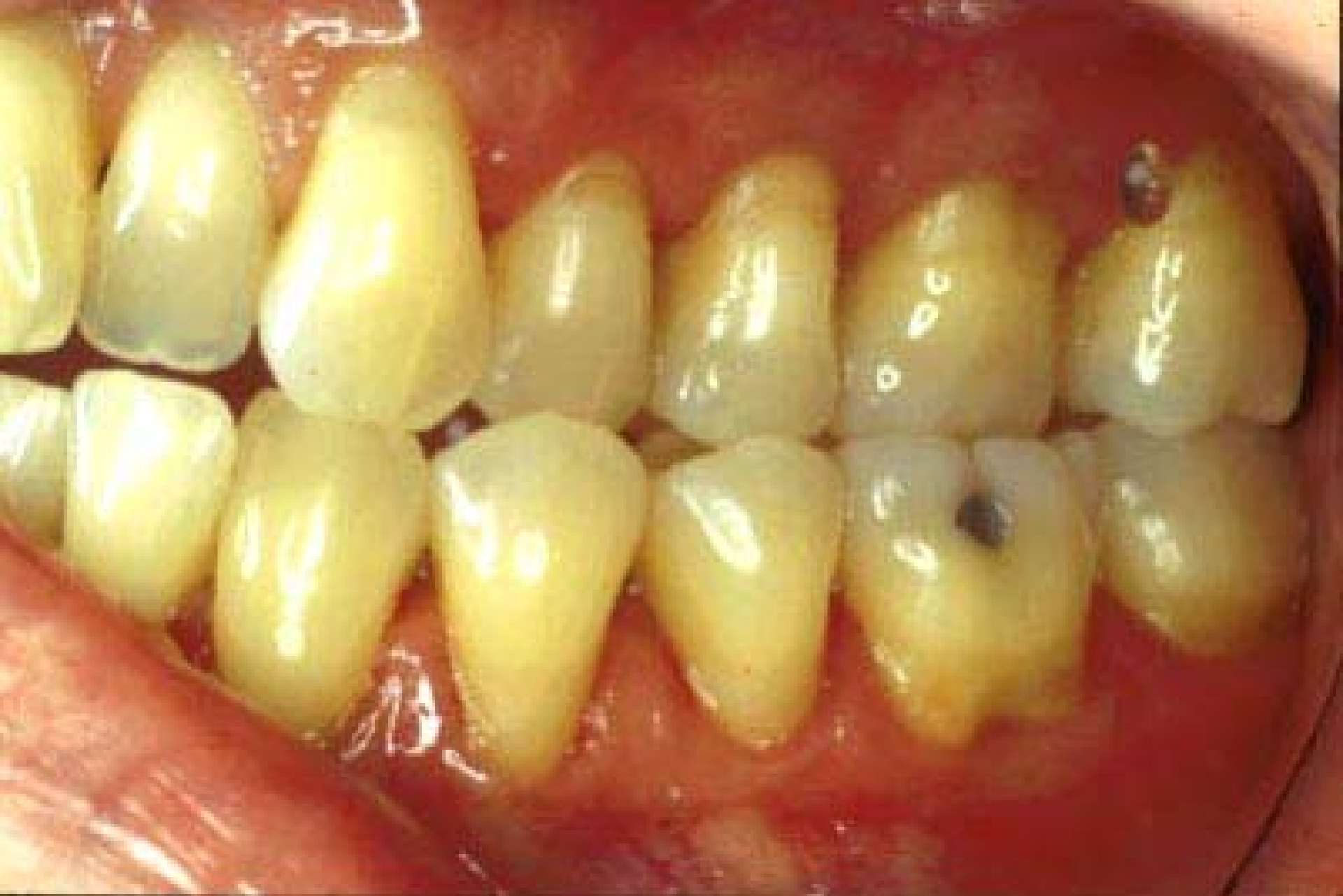B128

Anterior tongue thruster. See next 2 slides.

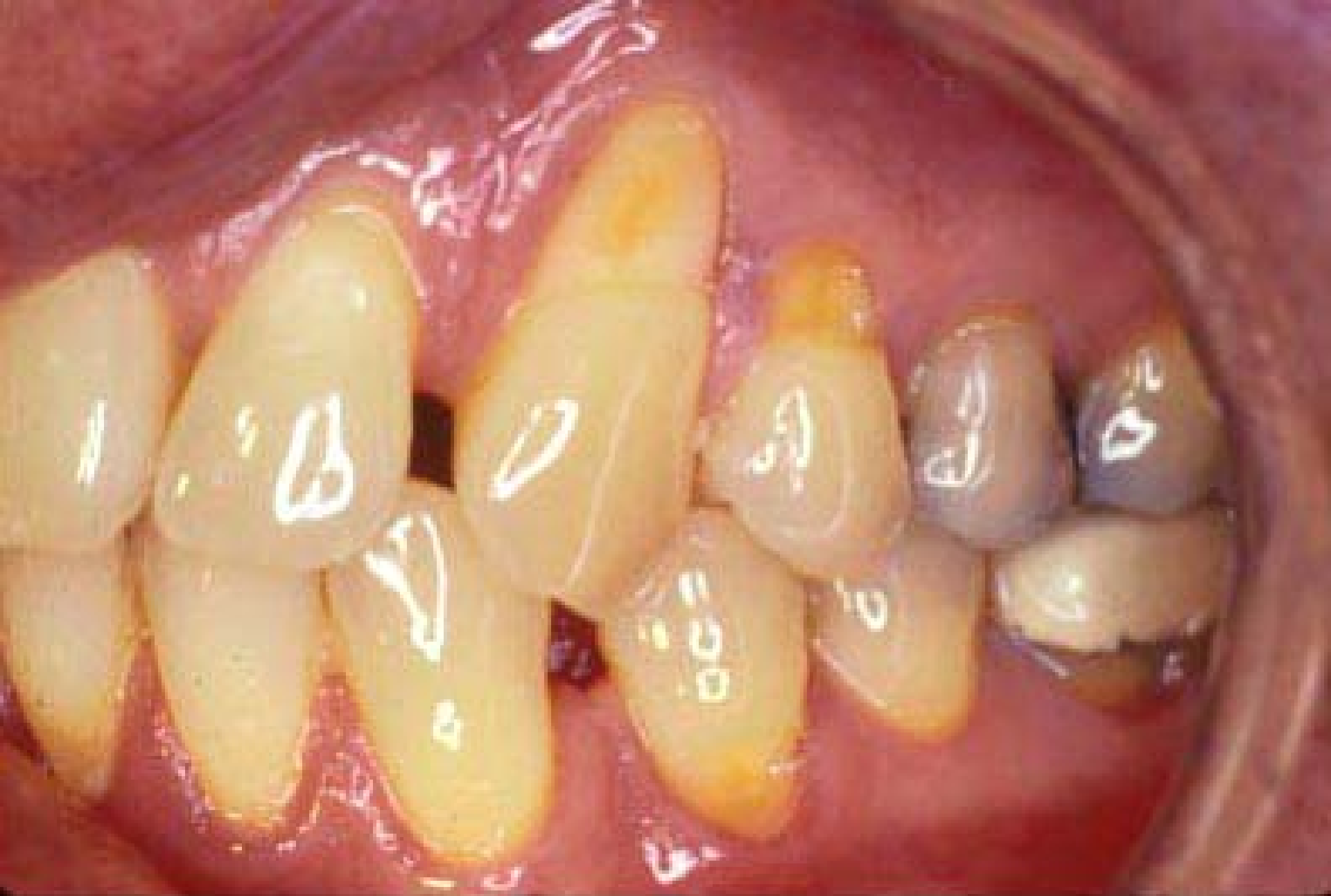

B129

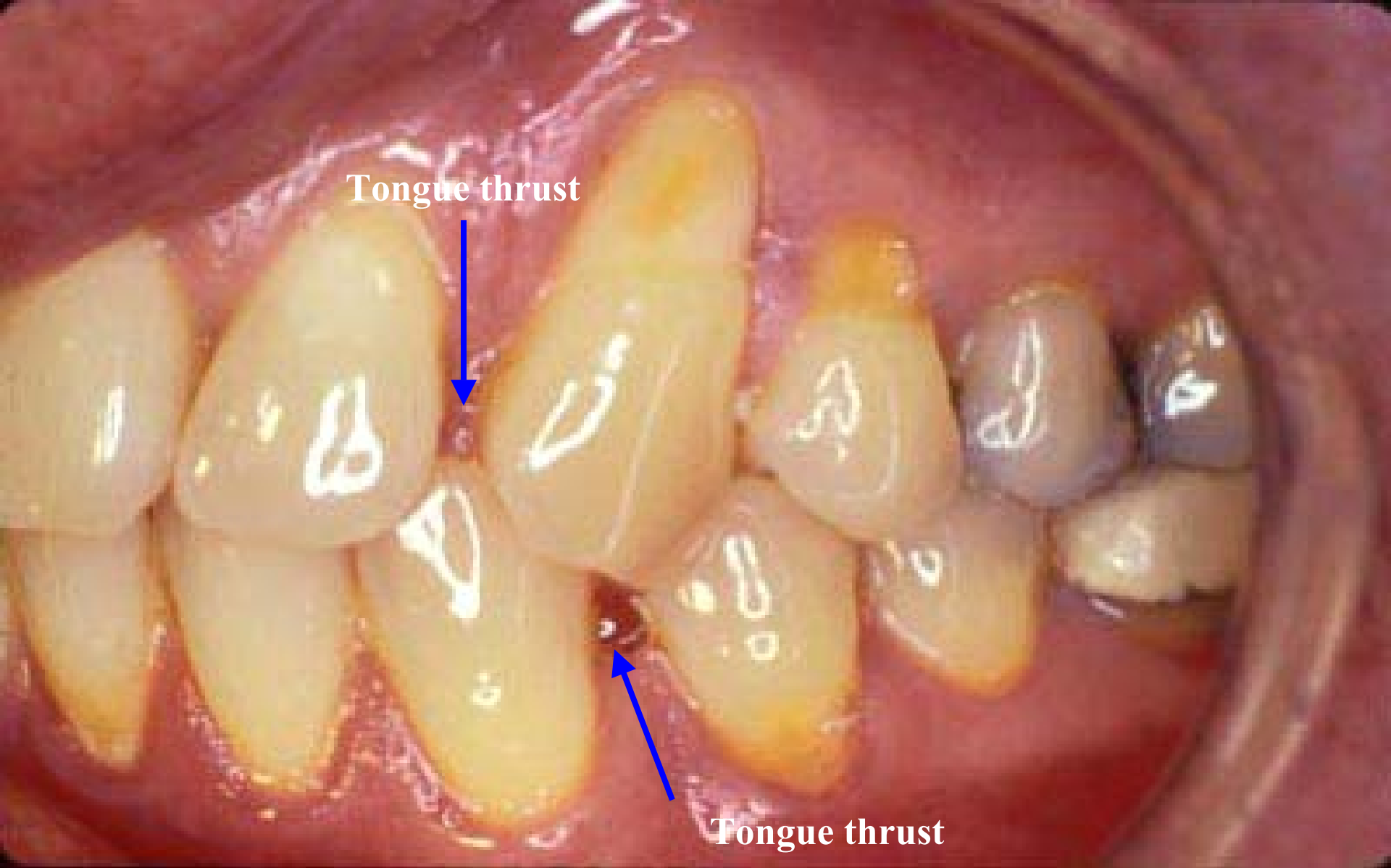
Abfractions - right side. See next slide.



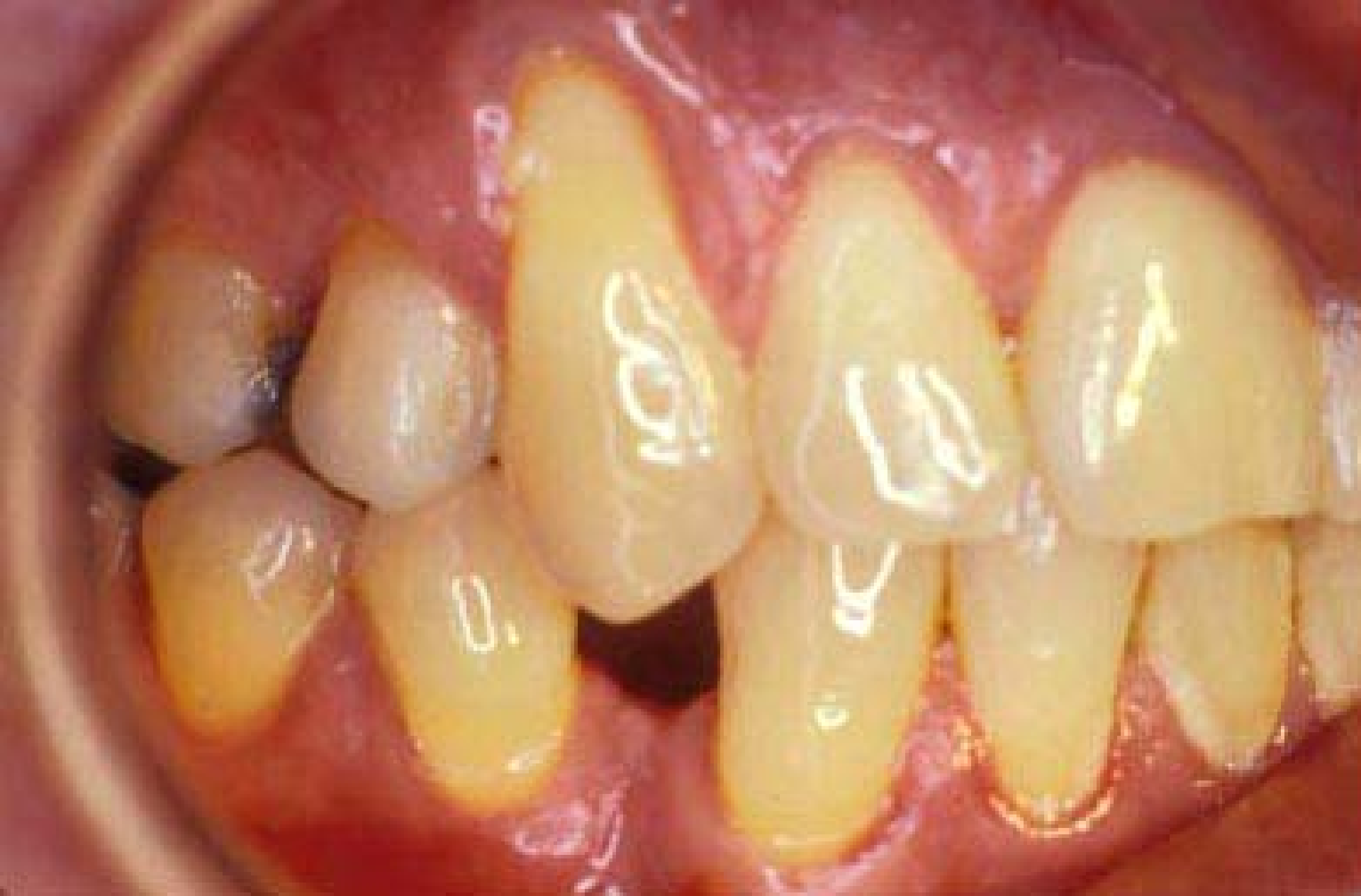B130 Abfractions - left side cross-bite. End of case.



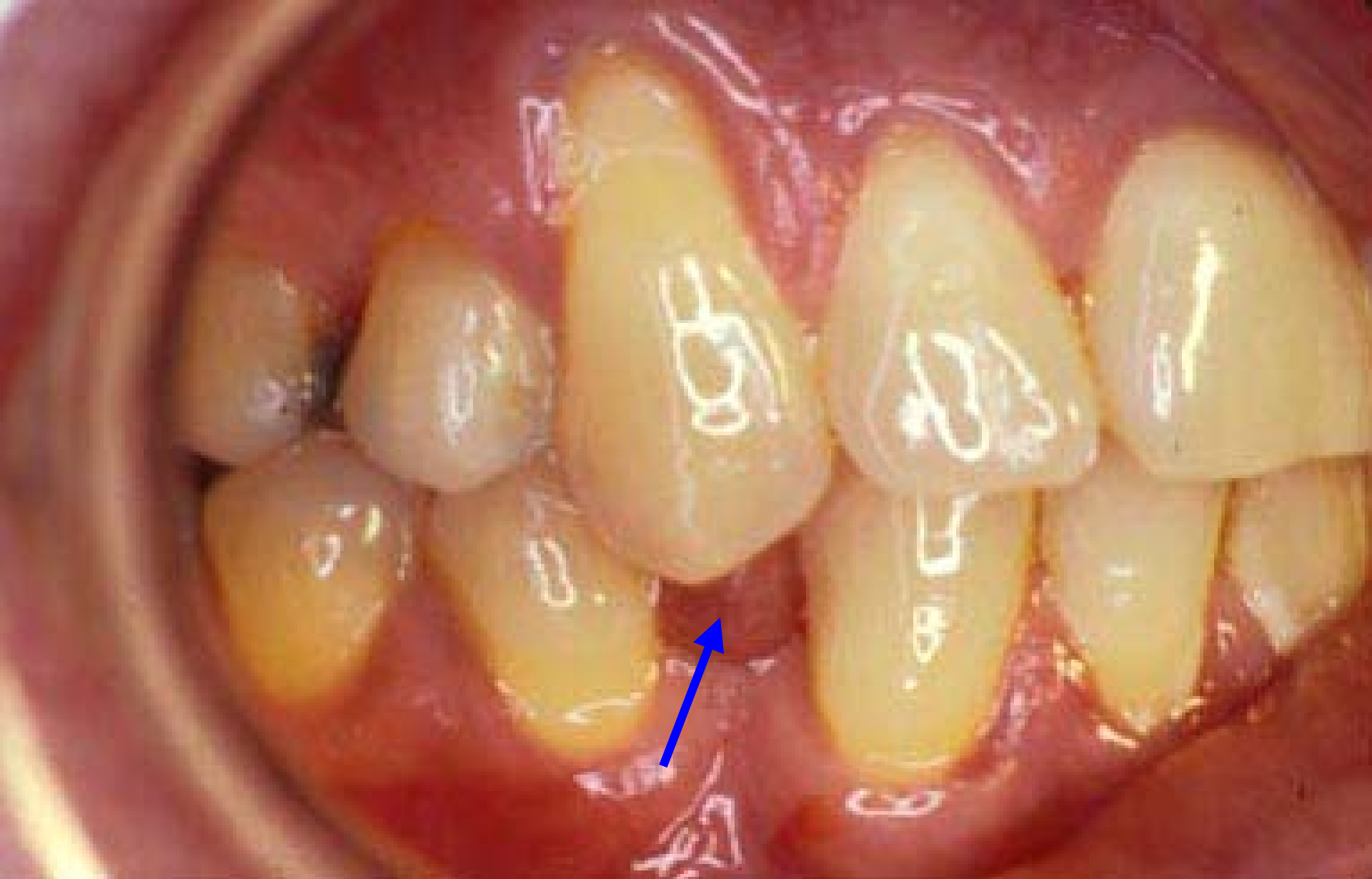B131 Abfractions and 'open spaces'. See next 3 slides.



Tongue thrust contributed to abfractions and 'open spaces'. See next 2 slides.



B133 Abfractions and 'open spaces'. See next slide.



Tongue thrust contributed to abfractions  
and 'open spaces'. End of case.

Research and presentation developed by:

Brian Palmer, DDS  
Kansas City, Missouri  
November 2004